

# Comparison of the Outcomes of Vascularized and Nonvascularized Bone Grafting in Treatment of Scaphoid Nonunion

Ali Tabrizi, Hooman Bakhtaki, Sina Dindarian<sup>1</sup>, Maryam Najafi<sup>2</sup>

Department of Orthopedics, Imam Khomeini Hospital, Urmia University of Medical Sciences, Urmia, Iran, <sup>1</sup>Student Research Committee, Urmia University of Medical Sciences, Urmia, Iran, <sup>2</sup>Trauma Research Center, Kashan University of Medical Sciences, Kashan, Iran

**ORCID:**

Ali Tabrizi: 0000-0002-4385-6445  
Hooman Bakhtaki: 0000-0001-7900-1441  
Sina Dindarian: 0000-0001-9702-1665  
Maryam Najafi: 0000-0002-0262-8323

## Abstract

**Background and Objectives:** Scaphoid fractures are common fractures of the upper extremity and more than 5% of them progress to nonunion. Nonvascularized bone grafting (NVBG) and vascularized bone grafting (VBG) are used to treat this fracture and the best option for the treatment of scaphoid nonunion (SN) is controversial. Hence, this study aimed to compare the clinical outcomes of VBG and NVBG in treatment of SN. **Materials and Methods:** This quasi-experimental study was conducted on 30 patients with SN. The patients were divided into two groups of NVBG ( $n = 15$ ) and VBG ( $n = 13$ ) and were followed up at 2, 4, 8 weeks, and at least 10 months after surgery. Patients' functional abilities in both groups were compared using the Quick Disabilities of the Arm, Shoulder, and Hand (DASH) Questionnaire and the Mayo modified wrist score. Severity of pain was also compared using the Visual Analog Scale (VAS) before and after the surgery. **Results:** Union rates between the VBG (92.3%) and NVBG (73.3%) groups were not significantly different ( $P = 0.1$ ). There was a significant difference in the VAS score ( $P = 0.03$ ) and grip strength ( $P = 0.010$ ) between the two groups. However, no significant difference was found regarding the active range of motion between the groups ( $P = 0.2$ ). The postoperative Quick DASH scores of the VBG and of NVBG groups were  $5.6 \pm 1.1$  and  $8.4 \pm 2.3$ , respectively, and the difference was significant ( $P = 0.001$ ). The functional improvement based on the postoperative Mayo score was significantly higher in the VBG group compared with the NVBG group ( $85.9 \pm 3.04$  vs.  $80.4 \pm 6.6$ ;  $P = 0.006$ ). **Conclusion:** Vascularized bone grafting seems to be a preferable treatment option for SN because of its higher union rate and better functional outcomes.

**Keywords:** Bone graft, functional outcome, nonunion, nonvascularized, Scaphoid, vascularized

## INTRODUCTION

Accounting for more than 60% of all carpal fractures, scaphoid fractures are the second most common fractures of the upper extremity after distal radius fractures.<sup>[1]</sup> The highest occurrence rate of scaphoid fractures are in young men in the second and third decades of life.<sup>[2]</sup> Among different populations, the annual occurrence rate of scaphoid fractures ranges from 0.08 to 1.21 per 1000 people. Studies show that more than 5% of all scaphoid fractures progress to nonunion fractures.<sup>[3]</sup> Diagnosis of scaphoid nonunion (SN) in radiography is hard and this fracture usually does not cause severe pain and work limitation. Thus, delay in diagnosis

may cause severe complications, such as instability and degenerative changes (SN advanced collapse).<sup>[4]</sup> Various nonvascularized bone grafting (NVBG) and vascularized bone grafting (VBG) procedures are used to treat this fracture including 1, 2-intercompartmental supraretinacular artery pedicled vascularized bone graft (1,2-ICSRA-VBG), free

**Address for correspondence:** Dr. Ali Tabrizi,  
Modaress Street, Ershad Boulevard, Urmia, 57157 81351, Iran.  
E-mail: [ali.tab.ms@gmail.com](mailto:ali.tab.ms@gmail.com)

This is an open access journal, and articles are distributed under the terms of the Creative Commons Attribution-NonCommercial-ShareAlike 4.0 License, which allows others to remix, tweak, and build upon the work non-commercially, as long as appropriate credit is given and the new creations are licensed under the identical terms.

**For reprints contact:** [WKHLRPMedknow\\_reprints@wolterskluwer.com](mailto:WKHLRPMedknow_reprints@wolterskluwer.com)

**How to cite this article:** Tabrizi A, Bakhtaki H, Dindarian S, Najafi M. Comparison of the outcomes of vascularized and nonvascularized bone grafting in treatment of scaphoid nonunion. Arch Trauma Res 2022;11:171-6.

**Received:** 01-01-2022,

**Revised:** 09-01-2023,

**Accepted:** 09-01-2023,

**Published:** 28-02-2023.

### Access this article online

Quick Response Code:



Website:  
[www.archtrauma.com](http://www.archtrauma.com)

DOI:  
10.4103/atr.atr\_1\_22

vascularized medial femoral condyle bone transfer,<sup>[5]</sup> and the free iliac crest bone graft.<sup>[6]</sup> It is believed that vascular-based bone graft is a better treatment option because of its faster healing process due to activity of living cells providing nutrition to the bone structure, less immobilization period, and higher chance of stability.<sup>[7]</sup> However, still the best option for the treatment of SN remains controversial. For instance, VBGs are technically more challenging than NVBGs, requiring microsurgical techniques<sup>[6,8]</sup> and resulting in prolonged surgical time, and donor-site morbidity.<sup>[9]</sup> If the fracture can be successfully repaired with NVBG, it is not necessary to use VBG techniques. However, the rate of union by NVBG methods differs from 60% to 95% in various papers, while in VBG, the rate ranges from 80% to 100%. Obviously, the use of VBG is more beneficial when NVBG may result in graft failure.<sup>[5,8,10,11]</sup> Hence, the present study aimed to prospectively evaluate the clinical outcomes of VBG compared to NVBG in treatment of nonunion scaphoid fractures.

## MATERIALS AND METHODS

### Study design

This quasi-experimental study was conducted on 30 patients with SN from April 2015 to April 2018. Demographic factors, features of the fractures (the site and time of fracture), type of surgery, and functional status of the patients were extracted from the medical records of the Orthopedic Department of the Trauma Center in Imam Khomeini Hospital of Urmia (in the northwest province of Iran). Urmia is located at a distance of 900 km from the capital of Iran with a population of about 1.5 million people. The exclusion criteria included congenital deformity of the wrist, previous history of trauma, previous wrist injuries, and previous history of consumption of corticosteroids and anabolic drugs. Flow diagram of the study protocol is shown in Figure 1. Thirty patients with SN presented with avascular necrosis (AVN) in waist or proximal pole of the scaphoid were eligible for this study. The patients were divided into two groups of 15 patients based on patients' consent and hand surgeon's decision. The vascularity of scaphoid was determined using MRI imaging.

Fifteen cases were treated by VBG (VBG group) and 15 patients underwent nonvascularized iliac crest bone grafting<sup>[10,12]</sup> without hardware fixation (NVBG group). In the VBG group, VBG was done according to the Zaidenberg's technique,<sup>[10,12]</sup> then fixation was performed by 1.5 mm Kirschner (K) wire [Figures 2-4]. Postoperatively, all of the patients in both groups immobilized with a cast for at least 6 weeks and then the thumb spica casts and pins were removed if union was achieved, and afterwards wrist functional splints were used. Two of the patients in the VBG group were lost to follow-up after surgery. The remaining 28 patients were followed up at 2, 4, and 8 weeks after surgery and also control radiography was performed for them [Figure 5]. Finally, the patients were followed up for at least 10 months after the treatment and functional abilities of the patients in both groups were determined and compared using the disabilities

of the arm, shoulder, and hand (Quick DASH) questionnaire<sup>[13]</sup> and the Mayo modified wrist score<sup>[14]</sup> before and after the surgery. Furthermore, the severity of pain before and after the surgery was compared in both groups using the Visual Analog Scale (VAS) ranging from 0 (no pain) to 100 (maximal pain). Finally, post-treatment complications including locomotor restriction, wrist joint osteoarthritis, nerve injury associated with anesthesia, and motor impairment (due to tendon injury) were compared between the groups.

### Statistical analysis

Descriptive data were given as mean  $\pm$  standard deviation for each group. For continuous scales variables, we used *t*-test or Mann-Whitney *U*-test where applicable. In addition, to compare categorical variables, we used Chi-square, or Fisher's exact tests. Statistical analysis was performed using IBM SPSS Statistics 20 (SPSS Inc., Chicago, IL, USA). The value of *P* < 0.05 was considered statistically significant.

### Ethical approval

All procedures were in accordance with the ethical standards of the 1964 Helsinki declaration and its later amendments and were approved by Ethics Committee, Urmia University of Medical Sciences, Urmia, Iran, with the approval code IR.UMSU.REC.1397.107. The results of this study were part of student thesis. We also obtained informed consent from all of the participants.

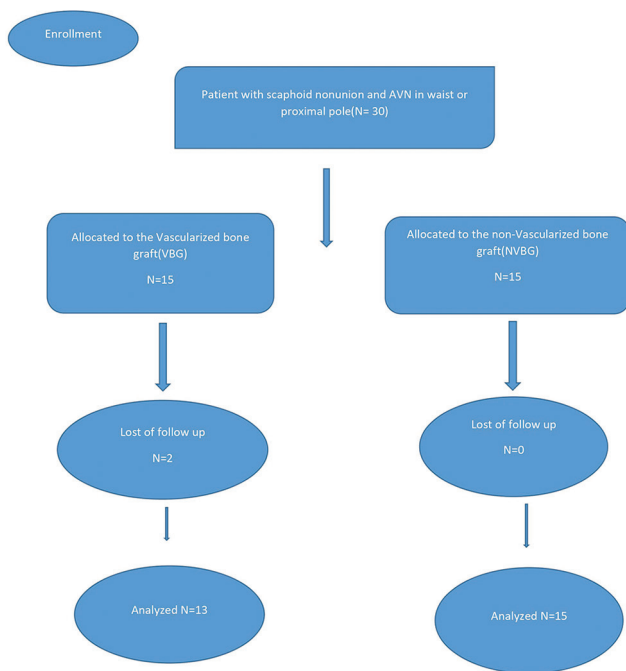
## RESULTS

The total number of participants included 28 patients with SN and AVN (27 males and 1 female) ranged from 20 to 47 years old with the mean age of  $27.4 \pm 6.7$  years. Thirteen patients (12 males and 1 female) were treated with VBG and 15 male patients were treated with NVBG. Demographic and clinical characteristics of the two groups are summarized

**Table 1: Demographic and clinical characteristics of the patients**

Characteristics	Total (n=28), n (%)	VBG (n=13), n (%)	NVBG (n=15), n (%)	<i>P</i>
Age (years)	27.4 $\pm$ 6.7	27.3 $\pm$ 6.8	27.5 $\pm$ 6.5	0.9
Sex				
Male	27	12	15	0.2
Female	1	1	–	
Injured hand				
Dominant	16 (57.1)	7 (53.8)	9 (60)	0.7
Nondominant	12 (42.8)	6 (46.2)	6 (40)	
Site of injury				
Proximal pole	9	3 (23.1)	6 (40)	0.3
Waist	19	10 (76.9)	9 (60)	
Time to surgery (months)	14.15 $\pm$ 4.5	14.9 $\pm$ 4.3	13.5 $\pm$ 4.6	0.4
Follow-up time (months)	16.03 $\pm$ 4.1 (10-24)	16.00 $\pm$ 4.6 (12-24)	16.06 $\pm$ 3.6 (10-22)	0.9

VBG: Vascularized bone graft, NVBG: Non-VBG

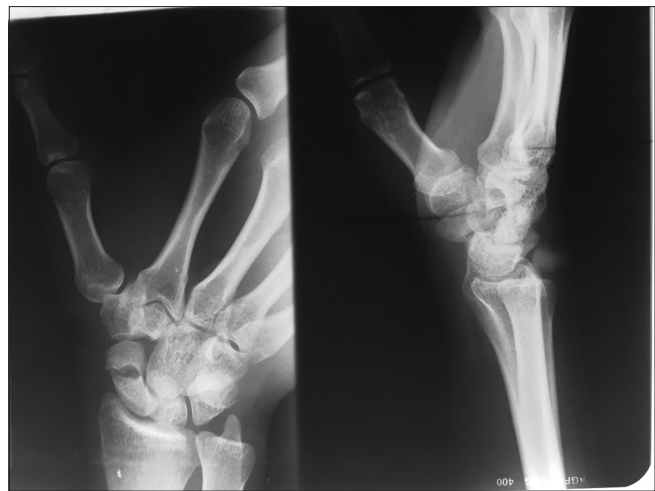

**Figure 1:** Flow diagram of the study protocol

in Table 1. There was no significant difference regarding sex ( $P = 0.2$ ) and age (independent  $t$ -test,  $P = 0.9$ ) between the two groups. The mean delay between the fracture and the surgery for the treatment of nonunion was almost the same in both groups (14.9 months in VBG vs. 13.5 months in NVBG;  $P = 0.4$ ). Furthermore, no significant difference was found regarding the injured hand, site of injury, and follow-up time.

Overall 23 patients achieved union in both groups. The rate of union was 92.3% ( $n = 12$ ) in the patients treated with VBG and 73.3% ( $n = 11$ ) in the patients treated with NVBG. Although more patients in the VBG group achieved union, there was no significant difference in the healing process between the two groups ( $P = 0.1$ ).

In vascularized bone grafts, superficial radial neuropathy was found in 4 cases (30.8%), and the complex regional pain syndrome was found in only 1 case (7.6%). None of these complications was found in the NVBG group. The postoperative outcomes of patients achieving union at the end of the follow-up time are shown in Table 2. The severity of pain was compared based on the VAS score between the two groups and the results showed statistically significant differences between the scores of the two groups ( $P = 0.03$ ). Furthermore, grip strength and an active range of motion (AROM) were compared in both grafts and significant differences were observed between the two groups for grip strength (vascularized vs. non VBG [NVBG];  $44.9 \pm 3.2$  vs.  $49 \pm 7.1$  kg;  $P = 0.01$ ). No significant difference was found in AROM between the groups ( $P = 0.20$ ). Table 3 compares the pre- and post-operative functions of the patients in both groups using Mayo-wrist and Quick DASH scores. The postoperative Quick DASH scores of the VBG and NVBG groups were  $5.6 \pm 1.1$  and  $8.4 \pm 2.3$ ,



**Figure 2:** Preoperative radiography indicating scaphoid nonunion

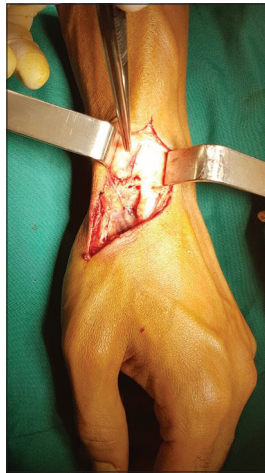respectively, which showed a significant difference ( $P = 0.001$ ). The functional improvement based on the postoperative Mayo score was significantly higher in the VBG group compared with the NVBG group ( $85.9 \pm 3.04$  vs.  $80.4 \pm 6.6$ ;  $P = 0.006$ ). In addition, Figures 6 and 7, respectively, show the changes in MAYO and Quick DASH scores of the two groups before and after surgery.

## DISCUSSION

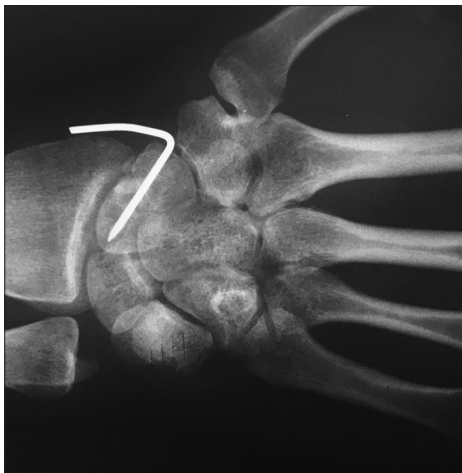The major goals of SN treatment are relieving pain and increasing function as well as prevention of degenerative osteoarthritis and carpal deformity.<sup>[15,16]</sup> Till now, various approaches have been used to treat SN such as NVBGs, VBGs, and dorsal and volar pedicled VBGs. Despite the VBG, which requires microsurgical treatment, these procedures are technically easier and are still widely performed.<sup>[6,17]</sup> In the current study, we demonstrated relatively better functional outcome scores in the VBG group despite higher rates of complications. In the present study, the rates of union in the VBG and NVBG groups were 92.3% and 73.3%, respectively; however, no significant difference was found in the healing process. Furthermore, the results of two other prospective studies showed better healing rates<sup>[18]</sup> and faster bone healing<sup>[19]</sup> using the VBG method. In a systematic review, Ferguson *et al.*<sup>[20]</sup> evaluated the outcomes of VBG and NVBG in 5464 patients with nonunion scaphoid and they reported that the union rates in patients treated with VBG and NVBG were 84% and 80%, respectively. Moreover, a recent review of evidence of 41 publications demonstrated 84.7% union rate at 13 weeks after surgery in patients treated with vascularized bone graft.<sup>[21]</sup> Thus, although there is a better outcome in patients treated with VBG, the union rates are relatively similar in both methods in most of the studies.

Avascular necrosis is considered a risk factor for SN in previous studies.<sup>[22,23]</sup> Furthermore, Chang *et al.*<sup>[24]</sup> demonstrated better union rates in patients without AVN. Malizos *et al.*<sup>[11]</sup> and Tsai *et al.*<sup>[25]</sup> found that AVN does not

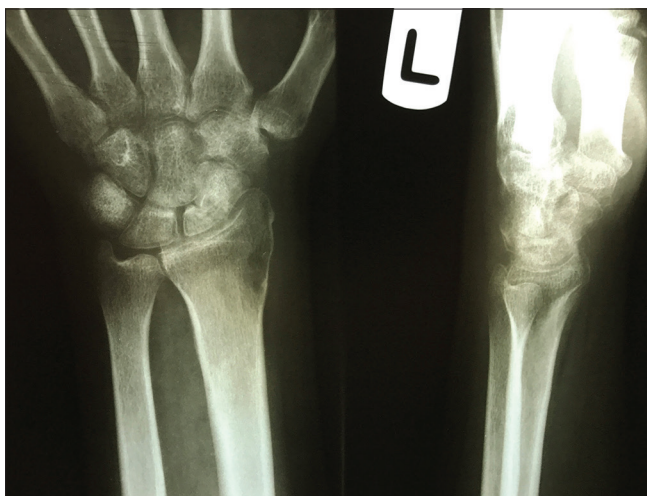have a significant impact on union rates. The present study included 24 patients with AVN; all of 13 patients in the VBG



**Figure 3:** Clinical photo showing the dorsal branch of radial artery in the preparation of vascularized distal radius bone graft



**Figure 4:** Postoperative radiography after graft insertion and fixation using K-wire



**Figure 5:** Final follow-up radiography indicating the union of scaphoid fracture

group and 11 patients in the NVBG group were diagnosed with AVN. We observed a high union rate in patients with AVN in both groups. Especially, there was a union rate of 92.3% in patients with AVN who underwent VBG. A recent meta-analysis of 1827 SN restoration also demonstrated the dominance of VBG in patients with AVN.<sup>[22]</sup> Furthermore, in the review of Ferguson *et al.*<sup>[20]</sup> they demonstrated that the union rates in patients with AVN who underwent VBG and NVBG were 75% and 62%, respectively. Most of the studies have reported VBG as a better method of treatment in patients with SN having AVN. However, since there is a controversy in the findings of studies investigating the impact of AVN on union rate, we recommend further studies to evaluate the effects of AVN on union following various methods of the SN treatment.

In the current study, complications were only found in vascularized bone grafts; 30.8% of the patients treated with VBG had superficial radial neuropathy and 6.7% of them had complex regional pain syndrome. In addition, in the review of Alluri *et al.*,<sup>[26]</sup> the most common complications were superficial infections (1.56%), neuropathic pain (1.56%), and complex regional pain syndrome (1.25%). In our study, we observed no complications in patients treated with NVBG. In addition, a low rate of complications occurrence in the review of Alluri *et al.* suggests that VBG is a better choice for SN.<sup>[27,28]</sup> The present study does not fully support this claim. Further studies, especially prospective ones with a large sample size are recommended to compare the occurrence of complications in both methods.

In both surgical techniques, acceptable functional outcomes were observed. The Quick Dash score was significantly

**Table 2: Clinical and functional outcomes of patients after surgical union using the visual analogue scale score, active range of motion, and grip strength**

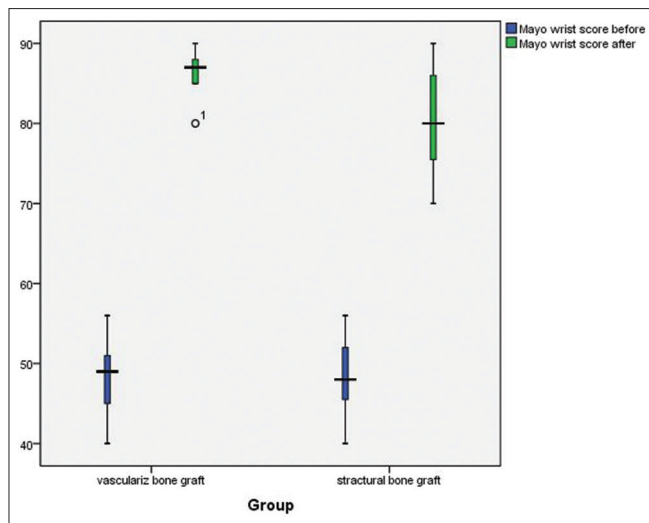
	VBG	NVBG	P
VAS score	41.7±5.1	59.8±10.8	0.03*
AROM (°)	105.5±4.9	103.2±4.4	0.2
Grip strength (kg)	44.9±3.2	49±7.1	0.01*

VBG: Vascularized bone graft, NVBG: Non-VBG, VAS: Visual Analog Scale, AROM: Active range of motion

**Table 3: Comparison of pre- and post-operative functions of patients in both groups using Mayo wrist and Quick DASH scores**

	Mayo wrist score		Quick DASH score	
	Preoperation	Postoperation	Preoperation	Postoperation
VBG (n=13)	48.3±4.3	85.9±3.04	27.7±1.5	5.6±1.1
NVBG (n=15)	48.4±4.7	80.4±6.6	28.2±2.3	8.4±2.3
P	0.9	<0.001*	0.5	<0.001*

VBG: Vascularized bone graft, NVBG: Non-VBG, Quick DASH: Quick disabilities of the arm, shoulder and hand



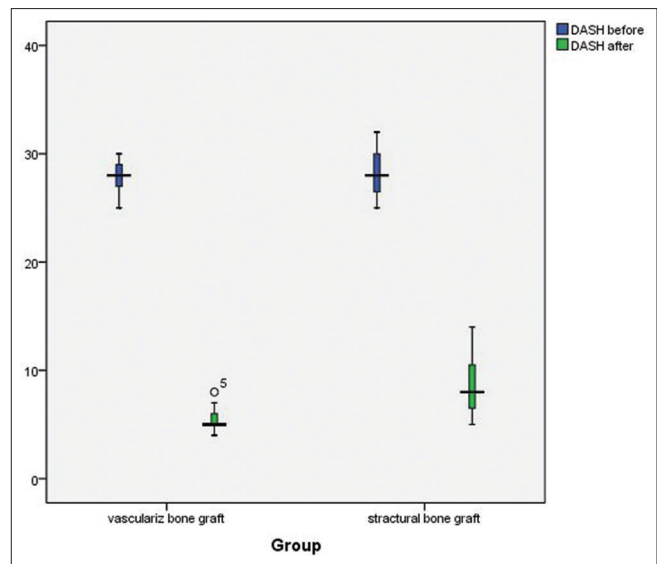
**Figure 6:** Changes in MAYO scores of the two groups before and after surgery

decreased in both groups in favor of the vascularized bone graft. The postoperative Mayo wrist score was increased from 48 to 85 in the VBG group and from 48 to 80 in the NVBG group and the difference was statistically significant. Furthermore, the VAS score and the grip strength were considerably higher in the NVBG group. In the study of Rahimnia *et al.*,<sup>[1]</sup> a modified Mayo wrist score (MMWS) improved from 60 to 83, postoperatively. Moreover, the Dash score decreased from 54 to 21, and grip strength decreased to 73% of the contralateral hand strength. This results are in accordance with those of Malizos *et al.*<sup>[11]</sup> and Hirche, *et al.*<sup>[29]</sup> Moreover, long-term results of SN surgeries in the study of Reigstad *et al.*<sup>[30]</sup> revealed that early surgery before the development of arthritis could positively affects MMWS, DASH, and VAS scores. Thus, both VBG and NVBG methods could be useful in the treatment of patients with SN, especially when it is conducted in an appropriate time. However, most of the studies consider VBG as a better method in improving the postoperative functions of SN.

One of the most considerable limitations of our study is the small sample size. Thus, the results of the current study cannot be generalized to the entire population. Furthermore, in the present study, we have not compared the function of the injured hand with the contralateral hand. Finally, we could not determine the exact healing time due to the long interval of follow-up. Studies with larger sample sizes, especially those evaluating and comparing the long-term outcomes of both methods, are strongly recommended in this field.

## CONCLUSION

Although the rate of complications occurrence in patients treated with vascularized bone graft is higher, it seems to be a preferable treatment option for SN in comparison with NVBG due to high union rates and better functional outcomes, especially in patients with AVN.



**Figure 7:** Changes in Quick DASH scores of the two groups before and after surgery. Quick DASH: Quick disabilities of the arm, shoulder and hand

## Financial support and sponsorship

Nil.

## Conflicts of interest

There are no conflicts of interest.

## REFERENCES

- Rahimnia A, Rahimnia AH, Mobasher-Jannat A. Clinical and functional outcomes of vascularized bone graft in the treatment of scaphoid non-union. *PLoS One* 2018;13:e0197768.
- Van Tassel DC, Owens BD, Wolf JM. Incidence estimates and demographics of scaphoid fracture in the U.S. population. *J Hand Surg Am* 2010;35:1242-5.
- Kawamura K, Chung KC. Treatment of scaphoid fractures and nonunions. *J Hand Surg Am* 2008;33:988-97.
- Düppe H, Johnell O, Lundborg G, Karlsson M, Redlund-Johnell I. Long-term results of fracture of the scaphoid. A follow-up study of more than thirty years. *J Bone Joint Surg Am* 1994;76:249-52.
- Malizos KN, Dailiana ZH, Innocenti M, Mathoulin CL, Mattar R Jr., Sauerbier M. Vascularized bone grafts for upper limb reconstruction: Defects at the distal radius, wrist, and hand. *J Hand Surg Am* 2010;35:1710-8.
- Harpf C, Gabl M, Reinhart C, Schoeller T, Bodner G, Pechlaner S, *et al.* Small free vascularized iliac crest bone grafts in reconstruction of the scaphoid bone: A retrospective study in 60 cases. *Plast Reconstr Surg* 2001;108:664-74.
- Munk B, Larsen CF. Bone grafting the scaphoid nonunion: A systematic review of 147 publications including 5,246 cases of scaphoid nonunion. *Acta Orthop Scand* 2004;75:618-29.
- Straw RG, Davis TR, Dias JJ. Scaphoid nonunion: Treatment with a pedicled vascularized bone graft based on the 1,2 intercompartmental supraretricular branch of the radial artery. *J Hand Surg Br* 2002;27:413.
- Taylor GI, Miller GD, Ham FJ. The free vascularized bone graft. A clinical extension of microvascular techniques. *Plast Reconstr Surg* 1975;55:533-44.
- Zaidemberg C, Siebert JW, Angrigiani C. A new vascularized bone graft for scaphoid nonunion. *J Hand Surg Am* 1991;16:474-8.
- Malizos KN, Zachos V, Dailiana ZH, Zalavras C, Varitimidis S, Hantes M, *et al.* Scaphoid nonunions: Management with vascularized bone grafts from the distal radius: A clinical and functional outcome study. *Plast Reconstr Surg* 2007;119:1513-25.

12. Cooney WP, Linscheid RL, Dobyns JH, Wood MB. Scaphoid nonunion: Role of anterior interpositional bone grafts. *J Hand Surg Am* 1988;13:635-50.
13. Hudak PL, Amadio PC, Bombardier C. Development of an upper extremity outcome measure: The DASH (disabilities of the arm, shoulder and hand) [corrected]. The Upper Extremity Collaborative Group (UECG). *Am J Ind Med* 1996;29:602-8.
14. Cooney WP, Bussey R, Dobyns JH, Linscheid RL. Difficult wrist fractures. Perilunate fracture-dislocations of the wrist. *Clin Orthop Relat Res* 1987;(214):136-47.
15. Pao VS, Chang J. Scaphoid nonunion: Diagnosis and treatment. *Plast Reconstr Surg* 2003;112:1666-76.
16. Milliez PY, Courandier JM, Thomine JM, Biga N. The natural history of scaphoid non-union. A review of fifty-two cases. *Ann Chir Main* 1987;6:195-202.
17. Robbins RR, Ridge O, Carter PR. Iliac crest bone grafting and Herbert screw fixation of nonunions of the scaphoid with avascular proximal poles. *J Hand Surg Am* 1995;20:818-31.
18. Ribak S, Medina CE, Mattar R Jr., Ulson HJ, Ulson HJ, Etchebehere M. Treatment of scaphoid nonunion with vascularised and nonvascularised dorsal bone grafting from the distal radius. *Int Orthop* 2010;34:683-8.
19. Caporrino FA, Dos Santos JB, Penteado FT, de Moraes VY, Belloti JC, Faloppa F. Dorsal vascularized grafting for scaphoid nonunion: A comparison of two surgical techniques. *J Orthop Trauma* 2014;28:e44-8.
20. Ferguson DO, Shanbhag V, Hedley H, Reichert I, Lipscombe S, Davis TR. Scaphoid fracture non-union: A systematic review of surgical treatment using bone graft. *J Hand Surg Eur Vol* 2016;41:492-500.
21. Alluri RK, Yin C, Iorio ML, Leland H, Mack WJ, Patel K. A critical appraisal of vascularized bone grafting for scaphoid nonunion. *J Wrist Surg* 2017;6:251-7.
22. Merrell GA, Wolfe SW, Slade JF 3<sup>rd</sup>. Treatment of scaphoid nonunions: Quantitative meta-analysis of the literature. *J Hand Surg Am* 2002;27:685-91.
23. Schuind F, Moungondo F, El Kazzi W. Prognostic factors in the treatment of carpal scaphoid non-unions. *Eur J Orthop Surg Traumatol* 2017;27:3-9.
24. Chang MA, Bishop AT, Moran SL, Shin AY. The outcomes and complications of 1,2-intercompartmental supraretinacular artery pedicled vascularized bone grafting of scaphoid nonunions. *J Hand Surg Am* 2006;31:387-96.
25. Tsai TT, Chao EK, Tu YK, Chen AC, Lee MS, Ueng SW. Management of scaphoid nonunion with avascular necrosis using 1, 2 intercompartmental supraretinacular arterial bone grafts. *Chang Gung Med J* 2002;25:321-8.
26. Alluri RK, Yin C, Iorio ML, Leland H, Wong J, Patel K. Vascularized bone grafting in scaphoid nonunion: A review of patient-centered outcomes. *Hand (N Y)* 2017;12:127-34.
27. Bratzler DW, Hunt DR. The surgical infection prevention and surgical care improvement projects: National initiatives to improve outcomes for patients having surgery. *Clin Infect Dis* 2006;43:322-30.
28. Macrae WA. Chronic post-surgical pain: 10 years on. *Br J Anaesth* 2008;101:77-86.
29. Hirche C, Heffinger C, Xiong L, Lehnhardt M, Kneser U, Bickert B, *et al.* The 1,2-intercompartmental supraretinacular artery vascularized bone graft for scaphoid nonunion: Management and clinical outcome. *J Hand Surg Am* 2014;39:423-9.
30. Reigstad O, Grimsgaard C, Thorkildsen R, Reigstad A, Rokkum M. Long-term results of scaphoid nonunion surgery: 50 patients reviewed after 8 to 18 years. *J Orthop Trauma* 2012;26:241-5.