

Nonoperative Management of Blunt Abdominal Trauma Cases at a Tertiary Care Center in India – An Effective Strategy

Tanvi Luthra, Karamjot Bedi, Shantanu Sahu, Sayani Banerjee¹

Departments of General Surgery and ¹Emergency Medicine, Himalayan Institute of Medical Sciences, SRHU, Dehradun, Uttarakhand, India

ORCID:

Tanvi Luthra: 0000-0003-2789-1053
Karamjot Bedi: 0000-0001-9203-4598
Shantanu Sahu: 0000-0003-2898-6329
Sayani Banerjee: 0000-0002-0241-0199

Abstract

Background and Objectives: An emerging paradigm is observed toward the application of nonoperative management for blunt abdominal trauma (BAT) over invasive surgery. It is postulated that the nonoperative approach is more effective financially, is safe and has a higher success rate. To evaluate the success of the shift from an aggressive operative approach to nonoperative management in solid organ injuries due to BAT at a tertiary care center in North India. **Materials and Methods:** An observational study was undertaken to evaluate the management of 95 cases of BAT presenting to the emergency department at a tertiary care center in North India, over 12 months. Operative and nonoperative managements were recorded, and the outcome was assessed at 72 h. Categorical variables were analyzed using the Chi-square test; $P < 0.05$ was taken to indicate a significant difference. **Results:** Out of the 95 patients, 46% were between 20 and 40 years and 84% were males. The most common mechanism of trauma was road traffic accidents (67%), followed by falls. Specific organ injuries were found in 59% of cases; of these, 38% were injuries to the liver and 34% to the spleen. Overall, 21% of all the cases underwent operative management, whereas 79% were managed nonoperatively. Nonoperative management showed satisfactory outcomes in 89% of cases overall. Furthermore, 88.90% of solid organ injuries with computed tomography American Association for the Surgery of Trauma (CT-AAST) Grades of III or above were successfully managed with nonoperative management. **Conclusions:** Nonoperative management shows successful results while allowing us to avoid surgical stress, complications, and financial burdens along with an acceptable morbidity rate and low mortality rate. A high CT-AAST grade of injuries does not warrant surgery, and operative management should be used judiciously.

Keywords: Abdominal trauma, blunt trauma, computed tomography American Association for Surgery of Trauma Score, nonoperative management

INTRODUCTION

Trauma-related injury is one of the major causes of death in India and worldwide. According to the World Health Organization, more than 5 million people die annually as a result of injury due to incidents, such as road traffic accidents (RTAs) and falls.^[1] Developing nations, like India, are most affected due to injury-related deaths, and these are found to be 1.7 times more than those caused by infectious diseases.^[2] With the exponential increase in vehicular density on Indian roads, the number of deaths due to RTAs is on the rise. The Ministry of Road Transport and Highways reported 464,910 RTAs in the year 2017 and recorded 147,913 fatalities because of the same.^[3] The

primary factors for mortality in cases of blunt abdominal trauma (BAT) are hemorrhage and sepsis.^[4] Most deaths in early cases of BAT are due to hemorrhage. Blood in the abdomen can be clinically inconspicuous due to sequestration within the peritoneal cavity.^[5] It is therefore essential to carry out thorough serial clinical examinations accompanied by

Address for correspondence: Dr. Karamjot Bedi,
Department of General Surgery, Himalayan Institute of Medical Sciences,
SRHU, Jolly Grant, Dehradun, Uttarakhand, India.
E-mail: kjbedi@gmail.com

This is an open access journal, and articles are distributed under the terms of the Creative Commons Attribution-NonCommercial-ShareAlike 4.0 License, which allows others to remix, tweak, and build upon the work non-commercially, as long as appropriate credit is given and the new creations are licensed under the identical terms.

For reprints contact: WKHLRPMedknow_reprints@wolterskluwer.com

How to cite this article: Luthra T, Bedi K, Sahu S, Banerjee S. Nonoperative management of blunt abdominal trauma cases at a tertiary care center in India – An effective strategy. *Arch Trauma Res* 2022;11:32-6.

Received: 09-07-2021,

Revised: 16-03-2022,

Accepted: 17-03-2022,

Published: 31-07-2022.

Access this article online

Quick Response Code:



Website:
www.archtrauma.com

DOI:
10.4103/atr.atr_54_21

radiological investigations in those patients who are likely to have intra-abdominal injuries to further guide therapy. Plain radiographs with evidence of lower rib fractures, diaphragmatic hernia, free air under diaphragm, and a fracture involving the pelvic rim suggest intra-abdominal injury. “Focused assessment with sonography for trauma (FAST)” has an important role in the detection of free intraperitoneal blood after blunt trauma in the hepatorenal space (Morrison’s pouch), splenorenal recess, inferior part of the pelvic cavity, and the pericardium which aids in guiding the management of trauma cases.^[6] However, due to a low sensitivity (82%), we cannot exclude intra-abdominal injury based on a normal ultrasound alone despite its benefits such as being economical, noninvasive, rapid, and repeatable. To date, computed tomography (CT) scan is the gold standard for assessing BAT^[7] and due to its high sensitivity (97%–98%) and specificity (97%–99%).^[8,9] Multidetector CT aids in the exact identification of the severity and extent of injury as per the American Association for the Surgery of Trauma (AAST) organ injury scale. Over the past two decades, there has been a significant shift in the application of nonoperative management for BAT rather than a more aggressive surgical approach.^[10] It is postulated that the nonoperative approach is more effective financially, is safe and has a higher success rate.^[11] This new opinion has laid strain on the importance of being very selective while choosing patients of trauma for exploratory laparotomy. The present study was undertaken at our center to study solid organ injury patients with a high CT-AAST injury score who were nonoperatively managed.

MATERIALS AND METHODS

This observational prospective study was conducted by recruiting all patients of BAT visiting the emergency department of a tertiary care center in North India, over a period of 12 months (January 2018–December 2018) after taking written informed consent. The study was approved by the institutional ethics committee.

Cases of penetrating abdominal trauma, pregnant women with gestational age more than 3 months, age <18 years, and patients on warfarin or those with Glasgow Coma Scale <13 were excluded from the study.

All recruited patients underwent primary and secondary surveys with robust concomitant resuscitation as per Advanced Trauma Life Support guidelines. As adjuncts to clinical examination, FAST was done in all patients, while X-rays of chest, cervical spine, and pelvis were done for all hemodynamically stable patients. CT scan with iv contrast were done for all hemodynamically stable patients selected for the nonoperative arm of management to grade the severity of organ injury. The nonoperatively managed patients were serially reassessed and closely monitored. The outcome of all patients was recorded at 72 h as satisfactory, morbidity, or mortality. Satisfactory outcomes meant hemodynamic stability and no need for intensive care. Morbidity included the need

for repeated interventions, intensive care unit (ICU) care, and ventilator support with or without inotropic support. Mortality outcome included demise at or within 72 h of presentation.

Figure 1 gives a summary of the protocol followed for the recruited patients.

Statistical analysis was performed by the SPSS program for Windows, version 17.0. Continuous variables are presented as mean \pm standard deviation, and categorical variables are presented as absolute numbers and percentages. Data were checked for normality before statistical analysis, and categorical variables were analyzed using the Chi-square test. For all statistical tests, $P < 0.05$ was taken to indicate a significant difference.

RESULTS

Among the total of 95 subjects recruited in this study to evaluate the success of nonoperative management in solid organ injuries due to BAT, the majority (46%) were found in the age group of 20–40 years and were predominantly males (84%). The mean age was 40.57 years. Most cases (67%) were due to RTAs. In addition, recorded causes included fall from height, assault, and other accidents (including animal mauling, electrocution, or fall of a heavy object over the abdomen).

Specific organ injuries were found in 56 instances, and these were categorized based on the injured organ [Figure 2].

All 12 bowel injury cases, diagnosed as pneumoperitoneum on radiographs, were taken up for surgery without further radiological investigations.

The 44 cases with solid organ injury underwent abdominal CT scans and were graded based on the AAST score [Table 1].

Persistent hemodynamic instability in solid organ injuries despite resuscitation (8 subjects), hollow viscus injury (12 subjects) and a high clinical suspicion remained the deciding factors for operative intervention which was done in 20 patients [Table 2].




Figure 1: Protocol of the study

All the eight subjects with solid organ injuries who showed persistent hemodynamic instability were found to have CT-AAST scores of III or more than III. These CT findings were also confirmed based on the intraoperative findings.

Satisfactory outcome was seen in 13 out of 20 operated patients while morbidity (four cases showed wound infection and one patient showed controlled biliary fistula from the surgical wound) was noted in five cases and mortality in two.

Nonoperative management was done for 75 subjects comprising 39 cases of blunt abdominal injuries without any specific organ injuries and 36 cases (out of 44) who had proven solid organ injuries based on their CT scans.

A satisfactory outcome was seen in 67 out of 75 subjects managed nonoperatively.

Morbidity was observed in seven patients (five cases needed mechanical ventilation and two cases needed continued

inotropic support under ICU care even after 72 h). Mortality was recorded in one patient whose death occurred within the first 24 h of admission.

The correlation between management options and outcome was calculated, and it was observed that nonoperative management showed a higher proportion of satisfactory outcomes and a lower morbidity and mortality proportion when compared to operative management ($P = 0.019$) [Table 3].

Out of the 36 patients with solid organ injuries under the nonoperative management arm, 75% (27 cases) had high CT-AAST scores (score of III or above). Majority of these patients (88.90%) showed satisfactory outcomes with nonoperative management at 72 h [Table 4].

Table 1: American Association for the Surgery of Trauma scores of various solid organ injuries recorded in the study based on computed tomography scan results (n=44)

AAST grade Organ injured	I	II	III	IV	V	VI	Total
Liver	1	5	9	6	0	0	21
Spleen	0	2	13	1	3	0	19
Pancreas	0	0	1	1	1	0	3
Kidney	0	1	0	0	0	0	1
Total	1	8	23	8	4	0	44

AAST: American Association for the Surgery of Trauma

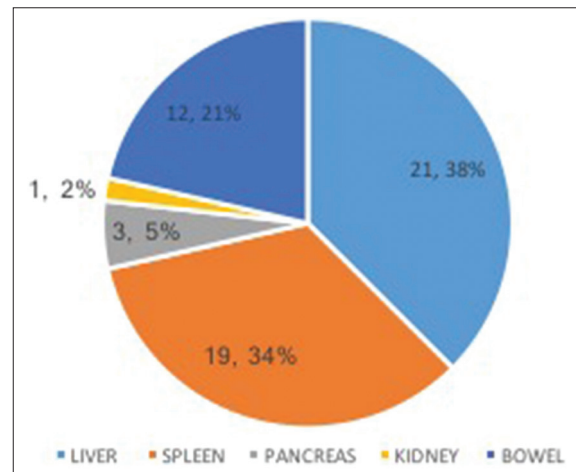


Figure 2: Injured organ (n = 56)

Table 2: Surgical procedures performed on subjects in the study distributed based on the injured organ (n=20)

Organ injury identified intraoperatively	Surgical intervention	n=20
Bowel (12)		
Small bowel perforation	Primary repair of perforation	6
Bowel gangrene due to SMV thrombosis	Resection of gangrenous bowel and anastomosis to establish bowel continuity	2
Perianal and rectal tear	Diversion colostomy	3
Small bowel transection 5ft from DJ flexure with gangrene in the transected bowel until splenic flexure	DCS done in 2 stages – Exploration and end jejunostomy; Resection of gangrenous bowel, and abdominal closure	1
Solid organ (8)		
Liver		
Liver laceration	Liver packing	4
Spleen		
Shattered spleen	Splenectomy	2
Pancreas		
Distal pancreas transection	Distal pancreatectomy + splenectomy	2
Total		12+8=20

SMV: Superior mesenteric vein, DJ: Duodenojejunal, DCS: Damage control surgery

Table 3: Comparison of management and outcome of subjects in the study (n=95)

	Total, n (%)	Satisfactory, n (%)	Morbidity, n (%)	Mortality, n (%)	P
Nonoperative	75 (78.9)	67 (89.3)	7 (9.3)	1 (1.4)	0.019
Operative	20 (21.1)	13 (65)	5 (25)	2 (10)	
Total	95 (100)	80 (84.21)	12 (12.63)	3 (3.16)	

Table 4: Outcome of patients with high-grade injuries at 72 h, computed tomography-American Association for the Surgery of Trauma scores of III or more (n=27)

Outcome	(n=27)
Satisfactory	24 (88.90)
Morbidity	2 (7.40)
Mortality	1 (3.70)
Total	27 (100)

Failure of nonoperative management was noted in 2 cases out of 75 (0.03%). One was of a 38-year-old male with Grade IV liver injury who presented with biliary peritonitis on posttrauma day 7 for which he underwent a laparotomy and successful repair of the liver laceration. The other case was of a 28-year-old male who presented with shock on posttrauma day 6 after nonoperative management due to delayed splenic rupture for which emergency splenectomy was done. Both patients had an uneventful postoperative phase.

DISCUSSION

Trauma is a subject gaining tremendous attention in the present day in developing as well as developed nations. BAT is an entity which is difficult to diagnose and manage because of its conspicuous nature when compared with penetrating injuries. The 95 subjects of BAT recruited herein were mostly males, between the age group of 20–40 years. Most of the cases were due to RTAs. Similar demographic patterns have earlier been noted in Indian^[7] and international studies.^[8]

Spleen and liver were found to be the most commonly injured organs in the abdominal trauma patients in our study and almost 80% (35 out of 44) of the solid organ injuries had AAST scores of III or above. Similar trends were found in the study by Tinkoff *et al.* done based on the National Trauma Data Bank in the USA^[12] and in the study by Nishijima *et al.*^[13]

high-grade solid organ injuries, with AAST scores of III and above were assessed separately and it was found that 27 out of 35 cases (77%) were managed with nonoperative management. Satisfactory outcome at 72 h was noted in 24 out of 27 such cases (88.90%) [Table 4]. Nonoperative management was thus justified as the treatment of choice even in patients with high-grade solid organ injuries in the setting of hemodynamic stability. Similar conclusions were made by Ruscelli *et al.*,^[14] Brillantino *et al.*,^[15] and Sisodiya and Malpani,^[16] who documented the overall success of nonoperative management with an acceptable rate of morbidity irrespective of the grade of injury.

Persistent hemodynamic instability despite adequate resuscitation and the evidence of hollow viscus injury leading to peritonitis were the only reasons which warranted operative management herein this study. Nonoperative management showed satisfactory outcomes in 89% of cases and was the preferred choice for managing patients with blunt abdominal injuries. This shift in management trend toward

the nonoperative approach is supported by the findings of various studies including the likes of a study by Okuş *et al.*^[17] which found a similar success rate of 86.3% with nonoperative management.

In this study, we monitored BAT patients from the time of presentation until 72 h and recorded the details of two cases that were classified as failures of nonoperative management. Literature published for blunt splenic injuries by Peitzman *et al.* in their multi-institutional study of the Eastern Association for the Surgery of Trauma,^[18] McCray *et al.*^[19] and Smith *et al.*,^[20] and those for blunt hepatic injuries by Parks *et al.*^[21] support that most failures of nonoperative management occur within 48–72 h. Although this period of observation has proven adequate for most patients, we must not ignore the need to assess the causes and preventive measures needed for late failures of nonoperative management who can present even a week after the original trauma without any associated inciting factors.

The limitations of our study are that due to its observational design, a precise comparison between groups managed operatively and nonoperatively could not be done; and the posttrauma and postoperative complications in the patients could not be adequately assessed due to lack of a follow-up design due to time constraints. Osler *et al.*^[22] identified a list of 82 different complications which contributed significantly to mortality in trauma patients and suggested that if all complications were eliminated, then two-thirds of deaths could be prevented. A study conducted by Chaudhry *et al.*^[23] showed that postcomplications in trauma in Indian patients included a high wound infection rate (50%–500%), intra-abdominal abscess (25%–8%), enterocutaneous fistula (20%–25%), and abdominal hypertension (20%).

Despite the drawbacks, our study identified very low rates of morbidity and mortality in the study subjects which indicates a good trauma protocol at our center. The study concurs with the rationale behind the major shift from mandatory to a selective surgical approach for solid organ injuries over the years, studied in detail by Leppäniemi,^[24] and is in accordance with the evidence-based guidelines developed by the International Consensus Conference held in Milan in December 2016.^[25]

Summary

Based on the findings of this observational study, nonoperative management emerged to be successful overall. Further, nonoperative management was also effective in patients who had high-grade injuries, with AAST scores of III or above. Morbidity and mortality could not solely be assessed based on the AAST grade of solid organ injuries. Operative intervention was justified only in cases of hollow viscus injuries and in patients who remained hemodynamically unstable despite resuscitation.

CONCLUSION

The golden rule of management of BAT injuries is nonoperative management when it is done for hemodynamically stable

patients with careful monitoring and good patient selection. A high CT-AAST grade of injuries does not warrant surgery, and operative management should be used judiciously. Nonoperative management shows successful results while allowing us to avoid surgical stress, complications, and financial burdens along with an acceptable morbidity rate and low mortality rate.

Financial support and sponsorship

Nil.

Conflicts of interest

There are no conflicts of interest.

REFERENCES

- Musalar E, Ersel M, Akarca FK, Kıyan GS, Can Ö. The predictive value of biochemical parameters in evaluating patients with abdominal trauma: The new scoring system. *Turk J Emerg Med* 2017;17:48-55.
- Choi SJ, Oh MY, Kim NR, Jung YJ, Ro YS, Shin SD. Comparison of trauma care systems in Asian countries: A systematic literature review. *Emerg Med Australas* 2017;29:697-711.
- Road Accidents in India 2017. Available from: <http://www.indiaenvironmentportal.org.in/files/file/road%20accidents%20in%20India%202017.pdf>. [Last accessed on 2019 May 04].
- Weledji P, Tambe J. Perspectives on the management of abdominal trauma. *Univers Surg* 2018;6:17. Available from: <http://www.jusurgery.com/abstract/perspectives-on-the-management-of-abdominal-trauma-23106.html>. [Last accessed on 2019 Mar 29].
- Lubner M, Menias C, Rucker C, Bhalla S, Peterson CM, Wang L, *et al.* Blood in the belly: CT findings of hemoperitoneum. *Radiographics* 2007;27:109-25.
- Focused Abdominal Sonography for Trauma in the Clinical Evaluation of Children with Blunt Abdominal Trauma. Available from: <https://www.ncbi.nlm.nih.gov/pubmed/26155302>. [Last accessed on 2017 Oct 11].
- Shojaee M, Faridaalae G, Yousefifard M, Yaseri M, Arhami Dolatabadi A, Sabzghabaei A, *et al.* New scoring system for intra-abdominal injury diagnosis after blunt trauma. *Chin J Traumatol* 2014;17:19-24.
- Peitzman AB, Makaroun MS, Slasky BS, Ritter P. Prospective study of computed tomography in initial management of blunt abdominal trauma. *J Trauma* 1986;26:585-92.
- Holmes JF, McGahan JP, Wisner DH. Rate of intra-abdominal injury after a normal abdominal computed tomographic scan in adults with blunt trauma. *Am J Emerg Med* 2012;30:574-9.
- Kokabi N, Shuaib W, Xing M, Harmouche E, Wilson K, Johnson JO, *et al.* Intra-abdominal solid organ injuries: An enhanced management algorithm. *Can Assoc Radiol J* 2014;65:301-9.
- Rosen CL, Legome EL, Wolfe RE. 79 – Blunt Abdominal Trauma. 2013.
- Tinkoff G, Esposito TJ, Reed J, Kilgo P, Fildes J, Pasquale M, *et al.* American Association for the Surgery of Trauma organ injury scale I: Spleen, liver, and kidney, validation based on the national trauma data bank. *J Am Coll Surg* 2008;207:646-55.
- Nishijima DK, Simel DL, Wisner DH, Holmes JF. Does this adult patient have a blunt intra-abdominal injury? *JAMA* 2012;307:1517-27.
- Ruscelli P, Gemini A, Rimini M, Santella S, Candelari R, Rosati M, *et al.* The role of grade of injury in non-operative management of blunt hepatic and splenic trauma: Case series from a multicenter experience. *Medicine (Baltimore)* 2019;98:e16746.
- Brillantino A, Iacobellis F, Festa P, Mottola A, Acampora C, Corvino F, *et al.* Non-operative management of blunt liver trauma: Safety, efficacy and complications of a standardized treatment protocol. *Bull Emerg Trauma* 2019;7:49-54.
- Sisodiya S, Malpani P. A retrospective study of blunt trauma abdomen in a tertiary center in central India: Evaluation, management and outcome. *Int Surg J* 2020;7:2696.
- Okuş A, Sevinç B, Ay S, Arslan K, Karahan Ö, Eryılmaz MA. Conservative management of abdominal injuries. *Ulus Cerrahi Derg* 2013;29:153-7.
- Peitzman AB, Heil B, Rivera L, Federle MB, Harbrecht BG, Clancy KD, *et al.* Blunt splenic injury in adults: Multi-institutional Study of the Eastern Association for the Surgery of Trauma. *J Trauma* 2000;49:177-87.
- McCray VW, Davis JW, Lemaster D, Parks SN. Observation for nonoperative management of the spleen: How long is long enough? *J Trauma* 2008;65:1354-8.
- Smith J, Armen S, Cook CH, Martin LC. Blunt splenic injuries: Have we watched long enough? *J Trauma* 2008;64:656-63.
- Parks NA, Davis JW, Forman D, Lemaster D. Observation for nonoperative management of blunt liver injuries: How long is long enough? *J Trauma* 2011;70:626-9.
- Osler T, Glance LG, Hosmer DW. Complication-associated mortality following trauma: A population-based observational study. *Arch Surg* 2012;147:152-8.
- Chaudhry R, Tiwari GL, Singh Y. Damage control surgery for abdominal trauma. *Med J Armed Forces India* 2006;62:259-62.
- Leppäniemi A. Nonoperative management of solid abdominal organ injuries: From past to present. *Scand J Surg* 2019;108:95-100.
- Cimbanassi S, Chiara O, Leppaniemi A, Henry S, Scalea TM, Shanmuganathan K, *et al.* Nonoperative management of abdominal solid-organ injuries following blunt trauma in adults: Results from an International Consensus Conference. *J Trauma Acute Care Surg* 2018;84:517-31.