

Correlation of Clinical Examination, MRI and Arthroscopy Findings in Menisco-Cruciate Injuries of the Knee: A Prospective Diagnostic Study

Ranajit Panigrahi,^{1*} Ashok Priyadarshi,¹ Nishit Palo,¹ Hatia Marandi,¹ Dinesh Kumar Agrawalla,² and

Manas Ranjan Biswal¹

¹Department of Orthopedics, Hi-Tech Medical College & Odisha, South Korea

²MD Radiodiagnosis Assistant Professor, Department of Radiology, Hi-Tech Medical College & Odisha, South Korea

*Corresponding author: Ranajit Panigrahi, Department of Orthopedics, Hi-Tech Medical College & Odisha, South Korea. Tel: +91-9777037435, E-mail: ranajitpanigrahi@gmail.com

Received 2015 May 03; Revised 2016 May 29; Accepted 2016 September 30.

Abstract

Background: The aim of this study was to examine the correlation of the clinical examination, MRI and arthroscopic findings in cruciate ligaments and meniscal injuries of knee and to evaluate the accuracy of clinical examination and MRI with the gold standard arthroscopy.

Methods: A prospective diagnostic double-blind study was conducted on 104 consecutive patients admitted to the outdoor/casualty with trauma to the knee complaining of knee pain/locking/ instability, from August 2012 to June 2014. All the patients were subjected to clinical examination, MRI scanning and diagnostic arthroscopy. Variables like sensitivity, specificity, positive predictive value, negative predictive value and accuracy of clinical examination and MRI against arthroscopy were evaluated.

Results: The sensitivity, specificity and accuracy of clinical examination for anterior cruciate ligament tears were 94.7%, 71.4% and 88.5% and for MRI were 94.7%, 78.6% and 90.4%, respectively; for posterior cruciate ligament tears 100%, 100% and 100% for clinical examination and for MRI 80%, 97.9% and 96.2%, respectively. These values for medial meniscus tears were 76.5%, 68.6% and 71.2% for clinical examination and 88.2%, 62.8% and 71.2% respectively for MRI. For lateral meniscus tears, 40%, 94.6% and 78.8% for clinical examination and 46.7%, 89.2% and 76.9% respectively for MRI.

Conclusions: A skillfully performed clinical examination establishes a diagnosis on which an arthroscopic procedure can be planned, reserving MRI scans for patients where the clinical examination fails to establish a diagnosis or cannot be performed. Decision to use MRI should be based on the criteria that it would confirm, expand the diagnosis or change diagnosis in such a way that alters the proposed treatment.

Keywords: Arthroscopy, MRI, Clinical Examination, Knee Injury

1. Background

Knee joint is the primary weight bearing joint and one of the most commonly injured joints owing to its anatomical structure, exposures to external forces and functional demands placed on it (1). Knee injuries are on a rise due to increased involvement in sports, motor accidents, and workplace injuries, which represent roughly 6% of acute injuries, treated at emergency department and 27% - 48% of these; are sports related (2). A knee injury affects the stability of knee and thus impairs a person to carry out routine daily activities. Therefore, early comprehensive diagnosis and management of these intra-articular injuries holds a pivotal role in patient's functional recovery and work performance.

Previously, orthopedic surgeons relied on clinical examination, till the advent of arthroscopy where, numerous reports on its role in diagnosis and treatment of various knee disorders were reported (3), which today has established itself as a gold "reference" standard in intra-articular pathologies of the knee joint (3). Magnetic resonance imaging (MRI) shares the advantage of being a noninvasive, highly sensitive investigation for the intra-

articular structures of knee but it is a costly investigation with very high inter-observer variations and minimal therapeutic potential.

In recent days, it is often seen that due to heavy working hours and overdependence on higher investigations patients with knee injuries are prescribed MRI scans without proper clinical examination. Being a highly sensitive modality, MRI suggests pathology even in asymptomatic or clinically normal patients, making it nonreliable for establishing the diagnosis alone. Also, the cost and need for instrumentation makes MRI a difficult investigation to be performed in all instances, especially in a country like ours.

Although, previous studies have compared the correlation of MRI and arthroscopy but to our knowledge, not many prospective diagnostic studies have compared the three modalities vis-avis clinical examination, MRI and arthroscopy in diagnosis of meniscal and cruciate ligament injuries.

2. Objectives

Thus, we initiated this prospective diagnostic study to compare and correlate the clinical examination, MRI and

arthroscopy in diagnosing cruciate ligaments and meniscal injuries and to evaluate the diagnostic accuracy of the two modalities with the gold standard arthroscopy.

3. Methods

This was a prospective diagnostic study on knee injuries to compare clinical examination, MRI and arthroscopy. Once the present research project was approved by the ethical committee of our institution, 104 consecutive patients with a history of trauma to the knee and with complaints of knee pain or locking or instability in our outdoor/casualties were included from August 2012 to June 2014. The participants declared their consent to participate in the study.

This was a prospective diagnostic study initiated after institutional ethical committee clearance (HMCH/IEC 672; 30). We compared patients with knee injuries and derangement of intra-articular soft tissue structures like menisci and cruciate ligaments by using three diagnostic modalities (clinically, arthroscopically and on MRI investigation) to correlate the efficacy of these modalities.

Inclusion criteria were as follows: male/female patients, age 18-50 years, American Society of Anesthesiologists grade I and II, and recent or old trauma to the knee with a history of knee pain/locking/instability.

Also, patients with contraindications to MRI, contraindications to arthroscopy superficial skin infection, tuberculosis knee, septic arthritis or neoplasms and those with a history of previous ligament reconstruction or arthroscopic knee procedures, joint inflammatory disease or neoplasm, and also patients who refused surgery or consent were excluded from the study.

3.1. Methodology

All the 104 patients were subjected to clinical examination, MR imaging and diagnostic arthroscopy. Patients with an old injury were subjected to the 3 investigations within 24 hours of presentation. Patients with a recent knee injury were managed initially with conservative measures such as rest, ice pack application, compression and elevation and were subjected to the 3 investigations at the end of three weeks. Clinical examination and diagnostic arthroscopy were performed by different orthopedic surgeons and MRI was performed by an experienced radiologist. All the clinicians were blinded of each other's findings. The results were penned down and sealed in an envelope by each examiner. Results of all the three investigations were tabulated at the end of the investigations. After all the investigations were completed, the data for medial collateral ligament, lateral collateral ligament and

posterolateral corner injuries were excluded and the results were tabulated only for anterior cruciate ligament (ACL), posterior cruciate ligament (PCL), medial meniscus and lateral meniscus.

3.2. Clinical Examination

Clinical examination was carried out by the same orthopedic surgeon, which included the presence of effusion, range of motion, joint line tenderness, varus and valgus stress tests, three (Sagittal plane-antero/posterior, frontal plane-abduction/adduction and coronal plane-internal/external rotation) stability tests of the knee. Standard clinical tests were used for diagnosing pathologies. For meniscal injuries, McMurray's and Apley's tests were used. Tests used for ACL injuries were anterior drawer test, Lachmann's test and Pivot shift test; for PCL injuries posterior drawer test, posterior tibial sag sign and quadriceps active test. For rotatory instabilities, the Slocum's test and Dial test were used.

3.3. MRI Evaluation

MRI was performed for all the patients to correlate the clinical diagnosis and for obtaining additional information. MR imaging was performed on a 1.5 Tesla MR scanner with a phased-array knee coil. All the patients had T1 and T2 weighted and proton dense sequences on coronal and sagittal plane images, without contrast. Magnetic resonance pulse sequences include fast spin echo (FSE) and fast recovery. The MRI protocol consists of fat-suppressed PD (TE 45, TR 2800) in axial, sagittal, and coronal planes, T2W (TE 80, TR 4000) in sagittal plane and T1W (TE 11, TR 495) in sagittal plane. The slice thickness was 4 mm. All MRIs were reported by the same radiologist at our institute who was blind of clinical diagnosis and was provided with only patient's identifying data. Complete as well as partial tears of anterior and posterior cruciate ligaments were interpreted as ruptures. Meniscal tears were graded from I to III. MRI findings

were recorded as per the modified preform in relation to our subject of the study.

3.4. Arthroscopy Evaluation

Arthroscopic procedures were performed under spinal anesthesia. The operating surgeon was blinded about the clinical and MRI findings. Standard arthroscopy portals were used in all cases and if required other portals were made. Following diagnostic arthroscopy, therapeutic procedure was carried out in the same sitting if required.

3.5. Statistical Analysis

Clinical examination, MRI and arthroscopic findings were tabulated on Microsoft excel spreadsheet and studied for correlation. The sensitivity, specificity, positive predictive value, negative predictive value and accuracy were then calculated and expressed as percentage. The t-test was used for comparison. P value for accuracy of clinical examination and MRI was then calculated.

4. Results

In the present study population, patients were from 18 to 50 years with a mean age of 30.21 ± 9.12 years; 50 patients (48.1%) in the age group 21 - 30 years, 22 (21.1%) in 31 - 40 years, 16 in 11 - 20 years and 16 cases in the 41 - 50 year age group. The number of male and female patients and the side of knee involved are shown in Table 1. The most common mode of injury was sport-related injuries in (50%), followed by road traffic accidents in 30.8% and self-fall in 19.2% of the patients. Among the intra-articular structures, ACL was the most common and PCL was the least to be involved. Arthroscopy in the 104 patients confirmed 76 ACL tears, 34 medial meniscus tears, 30 lateral meniscus tears and 10 PCL tears. The medial meniscus injury (34 cases) was more common than the lateral meniscus injury (30 cases). Figure 1 shows the pattern of tears in medial meniscus. The most common site of tear was body and posterior horn. The most common site of tear for lateral meniscus was the posterior horn, for pattern of tears in lateral meniscus (Figure 2).

Table 1. Demographic Data for the Patients (n = 104)

Variables	
Mean Age, y	30.21 ± 9.12
Gender, M/F	94/10
Side, R/L	40/64

Comparison of clinical examination with arthroscopy and MRI with arthroscopy, in terms of the total number of true-positive, false-positive, true-negative and false-negative cases for ACL, PCL, medial meniscus and lateral meniscus tears are represented in Tables 2 and 3, respectively.

On arthroscopy, out of 76 ACL tears, in clinical examination, 4 were missed initially, out of which 2 were chronic ACL tears and 2 were partial tears of ACL and 8 cases were false-positive. In MRI, 4 cases were missed with 6 false-positive cases. Out of 10 PCL tears, 100% were diagnosed on clinical examination, confirmed on arthroscopy but on MRI 2 cases were missed.

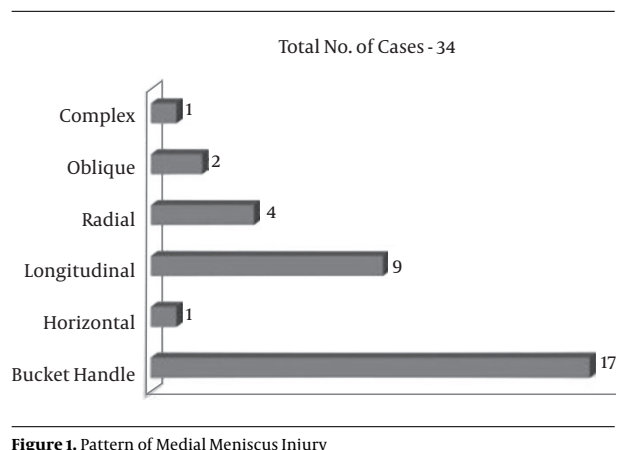


Figure 1. Pattern of Medial Meniscus Injury

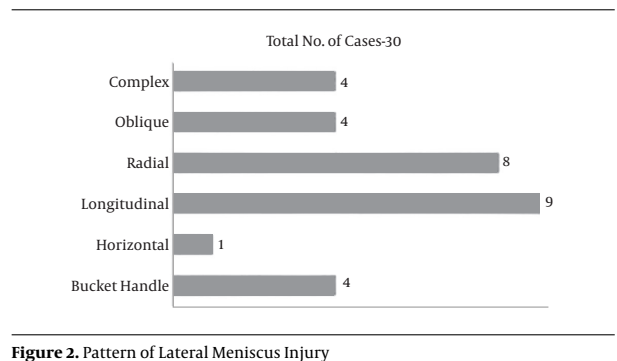


Figure 2. Pattern of Lateral Meniscus Injury

Out of the 34 medial meniscus tears, 8 were missed on clinical examination, 3 of which were grade-1 tears (increased intra-substance signal), which were not diagnosed clinically or arthroscopically with 22 false-positive cases. In MRI, 4 cases were missed with 26 false-positive cases. Two cases were of combined injury with locked knee in which clinical examination could not be done and an ACL tear with bucket handle tear of medial meniscus was found on MRI and arthroscopy. In 30 lateral meniscus tears, 18 were missed on clinical examination, 1 of which was grade-1 tear (increased intrasubstance signal) which was not diagnosed clinically or arthroscopically with 4 false-positive cases. In MRI, 16 cases were missed with 8 false-positive cases.

Sensitivity, specificity, positive predictive value, negative predictive value and accuracy of clinical examination and MRI v/s arthroscopy for ACL tears are represented in Figure 3, and for PCL tears are represented in Figure 4.

Comparing the accuracy of clinical examination with MRI, it was found to be significant for ACL ($P < 0.01$), PCL ($P < 0.01$), medial meniscus ($P < 0.01$) and for lateral meniscus ($P < 0.01$).

Table 2. Comparison Between Clinical and Arthroscopic Diagnoses for Lesions of the Anterior Cruciate Ligament, Posterior Cruciate Ligament, Medial Meniscus and Lateral Meniscus (Total No. Cases-104)

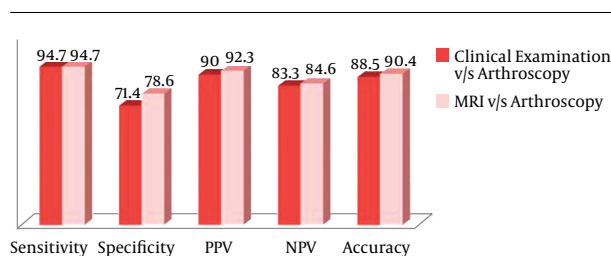
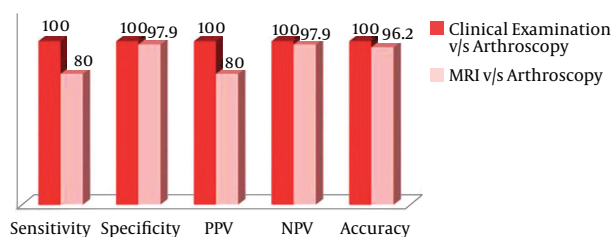
	True-Positive	False-Positive	True-Negative	False-Negative
ACL	72	8	20	4
PCL	10	0	94	0
MM	26	22	48	8
LM	12	4	70	18

Abbreviations: ACL, anterior cruciate ligament; PCL, posterior cruciate ligament; MM, medial meniscus, LM, lateral meniscus.

Table 3. Comparison Between MRI and Arthroscopic Diagnoses for Lesions of Anterior Cruciate Ligament, Posterior Cruciate Ligament, Medial Meniscus and Lateral Meniscus (Total No. of Cases-104)

	True-Positive	False-Positive	True-Negative	False-Negative
ACL	72	6	22	4
PCL	8	2	92	2
MM	30	26	44	4
LM	14	8	66	16

Abbreviations: ACL, anterior cruciate ligament; PCL, posterior cruciate ligament; MM, medial meniscus; LM, lateral meniscus.

**Figure 3.** Sensitivity, Specificity, Positive Predictive Value, Negative Predictive Value and Accuracy of Clinical Examination and MRI With Respect to Arthroscopy for Anterior Cruciate Ligament (%)**Figure 4.** Sensitivity, Specificity, Positive Predictive Value, Negative Predictive Value and Accuracy of Clinical Examination and MRI With Respect to Arthroscopy for the Posterior Cruciate Ligament (%)

5. Discussion

Clinical examination is a time-tested, easy and rapid method, which does not require instrumentation and with

a high specificity supplemented by a detailed history it becomes an effective screening tool for establishing an initial diagnosis. Magnetic resonance imaging has a high inter-observer variation, lacks specificity and is associated with a lot of false positive results.

Also, the cost and availability of MRI scans makes them less practical for use especially in country like ours for diagnosis of multiligamentous knee injury alone. Arthroscopy as a gold standard for diagnosing multiligamentous injuries is a minimally invasive, highly specific modality and it allows direct visualization of the joint from within and subsequent therapeutic intervention.

For ACL tears, the sensitivity, specificity, positive predictive value, negative predictive value and accuracy of clinical examination were 94.7%, 71.4%, 90.0%, 83.3% and 88.5%, respectively with respect to arthroscopy. Sensitivity, accuracy and negative predictive value were similar to other studies, whereas we had a lower specificity as compared to other studies (4-8).

Previous literature reports a sensitivity of 66% - 100% (5, 6, 9-15), specificity of 67% - 98% (6, 9-15), positive predictive value of 75% - 81% (10), negative predictive value of 79% - 100% (6, 10, 15) and accuracy of 78% - 98% (7, 8, 10-17) for the ACL tears in MRI against arthroscopy. Whereas we found them to be 94.7%, 78.6%, 92.3%, 84.6% and 90.4%, respectively, a picture similar to the other studies apart from the positive predictive value which was higher.

For PCL tears, whereas there is a lack of reported data comparing the sensitivity, specificity, positive predictive

value and negative predictive value of clinical examination with arthroscopy; a few studies report accuracy rates of 90% (14) and 100% (8), we found them to be 100% for all the variables.

Sensitivity, specificity, positive predictive value, negative predictive value and accuracy of MRI for PCL tears were 80%, 97.9%, 80%, 97.9% and 96.2%, respectively with respect to arthroscopy. In other established studies sensitivity ranged from 80% - 100% (10, 12), specificity ranged from 95% - 100% (10, 12), positive predictive value is reported at 50% (10), negative predictive values reported 100% (10, 12) and accuracy ranged from 94% - 99% (8, 10, 16).

The results of the current study were quite comparable with those of the previous studies regarding cruciate ligaments injuries. Clinical examination as well as MRI was both equally sensitive in diagnosing ACL tears but MRI was more specific than clinical examination. In diagnosing PCL tears clinical examination had an upper hand with sensitivity 100% as compared to 80% for MRI similar to the study concluded by Esmailijah AA et al. (8).

Specificity of clinical examination for ACL tears was less compared to MRI due to the more number of false-positive cases. Out of the 8 false-positive cases, 4 cases were in the age group of 45 - 50 years. There might have been degenerative changes in the knee leading to false-positive results, as also advocated by Madhusudhan TR et al. (18). In 4 cases of ACL tears we missed the clinical diagnosis, out of these 4 cases 2 cases were of partial tears and 2 cases were of chronic ACL tear. In cases with chronic ACL tear, we found arthroscopically anterior cruciate stumps fibrosis attachment with posterior cruciate ligament that might be giving pseudo firm end point on anterior drawer and Lachmann tests clinically. In the current study, 4 cases of ACL tears were missed on MRI. On MRI, partial tears of ACL may be missed due to the overlying synovial reactions, which have been also suggested by Stanitski CL (19). For ACL and PCL tears, in mass screening and outpatient department basis, clinical examination by experienced hands may be a better or similar tool as compared to MRI (7, 14, 16, 20).

In our study for medial meniscus tears, sensitivity, specificity, positive predictive value, negative predictive value and accuracy of clinical examination with respect to arthroscopy were 76.5%, 68.6%, 54.2%, 85.7% and 71.2%, respectively quite similar to the studies (21, 22), whereas other studies report a sensitivity of 86% - 96% (4, 21, 23), specificity of 33% - 87% (4, 21, 22), accuracy of 73% - 96% (4, 7, 8, 22, 23) whereas data for positive predictive value and negative predictive value are limited with 95% and 90%, respectively (23). Sensitivity, specificity, positive predictive value, negative predictive value and accuracy of MRI with respect to arthroscopy were 88.2%, 62.8%, 53.6%, 91.7% and 71.2%, respectively similar to studies by (21, 24). These values were

near to 90% in the studies (12, 13, 22). In other published studies, sensitivity ranged from 50% - 100% (9, 10, 12, 13, 21-25), specificity ranged from 44% - 100% (9, 10, 12, 13, 21-25), positive predictive value ranged from 71%-90% (10, 15, 24, 25), Negative predictive value ranged from 86% - 100% (10, 23, 24) and accuracy ranged from 66% - 98% (7, 8, 10, 12, 13, 16, 22, 23).

For lateral meniscus tears, sensitivity, specificity, positive predictive value, negative predictive value and accuracy of clinical examination with respect to arthroscopy were 40%, 94.6%, 75.0%, 79.6% and 78.8%, respectively similar to the study (22), whereas in previous published literature, sensitivity ranged from 38% - 81% (4, 22), specificity varied from 93% - 96% (4, 22), accuracy ranged from 76% - 90% (4, 7, 8, 22) whereas data for positive predictive value and negative predictive value are lacking.

Unlike the findings of the study (13, 22), in our study sensitivity, specificity, positive predictive value, negative predictive value and accuracy of MRI with respect to arthroscopy were 46.7%, 89.2%, 63.6%, 80.5% and 76.9%, respectively, which have been comparable to studies (12, 25). In previous published literature, sensitivity ranged from 40% - 96% (9, 10, 12, 13, 15, 22, 24, 25), specificity varied from 73% - 98% (9-15, 22, 24, 25), positive predictive values ranged from 33% - 81% (10, 24, 25), negative predictive values ranged from 91% - 93% (10, 25) and the accuracy ranged from 69% - 97% (7, 8, 10, 12, 13, 16, 22).

Clinical examination is a time-tested modality, which is specific and independent of involvement of other intra-articular structures. The Lachmann test is a more sensitive and specific clinical test for anterior cruciate ligament tear. Anterior and posterior drawer tests (26) have high specificity and sensitivity for the cruciate ligaments and can be performed in any patient.

The Lachmann test can be performed in acute scenario as well. The McMurray test (27) and Apley grinding-distraction tests (28) can only be performed after interval of 3 weeks and are contraindicated in acute scenarios. Joint line tenderness (20) is a sensitive but a nonspecific clinical sign, it has a low specificity hence cannot be used as a guide to establish a diagnosis but can be a supportive tool. The results of clinical examination and accuracy are better in an experienced and trained hand.

Over-diagnosis of meniscal tears on MRI may also be attributed to meniscal degeneration and more common presentation. Although MRI shares a high sensitivity for meniscal tears, it is an expensive tool with high inter-observer variations and false-positive results even in asymptomatic and clinically normal patients. However, MRI may be helpful in cases where clinical examination fails to establish a diagnosis or in instances where the examination cannot be performed, in all instances MRI

should serve as a supplementary tool to either clinical examination or arthroscopy in the diagnosis establishment.

One of the limitations of the current study was lack of inter and intra-observer reliability testing and small population of the study group, and large randomized controlled trial needed.

A detailed history with a carefully performed clinical examination is the first step towards patient management, which inexperienced hands may justify arthroscopy on clinical grounds alone. Depending on the clinical examination, the surgeon may decide the need for MRI examination.

Acknowledgments

We would like to thank all the patients involved in the study.

Footnote

Authors' Contribution: All the authors were involved in patient management, study design and manuscript preparation.

References

- Campbell. Campbell's Operative Orthopaedics. 12 ed. Elsevier; 2013. p. 2053.
- Frobell RB, Lohmander LS, Roos HP. Acute rotational trauma to the knee: poor agreement between clinical assessment and magnetic resonance imaging findings. *Scand J Med Sci Sports*. 2007;**17**(2):109-14. doi: [10.1111/j.1600-0838.2006.00559.x](https://doi.org/10.1111/j.1600-0838.2006.00559.x). [PubMed: [17394470](https://pubmed.ncbi.nlm.nih.gov/17394470/)].
- Gillquist J, Hagberg G, Oretorp N. Arthroscopic visualization of the posteromedial compartment of the knee joint. *Orthop Clin North Am*. 1979;**10**(3):545-7. [PubMed: [460830](https://pubmed.ncbi.nlm.nih.gov/460830/)].
- Yoon YS, Rah JH, Park HJ. A prospective study of the accuracy of clinical examination evaluated by arthroscopy of the knee. *Int Ortho (SICOT)*. 1997;**22**:223-7. doi: [10.1007/s002640050155](https://doi.org/10.1007/s002640050155).
- Gupta K, Guleria M, Sandhu P, Galhotra R. Correlation of clinical, MRI and arthroscopic findings in diagnosing meniscus and ligament injuries at knee joint: A prospective study. *J Orthop Allied Sci*. 2013;**12**:6. doi: [10.4103/2319-2585.117379](https://doi.org/10.4103/2319-2585.117379).
- Kasturi A, Veeraji E, Arvind B, Jaiswal R. A Study on Clinical Evaluation, MRI & Arthroscopy in Cruciate Ligament & Meniscal Injuries. *J Evolution Med Dental Sci*. 2013;**2**(25):4536-41. doi: [10.14260/jemds/875](https://doi.org/10.14260/jemds/875).
- Rose NE, Gold SM. A comparison of accuracy between clinical examination and magnetic resonance imaging in the diagnosis of meniscal and anterior cruciate ligament tears. *Arthroscopy*. 1996;**12**:398-405. doi: [10.1016/S0749-8063\(96\)90032-8](https://doi.org/10.1016/S0749-8063(96)90032-8).
- Esmailjiah AA, Keyhani S, Zerai R, Moghaddam AK. Accuracy of MRI in comparison with clinical and arthroscopic findings in ligamentous and meniscal injuries of the knee. *Acta Orthop Belg*. 2005;**71**:189-96.
- Munshi M, Davidson M, MacDonald PB, Froese W, Sutherland K. The efficacy of magnetic resonance imaging in acute knee injuries. *Clin J Sport Med*. 2000;**10**(1):34-9. [PubMed: [10695848](https://pubmed.ncbi.nlm.nih.gov/10695848/)].
- Khanda GE, Akhtar W, Ahsan H, Ahmad N. Assessment of menisci and ligamentous injuries of the knee on magnetic resonance imaging: correlation with arthroscopy. *J Pak Med Assoc*. 2008;**58**(10):537-40. [PubMed: [18998304](https://pubmed.ncbi.nlm.nih.gov/18998304/)].
- Ha TP, Li KC, Beaulieu CF, Bergman G, Ch'en IY, Eller DJ, et al. Anterior cruciate ligament injury: fast spin-echo MR imaging with arthroscopic correlation in 217 examinations. *AJR Am J Roentgenol*. 1998;**170**(5):1215-9. doi: [10.2214/ajr.170.5.9574587](https://doi.org/10.2214/ajr.170.5.9574587). [PubMed: [9574587](https://pubmed.ncbi.nlm.nih.gov/9574587/)].
- Polly DW, Callaghan JJ, Sikes RA. The accuracy of selective magnetic resonance imaging compared with the findings of arthroscopy of the knee. *J Bone Joint Surg*. 1988;**70**:192-8.
- Boeree NR, Watkinson AF, Ackroyd CE, Johnson C. Magnetic resonance imaging of meniscal and cruciate injuries of the knee. *J Bone Joint Surg Br*. 1991;**73**(3):452-7. [PubMed: [1670448](https://pubmed.ncbi.nlm.nih.gov/1670448/)].
- Gupta S, Sharma R, Sachar A, Saini Y, Saini N. Comparison Of Clinical Examination, MRI And Arthroscopy In Knee Injuries. *Int J Orthop Surg*. 2012;**19**(3).
- Cellar R, Sokol D, Lacko M, Stofa S, Gharaibeh A, Vasko G. [Magnetic resonance imaging in the diagnosis of intra-articular lesions of the knee]. *Acta Chir Orthop Traumatol Cech*. 2012;**79**(3):249-54. [PubMed: [22840957](https://pubmed.ncbi.nlm.nih.gov/22840957/)].
- Fischer SP, Fox JM, Del Pizzo W, Friedman MJ, Snyder SJ, Ferkel RD. Accuracy of diagnoses from magnetic resonance imaging of the knee. A multi-center analysis of one thousand and fourteen patients. *J Bone Joint Surg Am*. 1991;**73**(1):2-10. [PubMed: [1985991](https://pubmed.ncbi.nlm.nih.gov/1985991/)].
- Mink JH, Levy T, Crues JV 3rd. Tears of the anterior cruciate ligament and menisci of the knee: MR imaging evaluation. *Radiology*. 1988;**167**(3):769-74. doi: [10.1148/radiology.167.3.3363138](https://doi.org/10.1148/radiology.167.3.3363138). [PubMed: [3363138](https://pubmed.ncbi.nlm.nih.gov/3363138/)].
- Madhusudhan TR, Kumar TM, Bastawrous SS, Sinha A. Clinical examination, MRI and arthroscopy in meniscal and ligamentous knee Injuries - a prospective study. *J Orthop Surg Res*. 2008;**3**:19. doi: [10.1186/1749-799X-3-19](https://doi.org/10.1186/1749-799X-3-19). [PubMed: [18489779](https://pubmed.ncbi.nlm.nih.gov/18489779/)].
- Stanitski CL. Correlation of arthroscopic and clinical examinations with magnetic resonance imaging findings of injured knees in children and adolescents. *Am J Sports Med*. 1998;**26**(1):2-6. [PubMed: [9474394](https://pubmed.ncbi.nlm.nih.gov/9474394/)].
- Kocabay Y, Tetik O, Isbell WM. The value of clinical examination versus magnetic resonance imaging in the diagnosis of meniscal tears and anterior cruciate ligament rupture. *J Arthroscopy*. 2004;**20**:696-700. doi: [10.1016/S0749-8063\(04\)00593-6](https://doi.org/10.1016/S0749-8063(04)00593-6).
- Rayan F, Bhonsle S, Shukla DD. Clinical, MRI, and arthroscopic correlation in meniscal and anterior cruciate ligament injuries. *Int Orthop*. 2009;**33**(1):129-32. doi: [10.1007/s00264-008-0520-4](https://doi.org/10.1007/s00264-008-0520-4). [PubMed: [18297284](https://pubmed.ncbi.nlm.nih.gov/18297284/)].
- Sharma UK, Shrestha BK, Rijal S, Bijukachhe B, Barakoti R, Banskota B, et al. Clinical, MRI and arthroscopic correlation in internal derangement of knee. *Kathmandu Univ Med J*. 2011;**35**(3):174-8.
- Ercin E, Kaya I, Sungur I, Demirbas E, Ugras AA, Cetinus EM. History, clinical findings, magnetic resonance imaging, and arthroscopic correlation in meniscal lesions. *Knee Surg Sports Traumatol Arthrosc*. 2012;**20**(5):851-6. doi: [10.1007/s00167-011-1636-4](https://doi.org/10.1007/s00167-011-1636-4). [PubMed: [21833511](https://pubmed.ncbi.nlm.nih.gov/21833511/)].
- Nikolaou VS, Chronopoulos E, Savvidou C, Plessas S, Giannoudis P, Efstathiopoulos N, et al. MRI efficacy in diagnosing internal lesions of the knee: aretrospective analysis. *J Trauma Manag Outcomes*. 2008;**2**(4):1-10. doi: [10.1186/1752-2897-2-4](https://doi.org/10.1186/1752-2897-2-4).
- Elvenes J, Jerome CP, Reikeras O, Johansen O. Magnetic resonance imaging as a screening procedure to avoid arthroscopy for meniscal tears. *Arch Orthop Trauma Surg*. 2000;**120**(1-2):14-6. [PubMed: [10653097](https://pubmed.ncbi.nlm.nih.gov/10653097/)].
- Benjaminse A, Gokeler A, van der Schans CP. Clinical diagnosis of an anterior cruciate ligament rupture: a meta-analysis. *J Orthop Sports Phys Ther*. 2006;**36**(5):267-88. doi: [10.2519/jospt.2006.2011](https://doi.org/10.2519/jospt.2006.2011). [PubMed: [16715828](https://pubmed.ncbi.nlm.nih.gov/16715828/)].
- McMurray TP. The semilunar cartilages. *Br J Surg*. 1949;**29**:407. doi: [10.1002/bjs.18002911612](https://doi.org/10.1002/bjs.18002911612).
- Strobel M, Stedtfeld HW. Diagnostik des Kniegelenkes. Berlin: Springer Verlag; 1990. pp. 166-80.