

Conservative Treatment of Complete Dislocation of the Thumb Metacarpal in a Hypermobile Patient

Deniz Aydın, Baris Polat

Department of Orthopedics and Traumatology, Near East University Medical Faculty, Nicosia, Cyprus, Turkey

Abstract

Simultaneous dislocation of the thumb carpometacarpal and metacarpophalangeal joints is an uncommon injury. Stability is the most important factor in the decision of treatment in these rare injuries. The treatment methods range from closed reduction and maintaining reduction with cast or percutaneous k-wires to complex reconstruction surgeries. In this paper, a case of 28-year-old female with complete dislocation of the left thumb metacarpal has been reported. She was treated with closed reduction and cast immobilization with excellent result. Treatment decision should be based on postreduction stability in complete dislocation of thumb metacarpal; cast immobilization is a management option in case of stable reduction.

Keywords: Dislocation, metacarpal, thumb

INTRODUCTION

Simultaneous dislocation of the carpometacarpal (CMC) and metacarpophalangeal (MCP) joints of the thumb is a rare injury.^[1-5] Axial loading of metacarpal is the main injury mechanism.^[6] In this paper, a 28-year-old female with hypermobile joints and simultaneous dislocation of CMC and MCP joints of the left thumb was treated with closed reduction and cast immobilization with the excellent result is reported.

CASE REPORT

A 28-year-old female was admitted to the emergency room with deformity and pain in her left hand. She fell on her hand with her thumb outstretched. Her thumb was shortened with a bony prominence on the thenar side of the hand at CMC joint and dorsal displacement of proximal phalanx over the metacarpal [Figure 1]. The neurovascular examination was normal. The patient had hypermobile joints with a Beighton score of 8/9.^[7] Uninjured fingers were in swan-neck position.

Radiographs of both hands were obtained. Radiographs showed dorsal displacement of MCP joint and dorsal displacement of CMC joint of the left thumb with no evidence of fracture [Figure 1].

Intra-articular local anesthetic was applied. First, MCP joint was reduced by pushing proximal phalanx volarly while applying gentle traction from distal phalanx. Then, the thumb was positioned in flexion for the reduction of CMC joint. Metacarpal base was pushed volarly while gentle traction was applied distally. Both joints were found stable after reduction. Concentric reduction of both joints was confirmed by control radiographs [Figure 2].

Radial based thumb spica splint was applied. She was followed in the outpatient clinic for 3 weeks with weekly control radiographs. On the 6th week, the splint was removed, and the thumb exercises were given. It was observed that the concentric reduction was preserved.

She was called for follow-up and evaluation on the 3rd, 6th, and 18th month. At the end of the 3rd and the 18th month, thumb range of motion was unlimited, and the grip strength of the left hand was full in comparison with the contralateral

Address for correspondence: Dr. Deniz Aydın,
Department of Orthopedics and Traumatology, Near East University Medical
Faculty, Lefkosa, Cyprus, Mersin 10, Turkey.
E-mail: deniz.aydin@neu.edu.tr

This is an open access journal, and articles are distributed under the terms of the Creative Commons Attribution-NonCommercial-ShareAlike 4.0 License, which allows others to remix, tweak, and build upon the work non-commercially, as long as appropriate credit is given and the new creations are licensed under the identical terms.

For reprints contact: reprints@medknow.com

How to cite this article: Aydın D, Polat B. Conservative treatment of complete dislocation of the thumb metacarpal in a hypermobile patient. Arch Trauma Res 2018;7:33-5.

Access this article online

Quick Response Code:



Website:
www.archtrauma.com

DOI:
10.4103/atr.atr_30_17

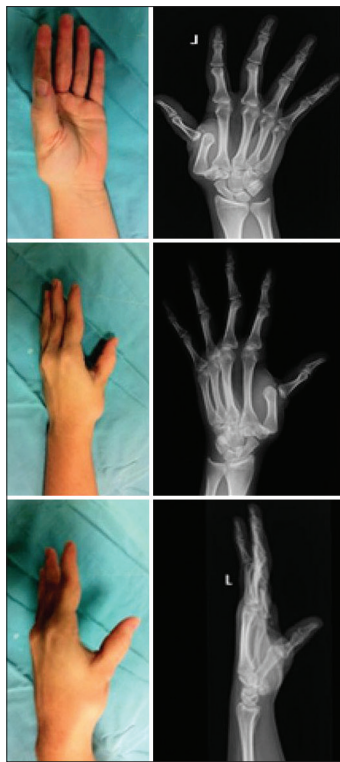

Figure 1: Prereduction pictures and radiographs of the left hand

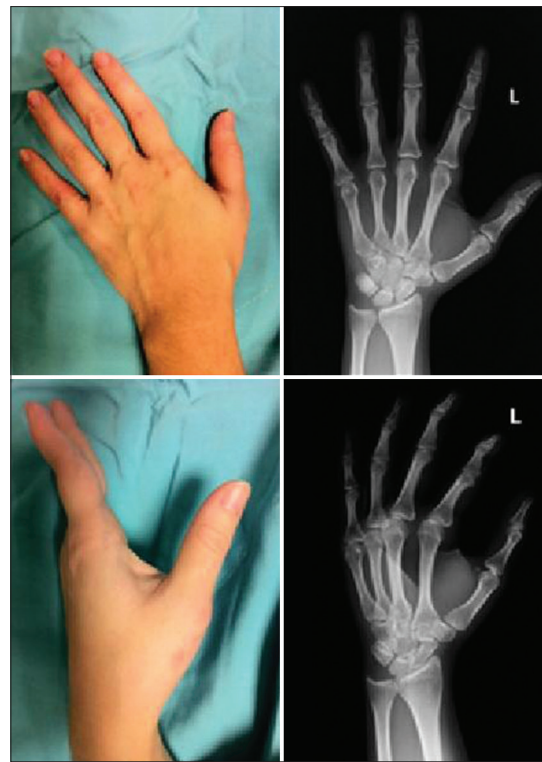


Figure 2: Postreduction pictures and radiographs of the left hand

side. In addition, the thumb-index span of both sides was equal at 16 cm. Her DASH (Disabilities of the arm, shoulder, and hand) score was 0. The last radiographs obtained at the 18th month of the trauma showed no evidence of subluxation or arthrosis [Figure 3].

The patient was informed that pictures, radiographs, and data from the case would be submitted for publication, and she gave her consent.

DISCUSSION

Complete dislocation of the thumb metacarpal is a very rare injury.^[1-5] Mechanism for dorsal dislocation of the CMC joint is axial loading when metacarpal is in slight flexion.^[4,8] Dorsal dislocation of the MCP joint occurs by forced hyperextension.^[4,8] In our case, the injury mechanism was similar, as the patient fell over her hand with an outstretched thumb. Axial loading of the thumb dislocated the CMC joint dorsally which caused flexion of the metacarpal. This resulted in hyperextension of the MCP joint, and the ongoing axial loading caused dorsal dislocation of this joint.

In these rare injuries, a common treatment method has not yet been established. Closed reduction and casting, closed or open reduction and pinning, and open reduction and ligamentous reconstruction are the treatment modalities.^[3,4] Operative treatment indications for CMC and MCP joint dislocations are instability after closed reduction, associated displaced fracture, severe ligamentous injury, inability to provide concentric reduction and associated open injuries.

There are few papers in the literature reporting conservative treatment of double dislocation of thumb metacarpal.^[5,9,10] Conservative treatment of the complete dislocation of the thumb metacarpal with satisfactory results was described by Shih *et al.* in 2006, Marcotte and Trzeciak in 2008, and Messaoudi *et al.* in 2015.^[5,9,10] In all these studies, closed reduction and 6 weeks of cast immobilization were applied, and good functional results were reported at 18th- to 24th-month follow-ups. Shih *et al.* described simultaneous dorsoradial dislocation of the CMC joint and dorsal dislocation of the MCP joint, both joints were found to be stable in clinical and fluoroscopic evaluation after reduction, treated conservatively with splint immobilization for 6 weeks. They explained good functional recovery but slight radial subluxation of the CMC joint at the end of the 18th month.^[9] Marcotte and Trzeciak described another simultaneous double dislocation of the thumb metacarpal with slight laxity of ulnar collateral ligament of the MCP joint and a stable CMC joint in the postreduction examination. The authors explained good results with no evidence of subluxation, instability, and arthritis in 2-year follow-up after conservative treatment.^[5] Messaoudi *et al.* treated another patient with simultaneous lateral dislocation of the CMC joint and dorsal dislocation of the MCP joint. They found that MCP joint was stable, and CMC joint had slight radial laxity in the postreduction evaluation. They reported excellent functional outcome following conservative treatment.^[10] In our case, both joints were stable in the postreduction evaluation. At the 18th month follow-up, excellent functional results with no evidence of instability or arthritis were found.

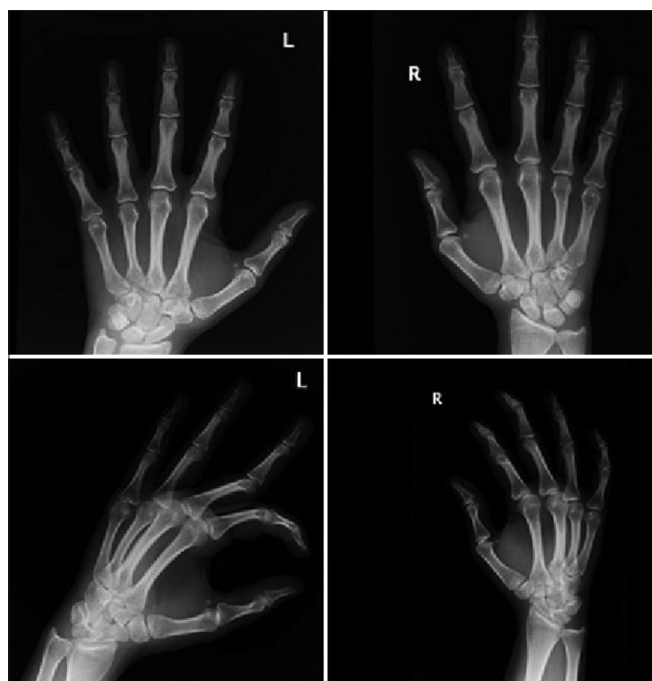

Figure 3: Radiographs of the left hand at 18th month

In hypermobile patients, close follow-up with repetitive radiograph controls is necessary for the conservative treatment of the floating thumb metacarpal. There is an increased risk of CMC joint redislocation in joint hypermobility syndrome.^[11] Recurrent dislocation of the CMC joint following double dislocation of thumb metacarpal in a patient with hyperlaxity was reported. The patient was treated with ligamentoplasty after CMC dislocation reoccurred twice. Suture and pinning or ligamentoplasty were advised as a first management in hypermobile patients.^[11] On the other hand, we should be aware of overtreatment in case of stable reduction. Postreduction stability of the joints should be the key point of treatment decision in pure dislocations of the thumb metacarpal.

Declaration of patient consent

The authors certify that they have obtained all appropriate

patient consent forms. In the form the patient(s) has/have given his/her/their consent for his/her/their images and other clinical information to be reported in the journal. The patients understand that their names and initials will not be published and due efforts will be made to conceal their identity, but anonymity cannot be guaranteed.

Financial support and sponsorship

Nil.

Conflicts of interest

There are no conflicts of interest.

REFERENCES

1. Moore JR, Webb CA Jr., Thompson RC. A complete dislocation of the thumb metacarpal. *J Hand Surg Am* 1978;3:547-9.
2. Ibrahim S, Noor MA. Simultaneous dislocations of the carpometacarpal and metacarpophalangeal joints of the thumb. *Injury* 1993;24:343-4.
3. Drosos GI, Kayias EH, Tsioros K. "Floating thumb metacarpal" or complete dislocation of the thumb metacarpal: A case report and review of the literature. *Injury* 2004;35:545-8.
4. Afshar AR, Mirzatoloei F, Abdi-Rad I. Concurrent dislocations of carpometacarpal and metacarpophalangeal joints of the thumb. *Arch Iran Med* 2005;8:221-2.
5. Marcotte AL, Trzeciak MA. Nonoperative treatment for a double dislocation of the thumb metacarpal: A case report. *Arch Orthop Trauma Surg* 2008;128:281-4.
6. Khan H, Darcy P, Magnussen P. Simultaneous volar dislocations of carpometacarpal and metacarpophalangeal joints of the thumb. *J Orthop Case Rep* 2012;2:8-11.
7. Beighton P, Horan F. Orthopaedic aspects of the Ehlers-Danlos syndrome. *J Bone Joint Surg Br* 1969;51:444-53.
8. Singh D, Krishna LG, Dhaka S, Kumar S, Arora S. Rare double fracture-dislocation of the thumb: A case report and review of the literature. *Chin J Traumatol* 2013;16:240-2.
9. Shih KS, Tsai WF, Wu CJ, Mudgal C. Simultaneous dislocation of the carpometacarpal and metacarpophalangeal joints of the thumb in a motorcyclist. *J Formos Med Assoc* 2006;105:670-3.
10. Messaoudi T, Errhaimini M, Ghoubach M, Chafik R, Madhar M, Elhaoury H, *et al.* Floating thumb metacarpal in a motorcyclist: A case report. *Chir Main* 2015;34:91-3.
11. Leiber-Wackenheim F, David E, Tran Van F, Havet E, Vernois J, Mertl P, *et al.* Floating first metacarpal with recurrent trapeziometacarpal dislocation in a subject with hyperlaxity. *Rev Chir Orthop Reparatrice Appar Mot* 2007;93:725-9.