

Chest Tube Malposition Inserted in Thorax Increases Morbidity at Thoracoabdominal Injury

Cem Donmez, Ahmet Korkut Belli, Sercan Subasi

Department of General and Emergency Surgery, Mugla Sitki Kocman University Hospital, Muğla, Turkey

ORCID:

Cem Donmez: <https://orcid.org/0000-0003-0822-6461>

Ahmet Korkut Belli: <https://orcid.org/0000-0003-1552-5697>

Sercan Subasi: <https://orcid.org/0000-0003-0822-6461>

Abstract

Thoracoabdominal penetrating trauma management is challenging when diaphragm injuries are involved. Thorax tube is golden standard for penetrating thoracoabdominal injuries. It has some complications. A 27-year-old male had stabbed thoracoabdominal penetrating trauma thorax tube inserted at another hospital. We decided to explore abdomen laparoscopy when he has symptoms at abdomen. We saw thorax tube ruptured diaphragm. We saturated diaphragm intracorporeally with laparoscopic protege. The clinician should not insert tube from penetrating trauma area. Tube must be inserted from its usual anatomical intercostal space.

Keywords: Chest tube, Diaphragm injury, thoracoabdominal

INTRODUCTION

Thoracoabdominal penetrating traumas have diaphragm injuries between 10% and 15%.^[1,2] Left-sided thoracoabdominal penetrating traumas have different management strategies, laparoscopy and thoracoscopy are now part of surgeon's diagnostic tool. Diagnosing even with the sophisticated devices is hard.

Common complications of tube thoracostomy are nonfunctioning or malpositioned chest tube, recurrent pneumothorax, and insertion site infection. Serious complications related to chest tube insertion are thoracoabdominal or thoracic injury, fistula formation, and vascular trauma.^[3]

At thoracoabdominal traumas, it is not recommended to insert the tube below the level of seventh intercostal space at left and sixth intercostal space at right in the thorax. In this case, we discussed inserting tube from the wound, where the penetrating trauma occurred.

CASE REPORT

A 27-year-old-man had been stabbed from the thorax at left eight intercostal levels and he had chest tube inserted at another

hospital 3 days ago. The patient had chest tube inserted from his wound. It was inserted below the left sixth intercostal space [Figure 1]. He was sent to our facility to the thoracic surgery. The patient has referred pain from the epigastrium to the left thoracoabdominal region. On examination, the patient was conscious and cooperated, Glasgow Coma Score: 15, blood pressure 110/70 mmHg, and heart pulse rate: 100/mn. There were no lung sounds in left. The tube had drained 400cc hemorrhagic fluid. The patient has epigastric tenderness and had no defense nor rebound in the abdomen. We made the laparoscopic diagnosis after 24 h for diaphragmatic injury. On laparoscopic exploration, there was a 4 cm diameter laceration in the left diaphragm [Figure 2]. The stomach fundus was herniated from the lacerated diaphragm. We reduced stomach fundus to the abdomen. There was a serosal injury at stomach fundus. The misplaced tube in thorax lacerated diaphragm muscles and pleura. Tube coursed horizontally and sided to the

Address for correspondence: Dr. Sercan Subasi,
Department of General Surgery, Mugla Sitki Kocman University Hospital,
Muğla, Turkey.
E-mail: ser274@hotmail.com

This is an open access journal, and articles are distributed under the terms of the Creative Commons Attribution-NonCommercial-ShareAlike 4.0 License, which allows others to remix, tweak, and build upon the work non-commercially, as long as appropriate credit is given and the new creations are licensed under the identical terms.

For reprints contact: reprints@medknow.com

How to cite this article: Donmez C, Belli AK, Subasi S. Chest tube malposition inserted in thorax increases morbidity at thoracoabdominal injury. Arch Trauma Res 2018;7:127-9.

Access this article online

Quick Response Code:



Website:
www.archtrauma.com

DOI:
10.4103/atr.atr_74_18

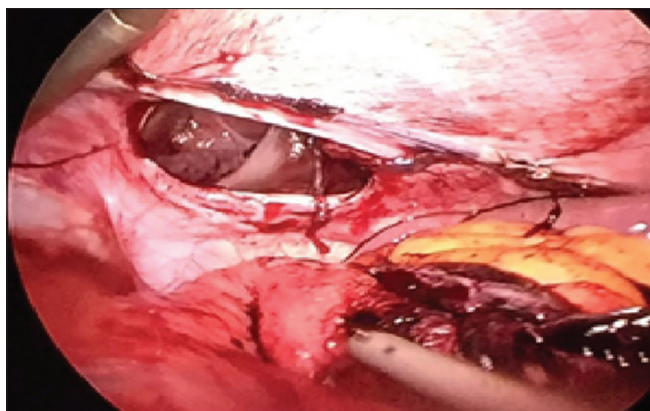


Figure 1: Diaphragm lesion whether from the tube or penetrating trauma

pericardium. Mislaced chest tube was taken out and bleeding at diaphragm was controlled. A new tube was inserted from the upper intercostal space. Diaphragmatic perforation and stomach serosa defect stitched intracorporeally.

DISCUSSION AND CONCLUSION

In a study, patients presenting thoracic trauma, required chest tube at 50%.^[4] Missed diagnosis of diaphragmatic injury could cause significant morbidity and mortality. Most of the patients with penetrating thoracoabdominal traumas have the history of gunshot and or stab wound to the abdomen or chest.^[5] The patient must be diagnosed for penetrating diaphragmatic injuries in case of stab wound between the nipple and umbilicus.^[6]

Left-sided diaphragmatic injuries present with herniation of organs such as stomach, intestines, liver, spleen, and omentum. A missed diagnosis can cause cardiopulmonary compromise, obstruction, strangulation even though perforation of the herniated organs in the hemithorax.

Acute diaphragmatic injuries should be diagnosed by exploratory laparotomy and in the case of delayed diaphragmatic injuries, it is the best way to treat and repair through a thoracotomy.^[7] Diagnostic laparoscopy and thoracoscopy are increasingly evaluated for diagnosis.

In the penetrating traumas between fourth and eighth intercostal spaces, the diaphragmatic traumas must be ruled out.^[8] Most of the traumatic penetrating traumas are left-sided because most suspects are right handed.

In cases which have suspected of hemothorax, chest tube should be inserted. Mehrotra *et al.* reported in a case that, diaphragmatic rupture was precipitated by chest tube.^[9] They blamed negative pressure created by the chest tube.

The British Thoracic Society defined the safe triangle, a line; it has borders superior to the horizontal level of the nipple, anterior border of the latissimus dorsi, the lateral border of the pectoralis major muscle, and an apex below the axilla.^[10] When a chest tube inserted below this area, there are some reports that chest tube ruptured diaphragm and placement to

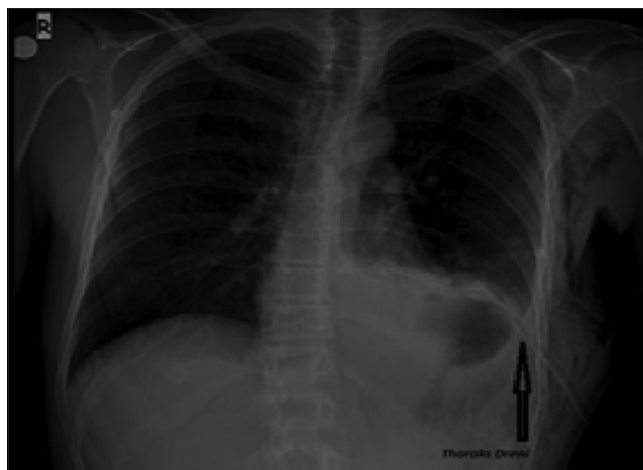

Figure 2: Mislaced tube in the thoracic cavity

the abdomen. Injuries to the stomach, liver, spleen have been reported.^[11] Perforation of the stomach that was herniated to the thorax is possible after chest tube insertion if there is iatrogenic diaphragmatic rupture.^[12]

In our case, misplaced chest tube was inserted from penetrating injury lesion at the eighth intercostal space level in another facility. It has disadvantages to insert tube from penetrating injury wound; first of all, below the level of left sixth intercostal space, it could make diaphragm and intra-abdominal organ damage.^[13,14] Second, the tube can move to lesion trace and could be misplaced. Third, the tube can contaminate thoracic cavity from lesion trace. Finally, possible criminal investigations cannot determine intrathoracic and intra-abdominal lesion was made from suspect or clinician.

At thoracoabdominal penetrating traumas, the clinician should insert the tube at its convenient position. Placing it from its unusual anatomical side can cause complication.

Financial support and sponsorship

Nil.

Conflicts of interest

There are no conflicts of interest.

REFERENCES

1. Asensio JA, Petrone P. Injury to the diaphragm. In: Moore EE, Feliciano DV, Mattox KL, editors. Trauma. 5th ed. NewYork: McGraw-Hill; 2004. p. 613-35.
2. Rosati C. Acute traumatic injury of the diaphragm. Chest Surg Clin N Am 1998;8:371-9.
3. Kwiatt M, Tarbox A, Seamon MJ, Swaroop M, Cipolla J, Allen C, *et al.* Thoracostomy tubes: A comprehensive review of complications and related topics. Int J Crit Illn Inj Sci 2014;4:143-55.
4. Chrysou K, Halat G, Hokscho B, Schmid RA, Kocher GJ. Lessons from a large trauma center: Impact of blunt chest trauma in polytrauma patients-still a relevant problem? Scand J Trauma Resusc Emerg Med 2017;25:42.
5. Chatzoulis G, Papachristos IC, Daliakopoulos SI, Chatzoulis K, Lampridis S, Svarnas G, *et al.* Septic shock with tension fecothorax as a delayed presentation of a gunshot diaphragmatic rupture. J Thorac Dis 2013;5:E195-8.
6. Scharff JR, Naunheim KS. Traumatic diaphragmatic injuries. Thorac

- Surg Clin 2007;17:81-5.
7. Thiam O, Konate I, Gueye ML, Toure AO, Seck M, Cisse M, *et al.* Traumatic diaphragmatic injuries: Epidemiological, diagnostic and therapeutic aspects. Springerplus 2016;5:1614.
 8. Meteroglu F, Sahin A, Basyigit I. Diaphragmatic injury: Condition be noticed in the management of thoracic trauma. Ulus Travma Acil Cerrahi Derg 2015;21:514-9.
 9. Mehrotra AK, Feroz A, Dawar S, Kumar P, Singh A, Khublani TK, *et al.* Diaphragmatic rupture precipitated by intercostal chest tube drainage in a patient of blunt thoraco-abdominal trauma. Lung India 2016;33:85-7.
 10. Laws D, Neville E, Duffy J; Pleural Diseases Group, Standards of Care Committee, British Thoracic Society. BTS guidelines for the insertion of a chest drain. Thorax 2003;58 Suppl 2:ii53-9.
 11. Millikan JS, Moore EE, Steiner E, Aragon GE, Van Way CW 3rd. Complications of tube thoracostomy for acute trauma. Am J Surg 1980;140:738-41.
 12. İçöz G, Kara E, Ilkgül O, Yetgin S, Tunçyürek P, Korkut MA, *et al.* Perforation of the stomach due to chest tube complication in a patient with iatrogenic diaphragmatic rupture. Acta Chir Belg 2003;103:423-4.
 13. Bowness JS, Nicholls K, Kilgour PM, Ferris J, Whiten S, Parkin I, *et al.* Finding the fifth intercostal space for chest drain insertion: Guidelines and ultrasound. Emerg Med J 2015;32:951-4.
 14. Bowness J, Kilgour PM, Whiten S, Parkin I, Mooney J, Driscoll P. Guidelines for chest drain insertion may not prevent damage to abdominal viscera. Emerg Med J 2015;32:620-5.

