

Diagnostic Value of Serial Ultrasound in Blunt Abdominal Trauma

Abdolhossein Davoodabadi,¹ Faramarz Marzban,¹ Leila Ghafoor,¹ Hamid Reza Talari,³ Esmail

Abdolrahim-Kashi,¹ Hossein Akbari,^{2,*} and Mehrdad Mahdian²

¹Department of Surgery, Kashan University of Medical Sciences, Kashan, IR Iran

²Trauma Research Center, Kashan University of Medical Sciences, Kashan, IR Iran

³Department of Radiology, Kashan University of Medical Sciences, Kashan, IR Iran

*Corresponding author: Hossein Akbari, Trauma Research Center, Kashan University of Medical Sciences, Qutb-e Ravandi Blvd. Postcode: 8715988141, Kashan, IR Iran. Tel: +98-9131638113, Fax: +98-36155575057, E-mail: akbari1350_h@yahoo.com

Received 2016 November 21; Accepted 2017 May 15.

Abstract

Background: Ultrasound has widely been used to assess patients with blunt abdominal trauma and detect free fluid in the abdomen. Nevertheless, different studies reported different false negative for this imaging technique.

Objectives: The present study was conducted to evaluate the diagnostic value of the repetitive ultrasound in diagnosis of free intraperitoneal fluid.

Methods: In this study, 125 patients with abdominal blunt trauma were recruited prospectively for ultrasound evaluation. Ultrasound and CT-scan were performed for all recruited patients in the study. In case of positive ultrasound or CT-scan (free fluid in the peritoneal cavity), patients underwent surgical operation. In the presence of negative ultrasound and CT-scan, and if the patient was alert and had stable vital signs, then, he/she would undergo exact supervision. In such patients, ultrasound and CT-scan were repeated 12 and 24 hours after admission. If any of the tests were positive, the patient underwent laparotomy. Moreover, if ultrasound and CT-scan examinations were negative 24 hours after admission, the patients with normal laboratory tests were discharged according to the surgeon's decision. Sensitivity, specificity, positive predictive value (PPV), and negative predictive value (NPV) were calculated.

Results: Of the 125 patients with abdominal blunt trauma, 90 patients finally underwent laparotomy. Based on the surgical outcome as the gold standard, the initial, 12 hours, and 24 hours sensitivity were measured to be 19.8%, 75.2%, and 82.2%, respectively. These numbers for specificity were 91.7, 75, and 70.8, respectively; they were 90.9, 92.6, and 92.2 for PPV, and 21.3, 41.8, and 48.5 for NPV, respectively.

Conclusions: The sensitivity of ultrasound to detect intraperitoneal fluid in blunt abdominal trauma cases will be increased by repeated ultrasound examinations.

Keywords: Abdominal Injuries, Ultrasonography, Hemoperitoneum

1. Background

Blunt abdominal trauma (BAT) accounts for about 80% of abdominal injuries seen in patients referred to the emergency departments (1). Although management of abdominal penetrating trauma is largely determined clinically, the diagnosis of BAT by physical examination is unreliable, especially in unconscious cases (2). On the other hand, early diagnosis of injuries is essential and late diagnosis and overlooked injuries are associated with poor outcome (3). Some procedures like diagnostic peritoneal lavage (DPL), computerized tomography scan, (CT-scan), abdominal ultrasonography, and laparoscopy have been used for abdominal assessment in patients with blunt injury (4-6). Despite the very high sensitivity (96%), DPL is an invasive procedure with the incidence of 1% to 9% possible complications of trauma to the bladder, bowel, and large vessels (7). Also, its low specificity may lead to unnecessary surgery

in 39% of cases (8). Diagnostic laparoscopy has had good sensitivity and specificity (94% and 98%, respectively) for predicting the need for laparotomy, however, this procedure is either invasive and time consuming or costly (9). The need for non-invasive, cost-effective, and accurate procedures has increased the tendency to use imaging techniques for evaluating patients with BAT. Although a CT-scan is the gold standard in abdominal assessment in BAT, some limitations such as x-ray exposure, high costs, possibility of renal poisoning in case of using contrast media, artifact due to patient movement, and need for patient transportation have led to reduced use of CT-scan in such patients (10, 11). Alternatively, many studies have shown that ultrasound can be replaced by DPL or CT-scan (12, 13); however, there are some evidences that show relying on ultrasound as the only means of assessing BAT victims instead of DPL or CT scan may lead to misdiagnosis (14, 15). So far, however, there has been little discussion about the increasing

accuracy of repeated or serial ultrasound in the evaluation of BAT (14, 16). Therefore, considering the limited studies and controversies about the value of repeated ultrasonography in early diagnosis of abdominal injuries in the patients sustaining BAT (17), this study was designed to evaluate the role of repeated ultrasound as a screening method for evaluating the need for operative intervention in such patients.

2. Objectives

The present study was designed to evaluate the diagnostic value of the repetitive ultrasound in the diagnosis of free intraperitoneal fluid in patients with BAT.

3. Methods

This was a prospective study on the diagnostic value of serial ultrasound in blunt abdominal trauma conducted at Kashan Shahid Beheshti hospital over a period of 12 months, from March 21, 2015 to March 21, 2016. Ethical approval was obtained from the deputy of research of Kashan University of Medical Sciences. Written informed consent was obtained from the patients and in cases that patients were unable to give consent, it was obtained from their relatives. The study included all patients aged 16 years and older who admitted to the Shahid Beheshti hospital during the study period with clinical manifestations of BAT due to different mechanisms including motor vehicle accidents and falling (from more than 20 feet height). Patients without consent, those whose FAST (focused assessment with sonography in trauma) was equivocal or difficult to interpret, patients with penetrating trauma or peritonitis, with gross hematuria, unstable vital signs, loss of consciousness, or those with pelvic fracture were excluded from the study. Routine resuscitation and treatment were performed for the all patients. Chest and pelvic x-ray and also FAST and CT-scan were performed for all recruited patients in the study. In case of positive FAST or CT-scan (free fluid in the peritoneal cavity), patients underwent surgical operation. In the presence of negative FAST and CT-scan examinations, and if the patient was alert and had stable vital signs, and if the x-ray of the chest (CXR) and pelvis (PXR) was normal and there was no noticeable bleeding in the urine and no signs of peritonitis, the patients underwent exact supervision. In such patients, ultrasonography and CT-scan were repeated 12 and 24 hours after admission using a Medison v20 11 MHz linear transducer (Samsung, Korea). All ultrasound and CT-scan examinations were performed by an experienced radiologist in the field of trauma. Ultrasonography was considered positive

when the liquid was seen in one of the 5 intraperitoneal spaces. If abdominal ultrasound or CT-scan showed fluid or blood 12 and 24 hours after patients' admission, then they were considered as positive and underwent surgical operation. If ultrasound and CT-scan examinations were negative 24 hours after admission, the patients with normal laboratory test and normal abdominal examination results were discharged based on the surgeon's decision (Figure 1). Phone follow-up was performed for all patients within 72 hours of discharge to reduce false negative cases. Finally, the results from ultrasounds were compared with the surgical and CT-scan results as the gold standard to determine specificity and sensitivity of FAST in BAT patients. Patients were categorized as true positives (TP) including cases with positive FAST and positive CT-scan or hemoperitoneum after operation; false positives (FP), or cases with positive FAST but negative CT-scan, or no hemoperitoneum after laparotomy; false negatives (FN), or those with negative FAST but with positive CT-scan, or hemoperitoneum after operation (because of deterioration of their condition); and finally true negatives (TN), or those who had negative FAST and negative CT-scan or those who were discharged from the hospital with good condition without any clinical manifestations during the first 72 hours after discharge from the hospital. Sensitivity, specificity, positive predictive value, and negative predictive value of FAST as a diagnostic approach were calculated.

4. Results

A total of 125 BAT patients [86 males (68.8%)] were included in the study. The mean (SD) age of the patients was 28.11 (25.8). Road traffic accident was the common mode of injury [103 (82.4%)] and in 22 patients (17.6%), injury was caused by falling from a height. False negative ultrasound was found in 2 cases (8.3%), while true positive was found in 20 (19.8%) at admission time ($P = 0.242$). In 12 and 24 hours after admission and ultrasound exams, true positives increased more significantly compared to false negatives (Table 1).

Based on the results presented in Table 1, diagnostic values for serial ultrasound were calculated. Although the sensitivity of ultrasound at admission was only 19.8%, the positive predictive value of the test was 90.9%, showing that cases with positive ultrasound at admission will have a positive laparotomy in more than 90% (Table 2). However, in patients with negative ultrasound at admission time, the result of laparotomy was negative in 21.3%. In other words, the positive ultrasound at admission is highly important to find hemoperitoneum cases. High sensitivity, positive, and negative predictive value will be achieved if

Table 1. Frequency of Serial Ultrasound Versus Surgical Operation Results Leading Diagnosis

Screening Results		Surgical Operation		P Value
		Negative	Positive	
Ultrasound at Admission	Negative	22 (91.7)	81 (80.2)	0.242
	Positive	2 (8.3)	20 (19.8)	
12 h Ultrasound	Negative	18 (75)	25 (24.8)	< 0.001
	Positive	6 (25)	76 (75.2)	
24 h Ultrasound	Negative	17 (70.8)	18 (17.8)	< 0.001
	Positive	7 (29.2)	83 (82.2)	

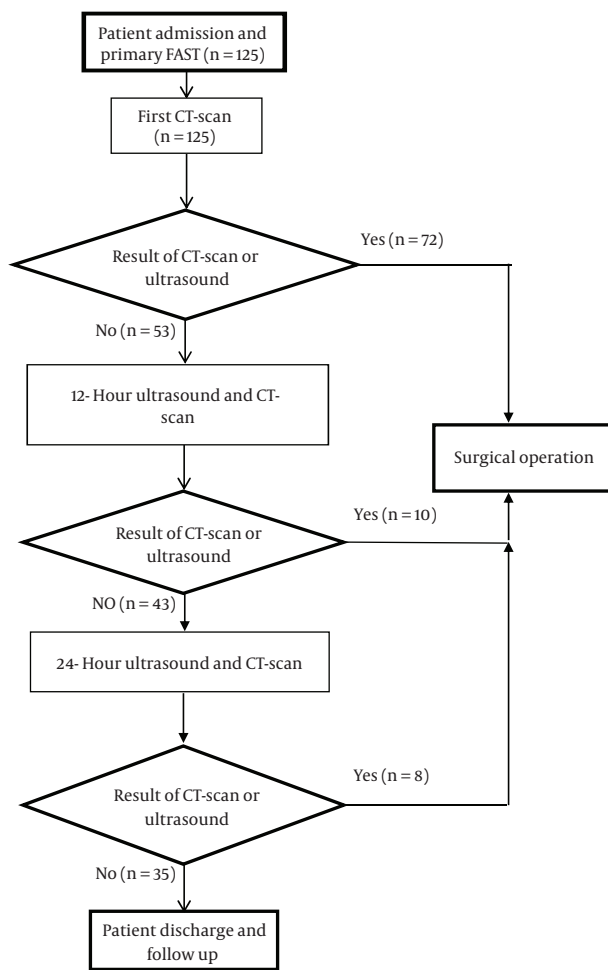


Figure 1. Diagram of Study Approach in Blunt Abdominal Trauma Patients

ultrasound is performed at 12 and 24 hours after admission, showing that the diagnostic power of the ultrasound will be increased by 2 and 3 folds compared with the admis-

sion time (Table 2).

Also, in this study diagnostic value of serial ultrasound, as the gold standard, was considered compared to CT-scan. Sensitivity and specificity were 30.6% and 100%, respectively at arrival time, while positive and negative predictive value of the test were 100% and 51.4%, respectively. In 12 and 24 hours ultrasound after admission, sensitivity increased to 81.9% and 88.9%, respectively. However, in these times the specificity was decreased. These results revealed that patients with positive ultrasound at arrival have a positive CT only in 51.4% of the cases, while those with negative ultrasound at arrival time have 100% negative CT-scan. In addition, prolonged hospitalization resulted in an increase in sensitivity and negative predictive value, but a decrease in specificity and positive predictive value (Table 3).

5. Discussion

The present study found that primary ultrasound at admission time has a high positive predictive value to diagnose intraperitoneal fluid in BAT cases and its diagnostic value will be increased if it is repeated 12 and 24 hours after admission. BAT is a serious diagnostic and management challenge for the trauma care team, especially surgeons due to its inherent nature that requires rapid, accurate, and efficient treatment. Delayed diagnosis may cause significant morbidity and mortality, thus, early diagnosis and appropriate intervention can improve outcomes (18). As a rapid, easy to perform, reliable, repeatable, safe, less expensive and cost effective tool, ultrasound can be an optimal screening test for BAT cases, especially in hemodynamically unstable patients in emergency departments (3). Several investigations have been done on the diagnostic value of ultrasound in BAT patients (6, 7, 19-21). However, different studies have reported different results on the potency of ultrasound to show free intraperitoneal fluid. The findings of the current study, to some extent, are consistent with those of Blackbourne et al. (2004), who found that the

Table 2. Sensitivity, Specificity and Predictive Value of the Test

	Sensitivity	Specificity	PPV	NPV
Ultrasound at Admission	19.8	91.7	90.9	21.3
12 h ultrasound	75.2	75	92.6	41.8
24 h ultrasound	82.2	70.8	92.2	48.5

Table 3. Sensitivity, Specificity and Predictive Values of Ultrasound compared to CT-Scan

Ultrasound Results		CT Scan Results		SEN	SP	PPV	NPV
		Negative	Positive				
Arrival Time	-	53	50	30.6	100	100	51.4
	+	0	22				
12 h after admission	-	30	13	81.9	56.6	71.9	69.8
	+	23	59				
24 h after admission	-	27	8	88.9	50.9	71.1	77.1
	+	26	64				

Abbreviations: CT, computed tomography; NPV, negative predictive value; PPV, positive predictive value; SEN, sensitivity; SP, specificity.

sensitivity of ultrasound will be increased by a secondary ultrasound to detect intra-abdominal injury. In their study, the sensitivity of the primary ultrasound in BAT cases has been increased from 31.1% to 72.1%, while the specificity of primary and secondary ultrasound was the same, 99.8% (22). Sensitivity of initial ultrasound based on the surgical operation in the current study was 19.8%, which reached to 75.2% for the second (12 hours after admission) and 82.2% for the third attempt (24 hours after admission). However, the specificity of the primary ultrasound in our study was high (91.7%), which gradually decreased in the second (75%) and third (70.8%) attempts. This rather contradictory result regarding specificity may be due to methodological difference between our study and Blackburn investigation.

Their study has been retrospective and the second ultrasound was performed during 30 minutes to 24 hours after an initial ultrasound, while we performed second and third ultrasounds exactly 12 and 24 hours after the initial one. The present findings are also in agreement with Rajabzadeh Kanafi et al. (2012) (16) and Feyzi et al. (2015) (23) findings that showed performing a secondary ultrasound increases the sensitivity of the test. Nevertheless, several studies have reported a high sensitivity (88.2% - 94.44%) for ultrasound in the first attempt (11, 18, 24). Although the results of the mentioned studies differ from ours in sensitivity, they are mainly consistent with our findings in specificity. Moreover, in almost all the above studies and some others (23, 25), positive predictive value was more than 90%, which is consistent with our finding in the present

study.

In conclusion, the evidence from this study suggests that although the initial ultrasound in BAT patients has low sensitivity, the sensitivity of the test will be increased through repeating. However, high positive predictive value of the ultrasound shows that more than 90% of patients with positive ultrasound will be undergoing laparotomy.

The results of the present study revealed that only slightly more than half of the cases with positive ultrasound have positive CT-scan at arrival time. However, those with negative ultrasound at admission have 100% negative CT, indicating that it can be possible to discharge patients with negative ultrasound, but it should be considered that half of the cases with positive ultrasound at arrival have positive CT.

Acknowledgments

This study was a part of residency dissertation supported by the deputy of research of Kashan University of Medical Sciences (grant no. 94121). The authors would like to thank all those who took part in this research.

References

1. Nishijima DK, Simel DL, Wisner DH, Holmes JF. Does this adult patient have a blunt intra-abdominal injury? *JAMA*. 2012;**307**(14):1517-27. doi: [10.1001/jama.2012.422](https://doi.org/10.1001/jama.2012.422). [PubMed: 22496266].

2. Isenhour JL, Marx J. Advances in abdominal trauma. *Emerg Med Clin North Am.* 2007;**25**(3):713-33. doi: [10.1016/j.emc.2007.06.002](https://doi.org/10.1016/j.emc.2007.06.002). [PubMed: [17826214](https://pubmed.ncbi.nlm.nih.gov/17826214/)] ix.
3. Jansen JO, Yule SR, Loudon MA. Investigation of blunt abdominal trauma. *BMJ.* 2008;**336**(7650):938-42. doi: [10.1136/bmj.39534.686192.80](https://doi.org/10.1136/bmj.39534.686192.80). [PubMed: [18436949](https://pubmed.ncbi.nlm.nih.gov/18436949/)].
4. Dittrich K, Abu-Zidan FM. Role of Ultrasound in Mass-Casualty Situations. *Int J Disaster Med.* 2009;**2**(1-2):18-23. doi: [10.1080/15031430410024813](https://doi.org/10.1080/15031430410024813).
5. Weishaupt D, Grozaj AM, Willmann JK, Roos JE, Hilfiker PR, Marincek B. Traumatic injuries: imaging of abdominal and pelvic injuries. *Eur Radiol.* 2002;**12**(6):1295-311. doi: [10.1007/s00330-002-1462-7](https://doi.org/10.1007/s00330-002-1462-7). [PubMed: [12042933](https://pubmed.ncbi.nlm.nih.gov/12042933/)].
6. Nnamonu MI, Ihezue CH, Sule AZ, Ramyil VM, Pam SD. Diagnostic value of abdominal ultrasonography in patients with blunt abdominal trauma. *Niger J Surg.* 2013;**19**(2):73-8. doi: [10.4103/1117-6806.119243](https://doi.org/10.4103/1117-6806.119243). [PubMed: [24497755](https://pubmed.ncbi.nlm.nih.gov/24497755/)].
7. Kornezos I, Chatziioannou A, Kokkonouzis I, Nebotakis P, Moschouris H, Yiarmenitis S, et al. Findings and limitations of focused ultrasound as a possible screening test in stable adult patients with blunt abdominal trauma: a Greek study. *Eur Radiol.* 2010;**20**(1):234-8. doi: [10.1007/s00330-009-1516-1](https://doi.org/10.1007/s00330-009-1516-1). [PubMed: [19662419](https://pubmed.ncbi.nlm.nih.gov/19662419/)].
8. McKenney KL. Ultrasound of blunt abdominal trauma. *Radiol Clin North Am.* 1999;**37**(5):879-93. [PubMed: [10494276](https://pubmed.ncbi.nlm.nih.gov/10494276/)].
9. Leppaniemi AK, Elliott DC. The role of laparoscopy in blunt abdominal trauma. *Ann Med.* 1996;**28**(6):483-9. [PubMed: [9017107](https://pubmed.ncbi.nlm.nih.gov/9017107/)].
10. Streck CJ, Jewett BM, Wahlquist AH, Gutierrez PS, Russell WS. Evaluation for intra-abdominal injury in children after blunt torso trauma: can we reduce unnecessary abdominal computed tomography by utilizing a clinical prediction model? *J Trauma Acute Care Surg.* 2012;**73**(2):371-6. doi: [10.1097/TA.0b013e31825840ab](https://doi.org/10.1097/TA.0b013e31825840ab). [PubMed: [22846942](https://pubmed.ncbi.nlm.nih.gov/22846942/)] discussion 376.
11. Nasr-Esfahani M, Kolahdouzan M, Shafiei M. Ultrasound surface probe as a screening method for evaluating the patients with blunt abdominal trauma. *J Res Med Sci.* 2014;**19**(1):23.
12. McKenney KL, Nunez DJ, McKenney MG, Asher J, Zelnick K, Shipshak D. Sonography as the primary screening technique for blunt abdominal trauma: experience with 899 patients. *AJR Am J Roentgenol.* 1998;**170**(4):979-85. doi: [10.2214/ajr.170.4.9580140](https://doi.org/10.2214/ajr.170.4.9580140). [PubMed: [9580140](https://pubmed.ncbi.nlm.nih.gov/9580140/)].
13. Yoshii H, Sato M, Yamamoto S, Motegi M, Okusawa S, Kitano M, et al. Usefulness and limitations of ultrasonography in the initial evaluation of blunt abdominal trauma. *J Trauma.* 1998;**45**(1):45-50. [PubMed: [9680011](https://pubmed.ncbi.nlm.nih.gov/9680011/)] discussion 50-1.
14. Mohammadi A, Ghasemi-Rad M. Evaluation of gastrointestinal injury in blunt abdominal trauma "FAST is not reliable": the role of repeated ultrasonography. *World J Emerg Surg.* 2012;**7**(1):2. doi: [10.1186/1749-7922-7-2](https://doi.org/10.1186/1749-7922-7-2). [PubMed: [22264345](https://pubmed.ncbi.nlm.nih.gov/22264345/)].
15. McGahan JP, Rose J, Coates TL, Wisner DH, Newberry P. Use of ultrasonography in the patient with acute abdominal trauma. *J Ultrasound Med.* 1997;**16**(10):653-62. [PubMed: [9323670](https://pubmed.ncbi.nlm.nih.gov/9323670/)] quiz 663-4.
16. Rajabzadeh Kanafi A, Giti M, Gharavi MH, Alizadeh A, Pourghorban R, Shekarchi B. Diagnostic accuracy of secondary ultrasound exam in blunt abdominal trauma. *Iran J Radiol.* 2014;**11**(3):ee21010. doi: [10.5812/iranjradiol.21010](https://doi.org/10.5812/iranjradiol.21010). [PubMed: [25763079](https://pubmed.ncbi.nlm.nih.gov/25763079/)].
17. Boutros SM, Nassef MA, Abdel-Ghany AF. Blunt abdominal trauma: The role of focused abdominal sonography in assessment of organ injury and reducing the need for CT. *Alexandria J Med.* 2016;**52**(1):35-41. doi: [10.1016/j.ajme.2015.02.001](https://doi.org/10.1016/j.ajme.2015.02.001).
18. Kumar S, Bansal VK, Muduly DK, Sharma P, Misra MC, Chumber S, et al. Accuracy of Focused Assessment with Sonography for Trauma (FAST) in Blunt Trauma Abdomen-A Prospective Study. *Indian J Surg.* 2015;**77**(Suppl 2):393-7. doi: [10.1007/s12262-013-0851-2](https://doi.org/10.1007/s12262-013-0851-2). [PubMed: [26730032](https://pubmed.ncbi.nlm.nih.gov/26730032/)].
19. Phul AH, Shah AA, Baloch I. Efficacy & Accuracy of Focused Assessment Sonography for Trauma (FAST) in Management of Isolated Gastrointestinal Injury due to Blunt Abdominal Trauma. *Pak J Med Res.* 2016;**55**(2):40A.
20. Helling TS, Wilson J, Augustosky K. The utility of focused abdominal ultrasound in blunt abdominal trauma: a reappraisal. *Am J Surg.* 2007;**194**(6):728-32. doi: [10.1016/j.amjsurg.2007.08.012](https://doi.org/10.1016/j.amjsurg.2007.08.012). [PubMed: [18005762](https://pubmed.ncbi.nlm.nih.gov/18005762/)] discussion 732-3.
21. Lee BC, Ormsby EL, McGahan JP, Melendres GM, Richards JR. The utility of sonography for the triage of blunt abdominal trauma patients to exploratory laparotomy. *AJR Am J Roentgenol.* 2007;**188**(2):415-21. doi: [10.2214/AJR.05.2100](https://doi.org/10.2214/AJR.05.2100). [PubMed: [17242250](https://pubmed.ncbi.nlm.nih.gov/17242250/)].
22. Blackbourne LH, Soffer D, McKenney M, Amortegui J, Schulman CI, Crookes B, et al. Secondary ultrasound examination increases the sensitivity of the FAST exam in blunt trauma. *J Trauma.* 2004;**57**(5):934-8. [PubMed: [15580013](https://pubmed.ncbi.nlm.nih.gov/15580013/)].
23. Feyzi A, Rad MP, Ahanchi N, Firoozabadi J. Diagnostic accuracy of ultrasonography in detection of blunt abdominal trauma and comparison of early and late ultrasonography 24 hours after trauma. *Pak J Med Sci.* 2015;**31**(4):980-3. doi: [10.12669/pjms.314.6614](https://doi.org/10.12669/pjms.314.6614). [PubMed: [26430442](https://pubmed.ncbi.nlm.nih.gov/26430442/)].
24. Healey MA, Simons RK, Winchell RJ, Gosink BB, Casola G, Steele JT, et al. A prospective evaluation of abdominal ultrasound in blunt trauma: is it useful? *J Trauma.* 1996;**40**(6):875-83. [PubMed: [8656472](https://pubmed.ncbi.nlm.nih.gov/8656472/)] discussion 883-5.
25. Fleming S, Bird R, Ratnasingham K, Sarker SJ, Walsh M, Patel B. Accuracy of FAST scan in blunt abdominal trauma in a major London trauma centre. *Int J Surg.* 2012;**10**(9):470-4. doi: [10.1016/j.ijsu.2012.05.011](https://doi.org/10.1016/j.ijsu.2012.05.011). [PubMed: [22659310](https://pubmed.ncbi.nlm.nih.gov/22659310/)].