



Fluoroscopic visualization of 4+5 extensor compartmental arteries in Kienböck's Disease

Tamer Coskun ^{1*}, Sertac Meydaneri ¹, Tolga Kurkcuoglu ¹

¹ Maltepe University Faculty of Medicine, Orthopedic Surgery Department, Istanbul, Turkiye

* **Corresponding author:** Tamer Coskun, Maltepe University Faculty of Medicine, Orthopedic Surgery Department, Istanbul, Turkiye

Email: drtamercoskun@gmail.com

Received: 2 February 2023 **Revised:** 9 April 2023 **Accepted:** 30 April 2023 **e-Published:** 30 June 2023

Abstract

Background: Many surgical treatment methods have been presented for Kienböck's disease. The most current treatment method is the surgical procedure with 4+5 extensor compartmental artery (ECA) bone graft. However, the graft harvest site is very close to the radioulnar and radiocarpal joints.

Objectives: This study aimed at determining the efficacy of intraoperative fluoroscopy evaluation of 4+5 ECA.

Methods: Intraoperative fluoroscopic visualization of the 4+5 ECA may facilitate the surgical procedure. Patients with lunate avascular necrosis at stage II-IIIa according to Lichtman classification who underwent 4+5 ECA bone graft were included in the study. A total of 13 patients (3 females, 10 males) participated in the study.

Results: The mean follow-up period of the patients was 15 months. In all patients, 4+5 ECA localizations were determined fluoroscopically. None of the patients experienced complications related to graft harvest.

Conclusion: Locating the intraoperative fluoroscopic 4+5 ECA may make the surgical procedure safer.

Keywords: Kienböck, 4+5 extensor compartmental artery, Fluoroscopic visualization.

Introduction

Lunate avascular necrosis, known as Kienböck's disease, causes a severe decrease in wrist function unless treated at an early stage. Many reasons have been revealed in the literature for the formation of this disease.^[1] Recurrent microtrauma, lunate morphology, ulnar variance, and lunate microvascular morphology have been included in the etiology of Kienböck's disease. Although there is no definite etiological cause, many treatment methods have been suggested. Treatment methods are generally selected according to the Lichtman classification. In the early stages, surgical treatments, such as radial shortening osteotomy, radial wedge osteotomy, capitate shortening osteotomy, and vascularized bone graft are applied. In advanced cases, salvage procedures such as carpal fusion, proximal row carpectomy, and wrist arthrodesis are performed. Despite the multitude of surgical treatment options applied to Kienböck's Disease, there is no gold standard treatment method. The 4+5 extensor

compartmental artery (ECA) bone graft provides a reliable alternative for the treatment of Kienböck's disease and may provide lunate revascularization.^[2]

The fourth extensor compartment artery lies next to the posterior interosseous nerve and at the base of the fourth extensor compartment. As it approaches the radiocarpal joint, many nutrients arteries penetrate the cancellous bone. The fifth extensor compartment artery lies below the fifth extensor compartment and anastomoses proximally with the fourth extensor compartment. While preparing the 4+5 ECA bone graft, the length of the pedicle and the place where the graft will be harvested is important. In our study, viewing the 4+5 ECA with intraoperative fluoroscopy for lunate avascular necrosis may provide a safer harvest of the vascularized bone graft.

Objectives

This study aimed at determining the efficacy of intraoperative fluoroscopy evaluation of 4+5 ECA.

Methods

Patients treated between 2019 and 2022 were included in the study. Patients with lunate avascular necrosis at stage II-IIIa according to Lichtman classification who underwent 4+5 ECA bone grafts were included in the study. Stage I, IIIB, and IV patients, who were treated with other surgical techniques, were excluded from the study. A total of 13 patients (3 females, 10 males) participated in the study. The mean age was 42.8 (range, 19-62). All patients had preoperative radiography and magnetic resonance imaging (MRI). As Figure 1 shown, 10 patients were diagnosed with stage II and 3 patients with stage IIIa. All patients had preoperative wrist pain and difficulty in daily activities. The dominant side was affected in 8 patients and the non-dominant side was affected in 5 patients. The patients had no history of trauma or surgery.

As a surgical technique, under general anesthesia, 4+5 ECA bone grafts and temporary scaphocapitate (SC) fixation were applied to all patients. The fourth and fifth ECA were determined [Figure 2]. The ray tech blue string removed from the surgical sponge was placed over the arteries [Figure 3]. The location of the 4+5 ECA in the dorsal radius was demonstrated by fluoroscopy (figure-4). With fluoroscopy, the radiocarpal joint and the distal radioulnar joint, and the safe place where the vascularized bone graft would be harvested were determined. The lunate necrotic bone was debrided. A corticocancellous bone graft with 4+5 ECA pedicles implanted into the hole opened on the lunate bone. Under the guidance of fluoroscopy, 1.2 mm K-wire is used for temporary SC fixation. The wrist was immobilized with a short arm splint for 6 weeks. K-wire was removed in Week 8. In the follow-ups, control was achieved with an X-ray.

Statistical analysis

In the descriptive statistics of the data, mean, standard deviation, median minimum, maximum, frequency, and ratio values were used. The distribution of variables was measured with the Kolmogorov-Smirnov test. Wilcoxon test was also used in the analysis of dependent quantitative data. SPSS 28.0 program (version 16.0, SPSS Inc, Chicago, IL, USA) was used in the analysis. A "P-value" less than 0.05 was considered significant.

Ethical considerations

The study was conducted in accordance with the Declaration of Helsinki. Hospital ethics committee approval was obtained. The present study did not interfere with the process of diagnosis and treatment of patients and all participants signed an informed consent form.

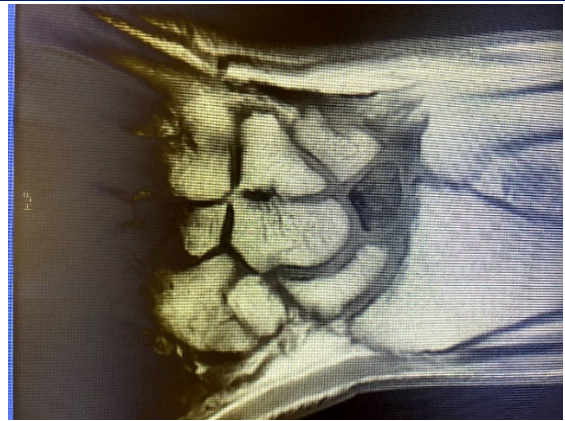


Figure-1. lunate avascular necrosis; a coronal MRI section

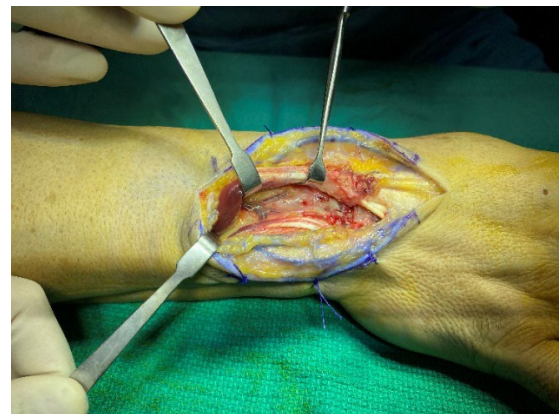


Figure 2. Intraoperative view of 4-5 ECA

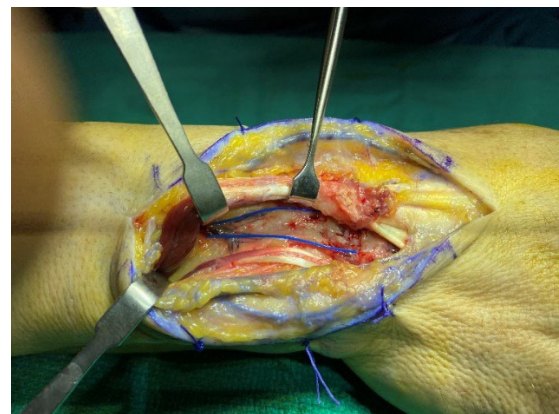


Figure 3. Placing ray tech blue strings on 4-5 ECA

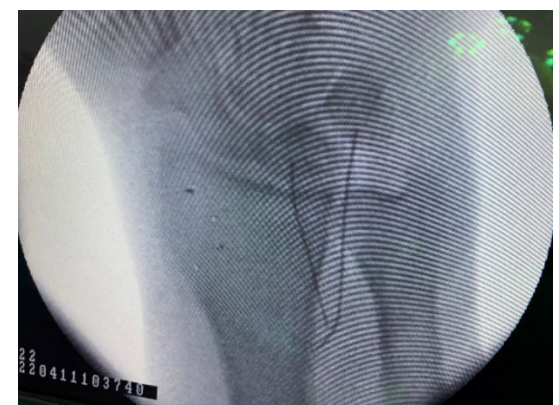

Figure 4. Fluoroscopic Visualization of 4-5 ECA

Results

The mean follow-up period of the patients was 15 months. During the follow-ups, the Lichtman stage of 2 patients changed and became stage-IIIB. Proximal row carpectomy (PRC) surgery was performed on these two

patients whose stages were changed [Table 1]. The preoperative Quickdash score of the patients decreased from 68.2 to 13.6 [Table 2]. Postop Quick DASH score decreased significantly ($p<0.05$) compared to the preoperative period.

Table-1. Demographic and clinical characteristics of patients

	Min-Max	Median	Mean±SD
Age (year)	19-62	46.0	42.8±13.6
Postoperative (month)	12-18	15.0	14.9±1.7
		N	Percent
Gender	Female	3	23.1%
	Male	10	76.9%
Side	Right	8	61.5%
	Left	5	38.5%
Stage	II	10	76.9%
	IIIA	3	23.1%
Secondary Surgery	No	11	84.6%
	PRC	2	15.4%

Table-2. Patients' Quick-DASH scores

Quick DASH	Min-Max	Median	Mean±SD	P value *
Preoperative	40.9-81.8	68.2	67.7±9.9	0.001
Postoperative	9.1-68.2	13.6	21.7±19.5	

* Wilcoxon test

Discussion

Kienböck's disease is a condition whose cause is unclear. It is a disease that usually presents with pain in the dominant wrist and is diagnosed with osteonecrosis of the lunate bone, one of the carpal bones, on radiographs. It is more commonly seen in the dominant wrist of men between the ages of 15 and 45 who work in heavy jobs. Symptoms usually appear 18 months before the radiological findings of the disease develop. Only magnetic resonance imaging can diagnose early avascular changes. Delay in treatment causes collapse and shortening of the lunate bone. Accordingly, secondary arthritic changes occur along the proximal carpal bones.^[3] The treatment plan for Kienböck's disease is determined according to the Lichtman classification. This classification was created by Lichtman based on wrist radiography and MRI.^[4] The purpose of this study was to evaluate the advantages of fluoroscopic visualization of 4-5 extensor compartmental arteries during surgery for the treatment of stage II-IIIA Kienböck's disease.

In stages II-III A, there are many different treatment options in the current literature. Joint leveling procedures (radius shortening and ulnar bone lengthening) can be

performed in patients with ulnar negative variance and wedge osteotomies of the radius bone can be performed in patients with ulnar neutral variance. Apart from these, core decompression of the distal radius bone, capitate bone shortening, and ulnar bone revascularization can also be performed.^[5]

The ulnar bone lengthening method, which is one of the joint leveling procedures, is a surgical method not very often used. In the conventional method, bone graft and plate are used. In addition, it is possible to apply ulnar lengthening with the distraction osteogenesis technique.^[6] However, there are complications such as graft site morbidity, implant removal, and nonunion. It is preferred more in shortening osteotomy of the radius bone because of the satisfactory results. After bone shortening, it is fixed with a compression plate. Not using bone grafts and having less risk of nonunion are advantages compared to ulnar lengthening.^[7] The capitate bone shortening method, which is another osteotomy method, as well as capitulum-hamatum fusion and carpometacarpal fusion have been used to reduce the load on the lunate bone.^[8] Wedge osteotomies of the radius bone can be performed in stage II-IIIA patients with Ulnar neutral variance. This

method is aimed to reduce the load on the lunate bone by reducing radioulnar inclination.^[9] There are also studies showing that wedge osteotomy increases lunate revascularization.^[10]

Metaphyseal core decompression in the distal radius bone is a relatively simple method that does not require advanced surgical techniques. It does not require invasion into the wrist joint or any internal fixation. It is a procedure that gives a chance to start active movements at the end of the second postoperative week. The basic principle of the procedure is to increase the local vascularity by hematoma and inflammation. Core decompression of the radius bone does not change the biomechanical load on the radiolunate fossa, but it exerts its effect on the increased vascularity around the lunate bone. Objective statistics cannot be reached because there is not much work on this technique apart from its developers.^[11,12]

Lunate bone revascularization procedure is preferred in our clinic. Studies have shown that pedicle graft transplanted into avascular bone stimulates new bone formation.^[13] The most preferred graft is 4+5 ECA bone graft in the distal radius.^[14] As a result of the technique, the success rate of revascularization in the lunate bone is quite high.^[15] The backward flow from the fifth ECA is directed ortho-gradely to the fourth ECA by ligation of the posterior branch of the anterior interosseous artery. The large diameter and length of the fifth ECA pedicle and the ulnar position of the pedicle on the wrist, which allows arthrotomy without damaging the vessels, provide a significant advantage. This surgical technique does not require extensive dissection and does not require cutting the palmar stabilizing radiocarpal ligaments. It is also easier to apply than other described vascularized graft techniques. It is especially the first choice in patients without ulnar negative variance. When this procedure is performed, it is necessary to reduce the pressure on the lunate bone to facilitate the revascularization process. After the vascularized graft is placed, the SC joint is temporarily fixed with a Kirschner wire to reduce the pressure on the lunate bone. The wire is removed after 8 weeks. In the long-term, excellent clinical results have been obtained in patients' mobility, grasping, and wrist pain.^[16]

Although multiple treatment options have been suggested for lunate avascular necrosis, there is no consensus on the gold standard treatment. The difficulty of constructing a set of treatment algorithms for Kienböck's disease is partly due to our incomplete understanding of the etiology of the disease. Avascular

necrosis of the lunate bone has been found to lead to lunate bone collapse followed by progression to radiocarpal and midcarpal arthritis. The treatment plan typically depends on the duration of the patient's symptoms, the Lichtman stage of the disease, and the surgeon's preference and experience. Vascularized bone graft procedures can be technically demanding and there is a learning curve associated with the procedure. Damage to the vessels during the exploration, harvest, or insertion of the pedicle can lead to devitalization of the graft. The fourth extensor compartment artery lies next to the posterior interosseous nerve and at the base of the fourth extensor compartment. As it approaches the radiocarpal joint, many nutrient arteries penetrate the cancellous bone. The fifth extensor compartment artery lies below the fifth extensor compartment and anastomoses proximally with the fourth extensor compartment. While preparing the 4+5 ECA bone graft, the length of the pedicle and the place where the graft will be harvested is important. The anatomical location of 4+5 ECAs is marked with intraoperative fluoroscopic images that we have applied. The ray tech blue string extracted from the surgical sponge is placed in proximal and distal parts of the 4th and 5th ECAs anatomical pathway. By marking their location in this way, the bone flap is lifted more safely. By determining the 4+5 ECAs location fluoroscopically, the harvest of the graft too close to the radiocarpal joint or radioulnar joint is prevented. There is a possibility of damage to the TFCC insertion site, one of the important stabilizers of the wrist, during graft removal. In addition, if the graft is taken too distally, there is a possibility of intraarticular cartilage damage. Determination of the graft location by intraoperative fluoroscopy eliminates these risks.

Conclusions

It can be concluded that 4-5 ECA bone grafts are one of the most current and frequent techniques used in Kienböck's disease. A much safer bone flap can be prepared with the method we recommend, when you are new to this surgical technique or when there is a doubt about the removal site of the intraoperative pedicle bone graft.

Acknowledgment

None.

Competing interests

The authors declare that they have no competing interests.

Abbreviations

4-5 extensor compartmental artery: ECA;
Magnetic resonance imaging: MRI;
Proximal row carpectomy: PRC;
Scaphocapitate: SC.

Authors' contributions

All authors read and approved the final manuscript. All authors take responsibility for the integrity of the data and the accuracy of the data analysis.

Funding

None.

Role of the funding source

None.

Availability of data and materials

The data used in this study are available from the corresponding author on request.

Ethics approval and consent to participate

The study was conducted in accordance with the Declaration of Helsinki. Institutional Review Board approval was obtained. All participants signed an informed consent form.

Consent for publication

By submitting this document, the authors declare their consent for the final accepted version of the manuscript to be considered for publication.

References

- Bain GI, MacLean SB, Yeo CJ, Perilli E, Lichtman DM. The Etiology and Pathogenesis of Kienböck Disease. *J Wrist Surg.* 2016; 5(4):248-254. doi: 10.1055/s-0036-1583755. Erratum in: *J Wrist Surg.* 2016;5(4):e1. PMID: 27777813; PMCID: PMC5074830.
- Chojnowski K, Opielka M, Piotrowicz M, Sobocki BK, Napora J, Dąbrowski F, Piotrowski M, Mazurek T. Recent Advances in Assessment and Treatment in Kienböck's Disease. *J Clin Med.* 2022;11(3):664. doi:10.3390/jcm11030664 PMID:35160115 PMCID:PMC8836398
- Camus EJ, Van Overstraeten L. Kienböck's disease in 2021. *Orthop Traumatol Surg Res.* 2022;108(1S):103161. doi:10.1016/j.otsr.2021.103161 PMID:34861414
- Ansari MT, Chouhan D, Gupta V, Jawed A. Kienböck's disease: Where do we stand? *J Clin Orthop Trauma.* 2020; 11 (4):606-613. doi:10.1016/j.jcot.2020.05.041 PMID:32684697 PMCID:PMC7355093
- Rioux-Forker D, Shin AY. Osteonecrosis of the Lunate: Kienböck Disease. *J Am Acad Orthop Surg.* 2020; 28 (14):570-584. doi:10.5435/JAAOS-D-20-00020 PMID:32692092
- Sundberg SB, Linscheid RL. Kienböck's disease. Results of treatment with ulnar lengthening. *Clin Orthop Relat Res.* 1984; (187):43-51. doi:10.1097/00003086-198407000-00007 PMID: 6744736
- van Leeuwen WF, Pong TM, Gottlieb RW, Deml C, Chen N, van der Heijden BEPA. Radial Shortening Osteotomy for Symptomatic Kienböck's Disease: Complications and Long-Term Patient-Reported Outcome. *J Wrist Surg.* 2021;10(1):17-22. doi: 10.1055/s-0040-1714750 PMID: 33552689; PMCID: PMC7850797
- Almquist EE. Capitate shortening in the treatment of Kienböck's disease. *Hand Clin.* 1993;9(3):505-12. doi:10.1016/S0749-0712(21)01271-3 PMID:8408261
- Shin YH, Kim J, Gong HS, Rhee SH, Cho MJ, Baek GH. Clinical Outcome of Lateral Wedge Osteotomy of the Radius in Advanced Stages of Kienböck's Disease. *Clin Orthop Surg.* 2017;9(3):355-362. doi:10.4055/cios.2017.9.3.355 PMID:28861204 PMCID:PMC5567032
- Lee JH, Kim J, Hwang JS, Baek GH. Improvement in lunate perfusion after radial closing-wedge osteotomy in patients with Kienböck's disease. *Hand Surg Rehab.* 2021;40(5):588-594. doi:10.1016/j.hansur.2021.06.005 PMID:34147670
- Illarramendi AA, De Carli P. Radius decompression for treatment of kienböck disease. *Tech Hand Up Extreme Surg.* 2003;7(3):110-3. doi:10.1097/00130911-200309000-00007 PMID:16518228
- Schulz CU. Metaphyseal Core Decompression of the Distal Radius for Early Lunate Necrosis. *J Hand Surg Asian Pac.* 2019;24(3):276-282. doi:10.1142/S2424835519500346 PMID:31438801
- Kirkeby L, von Varfalva Palffy L, Hansen TB. Long-term results after vascularised bone graft as treatment of Kienböck disease. *J Plast Surg Hand Surg.* 2014;48(1):21-3. doi:10.3109/2000656X.2013.793601 PMID:23731132
- Ye X, Feng JT, Yin HW, Qiu YQ, Shen YD, Xu WD. Use of 4+5 extensor compartmental vascularized bone graft and K-wire fixation for treating stage II-IIIa Kienböck's disease. *Hand Surg Rehab.* 2020;39(3):207-213. doi:10.1016/j.hansur.2020.01.005 PMID:32070791
- Moran SL, Cooney WP, Berger RA, Bishop AT, Shin AY. The use of the 4 + 5 extensor compartmental vascularized bone graft for the treatment of Kienböck's disease. *J Hand Surg Am.* 2005;30(1):50-8 doi:10.1016/j.jhsa.2004.10.002 PMID:15680555
- Kakar S, Shin AY. Vascularized bone grafting from the dorsal distal radius for Kienböck's disease: technique, indications and review of the literature. *Chir Main.* 2010;29 Suppl 1: S104-11. doi:10.1016/j.main.2010.09.003 PMID:21087888

How to Cite this Article:

Coskun T, Meydaneri S, Kurkcuoglu T. Fluoroscopic visualization of 4+5 extensor compartmental arteries in Kienböck's Disease. *Arch Trauma Res.* 2023;12(2):97-101. doi: 10.48307/ATR.2023.175286