

# Fatal Cut-Throat Injury of the Neck by Kite String

Santosh Kumar Swain

Department of Otorhinolaryngology and Head and Neck Surgery, IMS and Sum Hospital, Siksha "O" Anusandhan University, Bhubaneswar, Odisha, India

ORCID:

Santosh Kumar Swain: <https://orcid.org/0000-0001-7933-4414>

## Abstract

Flying kite is a common sport among children and even in the adult age group. Falls, cut wounds, head injuries, and fractures account for the bulk of accidents and injuries encountered while flying kites. Neck injury from a basic kite string is uncommon. Injury by kite string ranges from small cuts to major lacerations or even head trauma. The amount of abrasive material that is commonly placed on the kite's string to boost its cutting capacity determines the severity of the laceration injury. The preventive measures are to fly kites in a safe area and requirement of raising awareness of potential complications of this sport. A 56-year-old man arrived with a clean-cut, deep-incised wound that exposed the strap muscles and fat and required primary closure.

**Keywords:** Cutthroat, flying kite, kite string, laceration, neck injury

## INTRODUCTION

Kite flying is a popular springtime sport in several Asian nations, including India, China, and Pakistan.<sup>[1]</sup> Kite flying can be enjoyed in various parts of South America during the winter months.<sup>[2]</sup> The string of the kite can sometimes cause serious or even life-threatening injuries. There are several types of injuries found due to kites. The traumas are often seen on fingers and hands during preparing string.<sup>[2]</sup> There is also a chance of finger injury during the flying of the sharp string. Other sites of the body are affected by an injury during flying kite by falling from the rooftops as the person looks sky at the time of flying the kite or during the attempt to catch free-drifting kites.<sup>[3]</sup> Injury due to kites is increasing; however, there is a lack of literature on this subject. A severe neck injury caused by a kite string was shown in this case report. The exact mechanism of injury and different safety principles are discussed for avoiding such fatal injuries during kiting. This case report attempts to highlight the details of fatal injury of the neck by string of kites along with its management and its preventable measures.

## CASE REPORT

A 56-year-old man got entangled around the neck with a sharp kite string during riding his motorbike. He felt pain in the

neck and bleeding from the wound following the injury. He immediately attended the emergency department. He appeared alert, well-oriented, and pale, with mild degree of stridor in his breathing. His blood pressure and pulse were within the normal limit. On examination, there was a clean lacerated large wound at the level of the upper part of the thyroid cartilage [Figure 1]. As the patient was presenting with progressive stridor, the patient was intubated. A computed tomography (CT) scan of the neck was done on an urgent basis and showed a large hematoma at the anterior compartment of the neck compressing the trachea toward the left side [Figure 2]. The patient was immediately shifted to the operating room and exploration of the neck wound was done under general anesthesia. The size of the wound in the neck was approximately 7 cm across the anterior wall of the neck just above the upper border of the thyroid cartilage. The hematoma behind the strap muscles pressing the trachea in the anterior region of the neck was drained. The superior thyroid artery and the right-side external

**Address for correspondence:** Prof. Santosh Kumar Swain, Department of Otorhinolaryngology and Head and Neck Surgery, IMS and Sum Hospital, Siksha "O" Anusandhan University, K8, Kalinga Nagar, Bhubaneswar - 751 003, Odisha, India.  
E-mail: [santoshvoltaire@yahoo.co.in](mailto:santoshvoltaire@yahoo.co.in)

This is an open access journal, and articles are distributed under the terms of the Creative Commons Attribution-NonCommercial-ShareAlike 4.0 License, which allows others to remix, tweak, and build upon the work non-commercially, as long as appropriate credit is given and the new creations are licensed under the identical terms.

**For reprints contact:** [WKHLRPMedknow\\_reprints@wolterskluwer.com](mailto:WKHLRPMedknow_reprints@wolterskluwer.com)

**How to cite this article:** Swain SK. Fatal cut-throat injury of the neck by kite string. Arch Trauma Res 2022;11:161-3.

**Received:** 14-02-2022,

**Revised:** 25-10-2022,

**Accepted:** 26-10-2022,

**Published:** 20-12-2022.

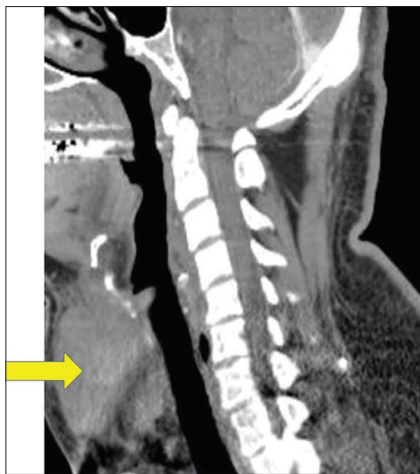
### Access this article online

Quick Response Code:

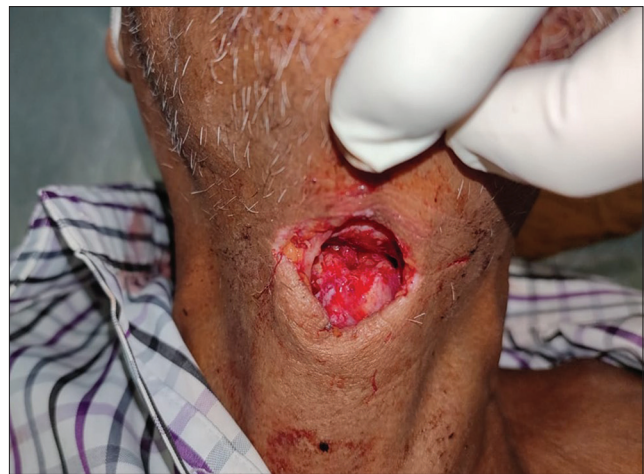

Website:  
[www.archtrauma.com](http://www.archtrauma.com)

DOI:  
10.4103/atr.atr\_10\_22



**Figure 1:** Neck injury by kite string



**Figure 2:** CT scan of the neck with hematoma in the anterior compartment. CT: Computed tomography

jugular vein were wounded, and these blood vessels were examined and ligated. An incision wound on the thyroid cartilage was present, but it did not reach the airway. With 3–0 vicryl, the neck wound was closed in layers. The patient was discharged from the hospital after 1 week after examining the laryngeal airway with help of flexible fiberoptic endoscopy. The follow-up check was done after 1 month and neck wound was healed and voice was within the normal limit without any evidence of residual sequelae.

## DISCUSSION

In festive seasons, kite flying is a very old sport practiced in India, Pakistan, China, and Malaysia.<sup>[3]</sup> Chinese often use kites to lift spies high in the air to identify enemy locations.<sup>[4]</sup> An errant kite string could strike a motorbike or bicycle rider's neck or limbs, causing serious or fatal injury. Injuries sustained by two-wheeler riders are generally more severe than those sustained by pedestrians, as the severity of the injury is determined by the vehicle's speed and the kite's moving string. When flying the kite in the rain, electric injuries can occur. The development of a pseudoaneurysm of the damaged vessel is an uncommon complication that can occur as a result of kite string injury.<sup>[4]</sup> Cyclists, motorcyclists, and pedestrians including both the adult age group and the elderly age group may sustain injuries when they come across strings of the kite. Flying kite is associated with several types of injuries ranging from simple cuts (29%) to grave lacerations and neck injuries or trauma to the head.<sup>[5]</sup> The palmer part of the hand is the most common site of damage for kite flyers, and those who merely try to snag the kite string are at risk of harm to the palmer part of the hand. The severity of injury caused by kite string is determined by the amount of abrasive material used on the string to improve its capacity to cut other kite strings.<sup>[6]</sup> The kite's string is typically coated with Manja, a mixture of ground glass and water-soluble paper glue. When human skin comes into contact with Manja, it causes laceration of the skin and deep fascia, as well as harm to internal cervical systems such

the carotid arteries, jugular vein, trachea, and larynx. One report showed two patients sustained neck injuries by a kite string where one case presented a laceration of the internal jugular vein, whereas the trachea was lacerated in the second case.<sup>[7]</sup> Five individuals were injured in the throat, and one of them had a severed artery and vein, according to a report from China, where the string of the kite caught across the bridge, on which these people were traveling and caused the disaster.<sup>[8]</sup> Motorcyclists, both adults and the elderly, may suffer injury as a result of their inattention to their surroundings when confronted with a flying or wandering kite.<sup>[9]</sup> If the killer string of the kite “Manja” is white, it may be deadly because it is difficult to spot by vehicles. In India, one news published where one person from Mumbai sustained a rupture of the larynx/voice box, and another person from Chennai sustained an injury to the neck by kite string.<sup>[10,11]</sup> Both victims were riding motorbikes during injury by kite string. In another case report, the victim was on a motorbike and sustained severe injury by kite string to the neck and shoulder.<sup>[12]</sup>

The management of neck injury should start immediately in the emergency department. If a patient has respiratory distress or a significant amount of bleeding, resuscitation should be started right away to secure the airway with intubation or a tracheostomy, and the bleeding should be stopped from the injury site. Once the patient is stable, an urgent CT scan of the neck or portable X-ray should be performed to assess the injury or to rule out compression of the trachea, vascular injury, or subcutaneous emphysema.<sup>[13]</sup> Intraoperative treatment of wounds is the same as other traumatic injuries. Care must be taken to remove any foreign body in the wound. The wound should be irrigated with normal saline. Hematoma should be evacuated thoroughly and checked for any vascular injuries. Any vessel that is found to be damaged should be ligated. Any injury to the larynx, pharynx, or esophagus, depending on the site of injury, should be expected and corrected if identified. The tracheal injury should be repaired with end-to-end anastomosis. A drain should be kept in the neck for at least 72 h and patients should be shifted to the intensive

care unit and stayed for 24 h–48 h. Patients should be treated aggressively with broad-spectrum antibiotics and generous pain medications. Fiberoptic endoscopy should be conducted after surgery to verify vocal fold mobility and airway adequacy. Other complications such as nerve damage, swallowing issues, fistulas, and failed decannulation should be monitored over time. Among the general population, awareness must be created regarding the hazards related to kite string injuries. Awareness is required regarding riskful activities, personal protective measures during a flying kite, and facilities available for managing such injuries.<sup>[14]</sup>

## CONCLUSION

Kite flying, which appears to be a harmless activity, can result in serious damage and even death, not only to the flyer but also to innocent bystanders. Kite-flying injuries are frequently avoidable. Adequate sensitivity measures, such as selecting a safe place and maintaining a safe distance from telephone lines, electricity cables, trees, animals, and even humans, are required. There is a need for greater understanding of the potential consequences of a sport like kite flying, as well as social awareness for family members, which can assist to reduce the number of injuries.

## Declaration of patient consent

The authors certify that they have obtained all appropriate patient consent forms. In the form, the patient has given his consent for his images and other clinical information to be reported in the journal. The patient understands that his name and initials will not be published and due efforts will be made to conceal his identity.

## Financial support and sponsorship

Nil.

## Conflicts of interest

There are no conflicts of interest.

## REFERENCES

1. Gupta P, Jain A, Patil AN, Thakor R, Kumar S. Kite string injury: A thin line between harmless sport and grievous injury. *Int J Community Med Public Health* 2018;5:1-4.
2. Singh V, Puri P, Agrawal A, Kumar P, Singhal R. Kite string: An unusual mode of maxillofacial injury. *J Indian Soc Pedod Prev Dent* 2013;31:188-90.
3. Prajapati C, Agrawal A, Atha R, Suri MP, Sachde JP, Shaikh MF. Study of kite string injuries in Western India. *Int J Inj Contr Saf Promot* 2017;24:136-9.
4. Hettige R, Snelling J, Bleach N. The dangers of kite flying: Pseudoaneurysm of the facial artery following blunt trauma. *J Laryngol Otol* 2010;124:223-5.
5. Mehmood N, Khwaja ZH, Ramazan S, Quddus A. Kite-flying associated injuries in Rawalpindi. *Ann Pak Inst Med Sci* 2010;6:116-9.
6. Wankhede AG, Sariya DR. “Manja” – A dangerous thread. *J Forensic Leg Med* 2008;15:189-92.
7. de Rezende Neto JB, Ferreira GC, da Silva Filho AL, Fontes MO, Bomfim F, Abrantes WL. Kiting injuries: Report of two cases and discussion. *J Trauma* 2000;48:310-1.
8. Cut Throat Kites. Available from: <http://www.google.com/Shanghai star>. [Last accessed on 2002 May 23].
9. Wankhede AG, Sariya DR. An electrocution by metal kite line. *Forensic Sci Int* 2006;163:141-3.
10. Swain SK. Kite string injury to the head-and-neck region: A review. *Annals of Indian Academy of Otorhinolaryngology Head and Neck Surgery* 2022;6:1-5.
11. Muvalia G, Jamshed N, Sinha TP, Bhoi S. Kite-string injuries: A case series. *International journal of critical illness and injury science* 2019;9:147-50.
12. Singla SL, Marwah S, Kamal H. Kite string injury – A trap for the unwary. *Inj Extra* 2009;40:277-8.
13. Borkar JL, Tumram NK, Ambade VN, Dixit PG. Fatal Wounds by “Manja” to a motorbike rider in motion. *J Forensic Sci* 2015;60:1085-7.
14. Ventura J, Hirano ES, Fraga GP. Glass-coated kites and cervical injuries: A serious threat to children and adults. *Clinics (Sao Paulo)* 2011;66:923-5.