

Histological Survey of the Effect of Granulocyte-colony-stimulating Factor (G-CSF) on Bacterial Translocation and Wound Healing in Burned Mice

Somayeh Soleymanzadeh Moghadam¹, Zeinab Fagheei Aghmiyuni^{1,2}, Nazanin Mohammad¹, Ali Anissian³, Maryam Azimi^{4,5}, Ali Majidpour¹, Farinaz Nasirinezhad⁶, Maryam Roham¹

¹Antimicrobial Resistance Research Center, Institute of Immunology and Infectious Diseases, Iran University of Medical Sciences, Tehran, Iran, ²Eye Research Center, The Five Senses Institute, Rassoul Akram Hospital, Iran University of Medical Sciences, Tehran, Iran, ³Immunology Research Center, Institute of Immunology and Infectious Diseases, Iran University of Medical Sciences, Tehran, Iran, ⁴Department of Immunology, School of Medicine, Tehran University of Medical Sciences, Tehran, Iran, ⁵Physiology Research Center, Iran University of Medical Sciences, Tehran, Iran, ⁶Department of Veterinary Medicine, Azad University, Abhar Branch, Abhar, Iran

ORCID:

Somayeh Soleymanzadeh Moghadam: <https://orcid.org/0000-0002-2605-2402>

Zeinab Fagheei Aghmiyuni: <https://orcid.org/0000-0003-2071-7060>

Nazanin Mohammad: <https://orcid.org/0000-0002-1815-3721>

Ali Anissian: <https://orcid.org/0000-0002-5754-1049>

Maryam Azimi: <https://orcid.org/0000-0002-6231-6073>

Ali Majidpour: <https://orcid.org/0000-0001-7440-1817>

Farinaz Nasirinezhad: <https://orcid.org/0000-0001-6285-1036>

Maryam Roham: <https://orcid.org/0000-0001-5406-709x>

Abstract

Background: Burn wound is an important cause of morbidity and mortality worldwide. Improving the host's immune system and removing the infection can be effective in healing wounds caused by burns. Granulocyte-colony-stimulating factor (G-CSF) stimulates both the bone marrow to produce granulocytes and the function of neutrophil precursors. The aim of this study was to examine the effect of G-CSF on removing infection and healing wound. **Materials and Methods:** A burn model was used to induce burns in 18 adult Balb/c mice, and their wounds were infected by *Acinetobacter baumannii* strains. Burned mice were divided into two groups (control and G-CSF) and treated daily by subcutaneous injections of normal saline (0.1 mL) and G-CSF (10 µg/kg). The wound healing process was evaluated by the morphological and histological assessments. **Results:** In morphological assay, the mean size of the wounds in the 3rd and 7th days of the treatment was significantly lower in the G-CSF treated group compared to the control group. Some of the histological parameters were evaluated, including the level of inflammation, re-epithelialization, angiogenesis, collagen deposition, the amount of granulation tissue, and fibroblast maturation. The results showed that inflammation was reduced in the G-CSF-treated group, and re-epithelialization and collagen deposition were increased insignificantly compared to the normal saline-treated group. Furthermore, bacterial translocation was reduced significantly in the G-CSF-treated group. **Conclusion:** G-CSF enhances wound closure and helps in wound healing by improving the immune system. It has also an anti-inflammatory role and reduces bacterial translocation.

Keywords: *Acinetobacter baumannii*, burn, granulocyte-colony-stimulating factor, wound healing

INTRODUCTION

Burn wound is one of the main causes of disability and mortality in human, which imposes severe economic and social consequences on community, particularly in developing

Address for correspondence: Dr. Maryam Roham, Antimicrobial Resistance Research Center, Rasoul Hospital, Niayesh Street, Sattarkhan Street, Tehran, Iran. E-mail: roham.m@iums.ac.ir

Received: 25-04-2019

Revised: 18-08-2019

Accepted: 01-09-2019

Published: 26-11-2019

Access this article online

Quick Response Code:



Website:
www.archtrauma.com

DOI:
10.4103/atr.atr_20_19

This is an open access journal, and articles are distributed under the terms of the Creative Commons Attribution-NonCommercial-ShareAlike 4.0 License, which allows others to remix, tweak, and build upon the work non-commercially, as long as appropriate credit is given and the new creations are licensed under the identical terms.

For reprints contact: reprints@medknow.com

How to cite this article: Moghadam SS, Aghmiyuni ZF, Mohammad N, Anissian A, Azimi M, Majidpour A, et al. Histological survey of the effect of granulocyte-colony-stimulating factor (G-CSF) on bacterial translocation and wound healing in burned mice. Arch Trauma Res 2019;8:149-54.

countries.^[1,2] Infection is considered as the common feature of burns because skin, which acts as a protective layer against microbes, is damaged in burns.^[1] In addition, the immune system weakens in the burns, and the body becomes susceptible to various infections and sepsis.^[2,3] Some studies have reported that bacterial translocation occurs after some types of stress, thermal injury, significant trauma, host immune deficiencies, immunosuppression, disruption of the ecologic gastrointestinal equilibrium to allow intestinal bacterial overgrowth, and increased permeability of the intestinal mucosal barrier.^[4] It is the invasion of gastrointestinal tract flora bacteria and their toxins which normally sterile tissues and the extraintestinal sites such as the mesenteric lymph nodes, liver, spleen, kidney, and bloodstream.^[3,4] Evidence suggests that translocation of indigenous bacteria from the gastrointestinal tract is an important early step in the pathogenesis of opportunistic infections originating from the gastrointestinal tract.^[4] *Acinetobacter baumannii* (Ab) is the common bacterium in nosocomial burn wound infections^[5,6] because multidrug-resistant (MDR) Ab strains have increased in recent years.^[4,5] Therefore, it is necessary to find new therapeutic drugs to prevent bacterial translocation, improve host's immune system, and remove infection in burns.^[7] Granulocyte-colony-stimulating factor (G-CSF), produced by monocytes and fibroblasts, is a glycoprotein stimulating the bone marrow.^[3] It also stimulates the survival, proliferation, differentiation, and function of neutrophil precursors and mature neutrophils with signal transduction pathways.^[8] Patients with severe burn trauma often display significant impairments in cell-mediated immunity, including defective neutrophil chemotaxis, phagocytosis, and superoxide production, resulting in increased susceptibility to infection.^[9] In some studies, it was shown that G-CSF is effective in reducing bacterial translocation and bacterial colonization and helps in wound healing.^[10] Moreover, G-CSF angiogenesis property in endothelial cells (ECs) was determined *in vitro* and *in vivo*.^[11,12] The results of the Huang *et al.* (2017) study indicated that G-CSF angiogenic effects were enhanced *in vitro*.^[13] Brubaker AL and Kovacs EJ *et al.* found that heightened bacterial colonization and delayed wound closure in aged mice could be attenuated by treatment with G-CSF.^[14] Recently, evidence has suggested that G-CSF plays a tissue-protecting role and promotes tissue repair and regeneration in many injuries through anti-inflammatory capabilities of host's cells.^[15] However, the effects of G-CSF on wound size and its microscopic histological factors in burn injury have not been yet explicated clearly. Therefore, the aim of this study was to examine the histological effects of G-CSF on bacterial translocation in mice suffering from burn wound infection.

MATERIALS AND METHODS

This study was performed in two steps including *in vitro* and *in vivo* as follows:

In vitro step: Clinical isolates

In this step, MDR-Ab clinical isolates were used for inoculation of the wound *in vivo*. Ab strains were isolated from the burn

wound of patients referred to Motahari Hospital Affiliated to Iran University of Medical Sciences.

In vivo step: Animal model

In this study, 18 adult Balb/c mice with the age ranging from 18 to 20 months and mean weight of 20 ± 2 g were purchased from laboratory animals breeding center in Alborz Province. All animals were transferred to the breeding center of Iran University of Medical Sciences. All of which were maintained under the controlled environmental conditions, including room temperature of $32^\circ\text{C} \pm 2^\circ\text{C}$, relative humidity of 60%–70%, and photoperiod of 12 h light and 12 h dark. Food and water were available, and animals were randomly assigned into two groups of nine animals. All experimental techniques involving animals were approved by the Experimental Animal Ethics Committee of Iran University of Medical Sciences with IR.IUMS.REC1393.95474.

Induction of wounds and treatment procedure

The mice were anesthetized by an intraperitoneal injection of a ketamine–xylazine cocktail (ketamine 10 mg/kg + xylazine 4 mg/kg). Then, the dorsal area of all the animals was disinfected by 70% ethanol and shaved. The second-degree burns were induced on animals' dorsal shaved area by a hot device like a circular steel rod (diameter = 2 cm and length = 20 cm) at 95°C for 8 s (setup by the research team). The dorsal area was dressed with a sterilized gas. After 24 h of burn induction, the wounds were inoculated by 0.1 mL of resistant Ab clinical isolates (1.5×10^8 CFU/mL).

Burn wound treatment

Twenty-four hours after induction of infection, all animals were randomly divided into two groups ($n = 9$ in each group). Burns in two groups were daily treated by subcutaneous injection (0.1 mL) in the area around the wound for 7 days following the burn wound infection by Ab as follows:

1. Group I (control) – Induction of burns on the skin + inoculated with 0.1 mL of resistant Ab clinical isolates + treatment by subcutaneous injections of normal saline (0.1 mL)
2. Group II (experimental) – Induction of burns on the skin + inoculated with 0.1 mL of resistant Ab clinical isolates + treatment by subcutaneous injections of G-CSF (10 $\mu\text{g}/\text{kg}$).

Evaluation of the wound healing process

All the animals were sacrificed using an overdose of xylazine, under anesthesia, 7 days after the start of treatment, and then, the extent of wound healing was evaluated.

Morphological assessment of burn wounds

The size of the burn wound was evaluated 24 h after the burn induction (before the start of treatment: day 0) and at the 3rd and 7th (last) days of posttreatment in two groups by measuring the wound's surface area with naked eyes using a ruler.^[16]

Histological assessment of burn wounds

After 7 days, animals were terminally anesthetized with xylazine, and 3 cm \times 3 cm wound skin tissues were removed. The wound tissues were immediately fixed with 10% formalin and 8% NaCl,

and then, paraffin-embedded sections were prepared. The sections were cut by a microtome with 2 µm thickness and stained with hematoxylin and eosin (H and E) and Masson's Trichrome stains for light microscopy examinations.^[13,17] The accuracy of collagen deposition scoring was increased by Masson's trichrome stains.^[13,17] All specimens were evaluated by a pathologist who was blind to the tissue type. The main histological parameters included the amount of inflammation, re-epithelialization, angiogenesis, collagen deposition, the amount of granulation tissue, and fibroblast maturation. A histological scoring system, which was developed specifically for this study based on the scoring system suggested by Abramov *et al.*, was used.^[15,18] Accordingly, in this study, each histological parameter was assessed independently by assigning a score of 0–3 to it (0: none, 1: scant, 2: moderate, and 3: abundant). A paired sample *t*-test was used to compare the control and treatment groups.

Surgery and biopsy of tissue

A surgical biopsy was performed to evaluate the translocation and presence of white blood cells (WBCs) in the tissue. After removing the skin tissues and cutting the ventral area, the liver and spleen and ileum were removed. A part of the incisions was homogenized in a separate sterile plate containing 1 mL phosphate-buffered saline using the sterile scalpel method. Homogenized tissues were cultured on plates containing blood, and MacConkey agar was used for the observation and identification of Gram-negative microorganisms using standard microbiological methods. After 24 h of incubation, all cultivated plates were checked to evaluate the bacterial growth and bacterial translocation.^[17] The other parts of each tissue were transferred to 50 mL sterile tubes containing 10% formalin and 8% NaCl and stored at 25°C for histological survey in terms of the presence of WBC. Comparisons between the groups were performed using the Chi-square test.

Tissue histology – Sample preparation

Tissue specimens were dehydrated by the tissue processing machine according to the manufacturer's instruction. The dehydrated specimens were embedded in paraffin with a paraffin dispenser and cut by a microtome with 2 µm thickness. The thick sections were fixed on the slide and prepared for histopathology staining. Specimens were stained with H and E and checked for the presence or increased count of WBCs using a light microscope by a histologist. In this section, statistical analyses were performed using the Chi-square test.

Statistical analysis

Statistical analyses were performed using Spss, version 20, IBM Corp., Armonk, NY, USA. Comparisons between the control and treatment groups were performed using the paired-sample *t*-test and Chi-square test. A *P* < 0.05 was considered as statistically significant.

RESULTS

Wound size examination

The mean size of the wound in the 3rd and 7th (last) days of the treatment was significantly reduced in the treatment group compared to that of the control group [Table 1].

Histological examination

After burn induction and treatment, histological parameters such as the amount of inflammation, re-epithelialization, angiogenesis, collagen deposition, the amount of granulation tissue, and fibroblast maturation were evaluated in burn wounds of all specimens. These parameters were evaluated based on the histological scoring system [Table 2].

As shown in Table 2 and Figure 1a-h, the level of inflammation was reduced in the G-CSF treated group. Moreover, the levels of re-epithelialization and collagen deposition were increased in this group compared to the normal saline-treated group but not statistically significant (*P* > 0.05).

Tissue histology – Bacterial translocation

To evaluate the bacterial translocation, homogenized liver and spleen tissues were cultured on microbial media.

Expectedly, in the G-CSF treated group, all mice showed significantly lower bacterial translocation compared with the control group (*P* = 0.02). The prevalence rates of the translocated organisms after wound burn infection in both groups are shown in Table 3.

Tissue histology – The presence of white blood cells

The amount of inflammation and the presence or increased count of WBCs in the G-CSF treated and control groups were measured using a light microscope. As shown in Table 4, there was no significant difference between the two groups regarding the WBC numbers in both liver and spleen tissues (*P* > 0.05).

DISCUSSION

Traumatic injury has a repressive effect on the immune system and decreased G-CSF, resulting in the increased susceptibility to infection.^[19] It is specified that G-CSF could increase the number of circulating polymorphonuclear leukocytes in response to chemotactic peptides and help in wound closure.^[16,20] Previous studies showed that burned patients with severe infections benefit from treatment by G-CSF.^[21] In the present study, the beneficial effects of treatment by G-CSF on wound healing were demonstrated in male mice following wound infections caused by *Ab* strains. After burn induction in mice, the wound size was measured at the 3rd and 7th days; expectedly, the findings showed that the wound size in the

Table 1: Mean of wound size (36) after burn wound induction at the 3rd and 7th days of treatment in two groups (normal saline group and granulocyte-colony-stimulating factor group), each with nine mice (mean±standard deviation)

Groups	Size of burn wound (mean±SD)	
	Third day	Seventh day
Normal saline group	2.53±0.48*	2.15±0.32*
G-CSF group	1.08±0.55**	1.18±0.81**

P*=0.000, *P*=0.01. G-CSF: Granulocyte-colony-stimulating factor, SD: Standard deviation

Table 2: The survey of wound healing histologic parameters of the skin at the 7th day of treatment in burned mice

Groups	Level of inflammation	Re-epithelialization	Angiogenesis	Collagen deposition	The amount of granulation tissue	Fibroblast maturation
Normal saline group	1.85±1.06	0.42±0.53	1.42±1.39	1.14±0.89	2±1.41	1.28±1.11
G-CSF group	0.85±1.06	1.14±1.06	1±1	1.71±1.25	2±1.15	1.14±1.06

The effect of GCSF according to the scoring system at the 7th day of treatment in two groups (normal saline group and GCSF group) of nine mice each (mean±SD). G-CSF: Granulocyte-colony-stimulating factor, SD: Standard deviation

Table 3: Assessment of Bacterial translocation of enteric organisms after wound burn and infection based on the presence of bacteria in the liver and spleen

Organ	Observation	Count	Groups		Total
			Control group	G-CSF group	
Liver ^a	Presence of bacteria	Count	3	0	3
		Expected count	1.8	1.2	3.0
	Absence of bacteria	Count	6	6	12
		Expected count	7.2	4.8	12.0
Total	Count	9	6	15	
	Expected count	9.0	6.0	15.0	
Spleen ^b	Presence of bacteria	Count	5	0	5
		Expected count	3.0	2.0	5.0
	Absence of bacteria	Count	4	6	10
		Expected count	6.0	4.0	10.0
Total	Count	9	6	15	
	Expected count	9.0	6.0	15.0	

Chi-square test: ^aValue: 2.5, df: 1, Significant: 0.11, ^b Value: 5, df: 1, significant: 0.02. G-CSF: Granulocyte-colony-stimulating factor

Table 4: The survey of white blood cells count in both of liver and spleen in the granulocyte-colony-stimulating factor treatment and control groups

Organ	Observation	Count	Groups		Total
			Control group	G-CSF group	
Liver ^a	Increased count of WBC	Count	1	1	2
		Expected count	1.1	0.9	2.0
	No increase in the count of WBC	Count	8	7	15
		Expected count	7.9	7.1	15.0
Total	Count	9	8	17	
	Expected count	9.0	8.0	17.0	
Spleen ^b	Increased count of WBC	Count	0	1	1
		Expected count	0.5	0.5	1.0
	No increase in the count of WBC	Count	9	7	16
		Expected count	8.5	7.5	16.0
Total	Count	9	8	17	
	Expected count	9.0	8.0	17.0	

Chi-square test: ^aValue: 0.008, df: 1, significant: 0.92, ^bValue: 1.05, df: 1, significant: 0.3. WBC: White blood cell, G-CSF: Granulocyte-colony-stimulating factor

G-CSF treated group was significantly lower than that in the control group. In this regard, the results of the present study are in line with other relevant studies. Furthermore, the results of the Fine *et al.* study indicated that G-CSF enhanced wound closure in 75.5% of the G-CSF treated patients. In their study, seven burned patients with severe infections were treated daily with subcutaneous G-CSF. After 7 days, all patients showed a significant reduction in a lesion size and blister or erosion counts.^[21] Furthermore, in another similar study conducted

by Brubaker and Kovacs, it was found that a wound size was reduced in the G-CSF-treated aged animals 3 and 7 days after the wound infection.^[14,22]

As shown in Table 2 and Figure 1a-h, in this study, the level of inflammation was insignificantly reduced in the G-CSF treated group.

As expected, the findings of the present study are in line with those of other similar studies showing that G-CSF has

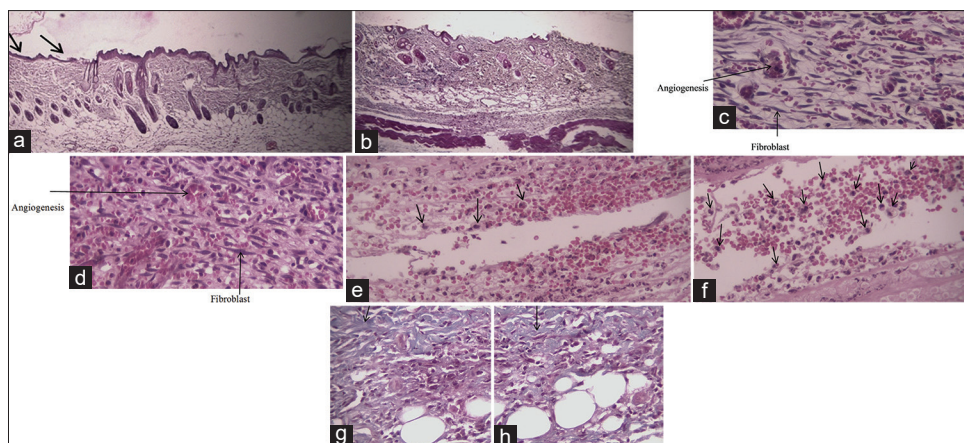


Figure 1: Photomicrograph of sections of the skin at the 7th day of treatment in burned mice by H and E and Masson's trichrome stains ($\times 40$ and $\times 100$). Re-epithelialization in the granulocyte-colony-stimulating factor group (a) and control group (b), angiogenesis and fibroblast in the granulocyte-colony-stimulating factor group (c) and control group (d), inflammation in the granulocyte-colony-stimulating factor group (e) and control group (f), and collagen deposition in the granulocyte-colony-stimulating factor group (g) and control group (h)

therapeutic effects on tissue repair and regeneration, partly by ameliorating inflammation, re-epithelialization, and enhancing angiogenesis in various ischemic conditions.^[23,24] In this regard, in a study conducted by Hartung *et al.* (1998), G-CSF was introduced as an anti-inflammatory immunomodulator.^[25] Moreover, recent studies have shown that G-CSF could decrease inflammation by inhibiting the production or activity of the main inflammatory mediators, including interleukin (IL)-1 and interferon-gamma.^[21,25,26] Furthermore, in 2016, Liao *et al.* indicated that systemic G-CSF treatment after nerve injury could upregulate μ -opioid receptor in the injured nerve, And decrease peripheral nociceptive signals. This treatment could suppress the pro-inflammatory cytokines but enhance the anti-inflammatory cytokines, i.e., IL-4.^[26]

These studies can partly confirm our study in relation to G-CSF anti-inflammatory effect.

In addition, in a study conducted *in vitro* and *in vivo*, it was observed that recombinant G-CSF could increase angiogenesis,^[12,27] but in some studies and ours, it was shown that G-CSF decreases EC angiogenesis. Therefore, it is possible that the observation of angiogenesis following the prescription of G-CSF comes only due to the hematopoietic progenitor cells.^[1,28] Because of the contradiction in these results, it seems that further studies are needed to be conducted.

In this study, it was also shown that G-CSF could reduce bacterial translocation in the G-CSF-treated group compared to the control group. Furthermore, the Yalçın O *et al.* study showed that widespread use of G-CSF decreases bacterial translocation significantly.^[10] The results of Hong-Fang *et al.* study indicated that G-CSF could enhance levels of the opsonin receptors, CD11b and CD32/16, which are necessary for antimicrobial function and provided protection against infection in animal models of severe acute pancreatitis.^[29]

Although the role of G-CSF in reducing inflammation and infection of wound is under investigation, it seems that G-CSF

can accelerate bacterial clearance and ameliorate inflammation by improving immune system and neutrophil function in the sites of inflamed wound.^[14,30]

In a recent study performed by this research team, it was found that G-CSF could elevate the number of circulating leukocytes,^[31] while there was no significant difference between the groups regarding the number of tissue-derived WBCs. According to the effect of G-CSF on bacterial translocation, it was found that G-CSF preferably enhances bactericidal activity. In addition, regarding the effects of G-CSF in patients with neutropenia^[32] as well as donors before hematopoietic stem cell transplantation,^[32] it seems that the use of G-CSF may be functional in infectious wound, where neutrophils are absent or dysfunctional.

CONCLUSION

The findings of the present study reveal that G-CSF could enhance wound closure. Furthermore, it was shown that G-CSF has an anti-inflammatory role in wound healing and reduces bacterial translocation. Together, these reports provided novel indications for the use of G-CSF as therapeutic interventions.

Acknowledgments

The authors thank Mr. Hossein Noori Mazandarani in animal laboratory of Iran University of Medical Sciences. This project was supported by Iran University of Medical Sciences with grant number 25985.

Financial support and sponsorship

The study was financially supported by Iran University of Medical Sciences with grant number 25985.

Conflicts of interest

There are no conflicts of interest.

REFERENCES

- Singh P, Harish D. Incidence of post burn septicemia at a tertiary care hospital. *JIAFM* Oct-Dec2011. 2011;33:319-23.

2. Agbenorku P, Aboah K, Akpaloo J, Amankwa R, Farhat B, Turkson E, et al. Epidemiological studies of burn patients in a burn center in Ghana: any clues for prevention? *Burns & trauma*. 2016;4:21.
3. Deotare U, Al-Dawsari G, Couban S, Lipton J. G-CSF-primed bone marrow as a source of stem cells for allografting: revisiting the concept. *Bone marrow transplantation*. 2015;50:1150.
4. Wiest R. Bacterial translocation. *Bioscience and microflora*. 2005;24:61-90.
5. Tekin R, Dal T, Bozkurt F, Devenci Ö, Palancı Y, Arslan E, et al. Risk factors for nosocomial burn wound infection caused by multidrug resistant *Acinetobacter baumannii*. *Journal of Burn Care & Research*. 2014;35:e73-e80.
6. Dasari H, Kumar A, Sharma B. Burns Septicemia—The Leading cause of burn mortality. *Journal of Punjab Academy of Forensic Medicine & Toxicology*. 2008;8:10-6.
7. Harrison C. Innate immunity as a key element in host defense against methicillin resistant *Staphylococcus aureus*. *Minerva pediatrica*. 2009;61:503-14.
8. Horiuchi T, Shimizu K, Sasaki K, Kato A, Homma Y. Granulocyte-colony stimulating factor producing infiltrating urothelial carcinoma of the left renal pelvis: a case report. *Urology case reports*. 2017;10:11-3.
9. Kramer GC, Lund T, Herndon D. Pathophysiology of burn shock and burn edema. In *Total Burn Care* (Herndon DN, 4th ed). 2012:103-13.
10. Yalçın O, Soybir G, Köksoy F, Köse H, Öztürk R, Çokne B. Effects of granulocyte colony-stimulating factor on bacterial translocation due to burn wound sepsis. *Surgery today*. 1997;27:154-8.
11. Chen CH, Sereti KI, Wu BM, Ardehali R. Translational aspects of cardiac cell therapy. *Journal of cellular and molecular medicine*. 2015;19:1757-72.
12. Lee M, Aoki M, Kondo T, Kobayashi K, Okumura K, Komori K, et al. Therapeutic angiogenesis with intramuscular injection of low-dose recombinant granulocyte-colony stimulating factor. *Arteriosclerosis, thrombosis, and vascular biology*. 2005;25:2535-41.
13. Huang H, Zhang Q, Liu J, Hao H, Jiang C, Han W. Granulocyte-colony stimulating factor (G-CSF) accelerates wound healing in hemorrhagic shock rats by enhancing angiogenesis and attenuating apoptosis. *Medical science monitor: international medical journal of experimental and clinical research*. 2017;23:2644.
14. Brubaker AL, Kovacs EJ. G-CSF enhances resolution of *Staphylococcus aureus* wound infection in an age-dependent manner. *Shock* (Augusta, Ga). 2013;40:327.
15. Greenhalgh DG, Sprugel KH, Murray MJ, Ross R. PDGF and FGF stimulate wound healing in the genetically diabetic mouse. *The American journal of pathology*. 1990;136:1235.
16. Eroglu E, Agalar F, Altuntas I, Eroglu F. Effects of granulocyte-colony stimulating factor on wound healing in a mouse model of burn trauma. *The Tohoku journal of experimental medicine*. 2004;204:11-6.
17. Thompson MG, Black CC, Pavlicek RL, Honnold CL, Wise MC, Alamneh YA, et al. Validation of a novel murine wound model of *Acinetobacter baumannii* infection. *Antimicrobial agents and chemotherapy*. 2014;58:1332-42.
18. Abramov Y, Golden B, Sullivan M, Botros SM, Miller JJR, Alshahrour A, et al. Histologic characterization of vaginal vs. abdominal surgical wound healing in a rabbit model. *Wound repair and regeneration*. 2007;15:80-6.
19. Gardner JC, Noel JG, Nikolaidis NM, Karns R, Aronow BJ, Ogle CK, et al. G-CSF drives a posttraumatic immune program that protects the host from infection. *The Journal of Immunology*. 2014;192:2405-17.
20. Cohen AM, Hines DK, Korach ES, Ratzkin BJ. In vivo activation of neutrophil function in hamsters by recombinant human granulocyte colony-stimulating factor. *Infection and immunity*. 1988;56:2861-5.
21. Martins A, Han J, Kim SO. The multifaceted effects of granulocyte colony-stimulating factor in immunomodulation and potential roles in intestinal immune homeostasis. *IUBMB life*. 2010;62:611-7.
22. Fine J-D, Manes B, Frangoul H. Systemic granulocyte colony-stimulating factor (G-CSF) enhances wound healing in dystrophic epidermolysis bullosa (DEB): Results of a pilot trial. *Journal of the American Academy of Dermatology*. 2015;73:56-61.
23. Roberts AW. G-CSF: a key regulator of neutrophil production, but that's not all! *Growth factors*. 2005;23:33-41.
24. Petit I, Szyper-Kravitz M, Nagler A, Lahav M, Peled A, Habler L, et al. G-CSF induces stem cell mobilization by decreasing bone marrow SDF-1 and up-regulating CXCR4. *Nature immunology*. 2002;3:687.
25. Hartung T. Anti-inflammatory effects of granulocyte colony-stimulating factor. *Current opinion in hematology*. 1998;5:221-5.
26. Liao M-F, Yeh S-R, Lo A-L, Chao P-K, Lee Y-L, Hung Y-H, et al. An early granulocyte colony-stimulating factor treatment attenuates neuropathic pain through activation of mu opioid receptors on the injured nerve. *Scientific reports*. 2016;6:25490.
27. Wallner S, Peters S, Pitzer C, Resch H, Bogdahn U, Schneider A. The granulocyte-colony stimulating factor has a dual role in neuronal and vascular plasticity. *Frontiers in cell and developmental biology*. 2015;3:48.
28. Sato D, Otani H, Fujita M, Shimazu T, Yoshioka K, Enoki C, et al. Granulocyte colony-stimulating factor does not enhance recruitment of bone marrow-derived cells in rats with acute myocardial infarction. *Experimental & Clinical Cardiology*. 2012;17:83.
29. Tuo H-F, Peng Y-H, Bao L, Zhang W-X. Effects of Granulocyte Colony-Stimulating Factor on Opsonin Receptor Expression and Neutrophil Antibacterial Activity in a Mouse Model of Severe Acute Pancreatitis. *Advances in Hygiene & Experimental Medicine/Postepy Higieny i Medycyny Doswiadczalnej*. 2017;71.
30. Park S, Rich J, Hanses F, Lee JC. Defects in innate immunity predispose C57BL/6J-Leprd/Leprd mice to infection by *Staphylococcus aureus*. *Infection and immunity*. 2009;77:1008-14.
31. Moghadam SS, Aghmiyuni ZF, Zaheri H, Arianpour N, Danaeifard MR, Roham M, et al. Comparative effects of granulocyte-colony stimulating factor and colistin-alone or in combination on burn wound healing in *Acinetobacter baumannii* infected mice. *Iranian journal of microbiology*. 2018;10:371.
32. Martino M, Fedele R, Massara E, Recchia AG, Irrera G, Morabito F. Long-term safety of granulocyte colony-stimulating factor in normal donors: is it all clear? *Expert opinion on biological therapy*. 2012;12:609-21.