

# The Effect of Splenic Hilum Ligation on the Injured Spleen and Its Function in Rat Model

Mehrdad Hosseinpour, Amir Hossein Irajpour<sup>1</sup>, Naghme Poorjam

Departement of General Surgery, Imam Hossein Children Hospital, Isfahan University of Medical Sciences, <sup>1</sup>Departement of General Surgery, Isfahan University of Medical Sciences, Isfahan, Iran

ORCID:

Mehrdad Hosseinpour: <https://orcid.org/0000-0001-9242-2873>

Naghme Poorjam: <https://orcid.org/0000-0002-2680-8409>

## Abstract

**Background:** The aim of this study was to compare the outcome of splenic hilum ligation (SHL) and splenectomy in spleen trauma in rat model. **Methods:** This interventional study was performed on 38 rats with spleen injuries. Rats were randomly divided into SHL and splenectomy groups. After 7 days of surgery, IgG, IgA, IgM, and IgE were measured. At this time, blood smear was prepared to evaluate Howell–Jolly bodies, target cells, schistocyte, poikilocyte, and anisocyte. Three months after the surgery, the spleen viability was evaluated by relaparotomy. **Results:** After 7 days, white blood count was significantly lower in SHL group as compared to control group ( $P = 0.024$ ). All variables in peripheral blood smear were significantly lower in SHL group as compared to control group, except Howell–Jolly bodies ( $P = 0.461$ ). In the SHL group, all spleens were viable in second operations. **Conclusions:** SHL can be used safely in the management of traumatic splenic injuries in rats.

**Keywords:** Hilum ligation, nonoperative management, splenic injuries

## INTRODUCTION

Splenic injuries after major abdominal trauma are common and can be associated with major morbidities or even death.<sup>[1,2]</sup> Most of the surgeons are desired to save spleen with different methods, to decrease the side effects of splenectomy, especially in children.<sup>[3-6]</sup>

Different methods such as nonoperative management and splenic artery embolization (SAE) have been described to prevent splenectomy. SAE is reported to increase the success rate of saving spleen, approaching 98%.<sup>[7-9]</sup> However, some studies showed some serious side effects in SAE including splenic abscesses, infarction, cysts, contrast-induced renal insufficiency, left-sided pleural effusions, coil migration, and fever.<sup>[10]</sup>

In this study, we performed splenic hilum ligation (SHL) without resection to compare the outcome of this method with splenectomy in the rats with splenic trauma injuries. Our hypothesis is that the short gastric circulation is sufficient as whole blood supply for injured unresected small spleen.

## METHODS

### Study design and target group

In an interventional study in the Surgery Department of St-Zahra Hospital in Isfahan at the center of Iran from August to December 2015, 40 Wistar-Albino rats were selected. All experiments were performed in accordance with relevant guidelines and regulations (i.e., IACUC guidelines and federal regulations). Approval of the study by an Institutional Review Board was obtained. The ethics approval from the Ethics Committee of Isfahan University of Medical Sciences (395020) was taken.

The study flowchart is shown in Figure 1. Forty Wistar-Albino rats (with age 6–8 weeks) undergone surgery and inclusion

**Address for correspondence:** Dr. Mehrdad Hosseinpour, Imam Hossein Hospital, Isfahan University of Medical Sciences, Imam Khomeini Blvd, Isfahan, Iran.  
E-mail: [meh\\_hosseinpour@yahoo.com](mailto:meh_hosseinpour@yahoo.com)

This is an open access journal, and articles are distributed under the terms of the Creative Commons Attribution-NonCommercial-ShareAlike 4.0 License, which allows others to remix, tweak, and build upon the work non-commercially, as long as appropriate credit is given and the new creations are licensed under the identical terms.

**For reprints contact:** [reprints@medknow.com](mailto:reprints@medknow.com)

**How to cite this article:** Hosseinpour M, Irajpour AH, Poorjam N. The effect of splenic hilum ligation on the injured spleen and its function in rat model. Arch Trauma Res 2019;8:6-10.

**Received:** 27-07-2018, **Accepted:** 17-05-2019.

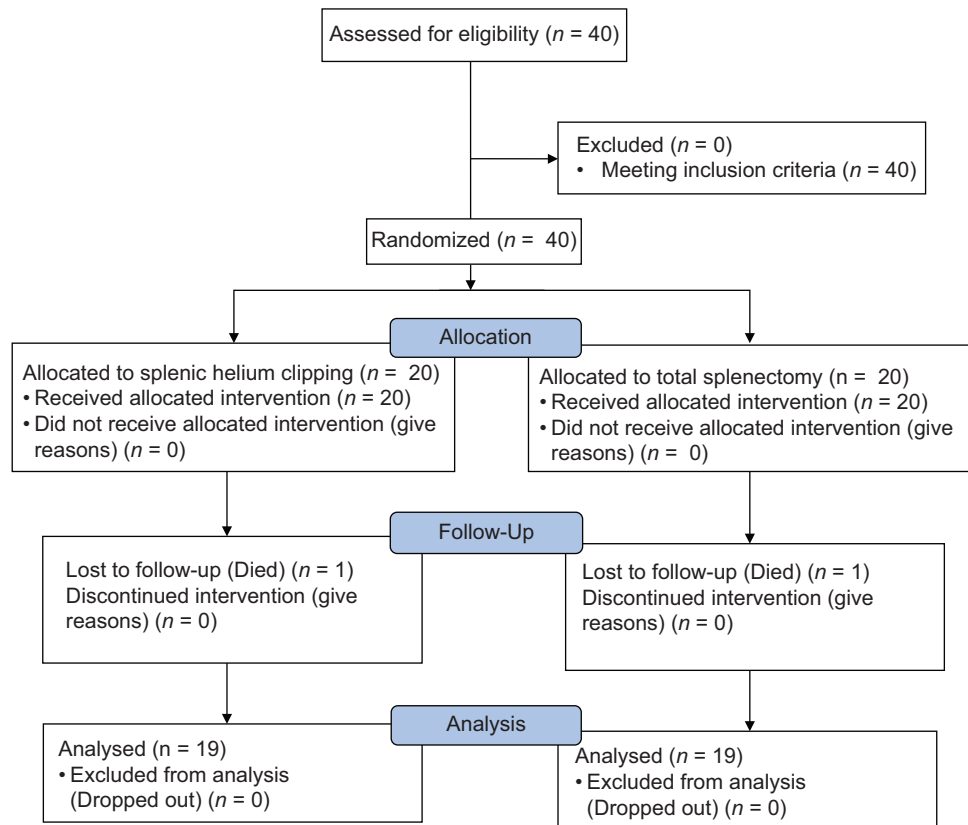
### Access this article online

#### Quick Response Code:



**Website:**  
[www.archtrauma.com](http://www.archtrauma.com)

**DOI:**  
10.4103/atr.atr\_49\_18



**Figure 1:** Study flowchart (CONSORT format)

and exclusion criteria were included. The rats were randomly allocated in two groups using a block randomization procedure with matched subjects in each block based on sex and age. Exclusion criteria consisted of rats died during the study due to other reasons.

Housing was performed in a controlled environment for at least 2 days before starting the experiment. Rats were fasted for 4 h before the experiment. Under general anesthesia with ketamine (35 mg/kg intramuscularly), acepromazine (1.2 mg/kg intramuscularly), and nitrogen oxide/oxygen (50%:50%) plus halothane 3%–4%, the rats were placed in the supine position throughout the experiment. Antisepsis was provided by chlorhexidine. With 5 cm length incision, rat abdomen was opened in midline. After exploration of the abdomen, a deep stab wound is created in the lower pole of the spleen with a scalpel blade. In the control group, total splenectomy was performed. In SHL, after total separation of spleen, a splenocolic ligament was cut. The spleen was mobilized medially, and main splenic vessels were divided closely into the hilum after double ligation with silk 2/0 [Figure 2]. Gastrosplenic ligament, which contains short gastric vessels, remained intact. After complete hemostasis, the abdomen was closed. The operative time was recorded, and blood loss in surgery was measured based on gauze consumption. After the surgery, the rats had free access to oral feeding at the 1<sup>st</sup> postoperative day. The rats received subcutaneous postoperative analgesia with flunixin (Razak Co., Iran), they

also received syrup cefazolin in a dose of 20 mg/kg/d by oral gavage for three times in a day.

After 7 days of surgery, differential white blood cell count was performed with Giemsa stain and under the low power ( $\times 10$ ). As well as, red blood cells count, hemoglobin, and hematocrit were measured after 7 days.

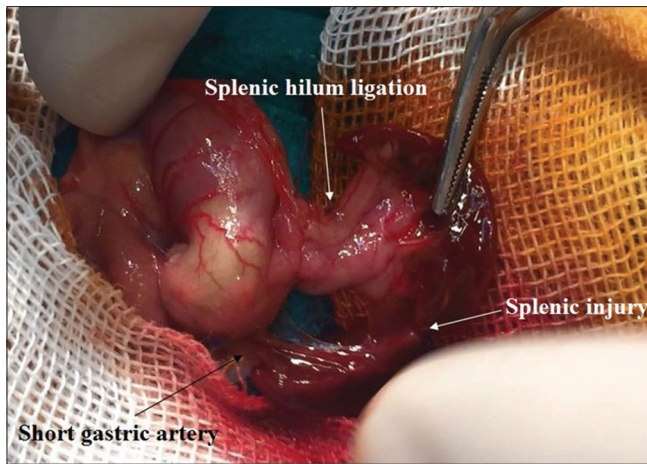
After 3 months of surgery, rats were explored to evaluate the spleen viability. At this time, blood smear was prepared to evaluate Howell–Jolly bodies, target cells, schistocyte, poikilocyte, and anisocyte, and IgG, IgA, IgM, and IgE were measured with Elisa method (Monobind, USA).

### Data analysis

Data were analyzed and reported only for rats which completed the study. Statistical analysis of data was performed using SPSS ver 22 (SPSS Co, Chicago, ILL, USA). To compare qualitative variables between groups, Chi-square test was performed. The normal distribution of all studied parameters was checked with Kolmogorov–Smirnov test. Student's *t*-test and paired *t*-test were used for normal distributed variables. Mann–Whitney and Wilcoxon test were performed for variables that have not normal distribution.  $P < 0.05$  was considered as statistically significant.

## RESULTS

Two rats were dropped out, and finally, 38 rats completed the study. In the SHL group, one rat died after 2 weeks, while in



**Figure 2:** Mobilization of spleen and division main splenic vessels

the control group, one rat died after 6 weeks. By evaluation of both rats, we did not find internal hemorrhage. In fact, the reason of rats' death was unclear.

After 7 days, white blood count (WBC) was significantly lower in SHL group as compared to control group ( $P = 0.024$ ) [Table 1]. Moreover, there were no significant differences in C3, C4, IgG, IgA, IgE, and surgery duration [Table 1] between groups. However, IgM was significantly reduced in total splenectomy group.

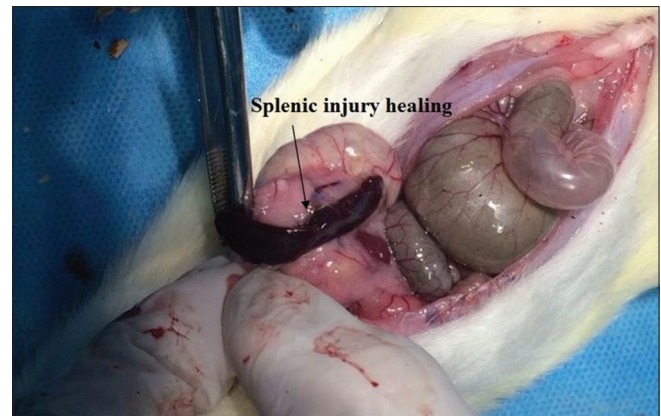In the SHL group, all spleens were viable in second operations [Figure 3]. All variables in peripheral blood smear were significantly lower in SHL group as compared to control group, except Howell–Jolly bodies ( $P = 0.461$ ). The other variables in peripheral blood smear were including anisocyte ( $1.41$  vs.  $3.25 \text{ mm}^{-2}$ ,  $P < 0.001$ ), target cells ( $0.95$  vs.  $2.64 \text{ mm}^{-2}$ ,  $P < 0.001$ ), poikilocyte ( $1.35$  vs.  $3.85 \text{ mm}^{-2}$ ,  $P < 0.001$ ), and schistocyte ( $1.4$  vs.  $3.26 \text{ mm}^{-2}$ ,  $P < 0.001$ ). There was no abscess formation in the SHL group.

Moreover, we found that the bleeding volume in SHL group was significantly lower than control group ( $P < 0.001$ ).

## DISCUSSION

During the past three decades, there have been major changes in the management of traumatic splenic injuries toward splenic preservation procedures. Although nonoperative management is now believed to be the choice treatment in stable patients, however, surgery is necessary for some conditions such as high-grade injuries or in unstable patients. Today, radiological interventions<sup>[11]</sup> such as SAE are performed in many developed countries as an alternative of surgery, but these interventions are not accessible in every centers, and as our review showed most of operative splenic preservations were performed in the past two decades. As radiological intervention is also limited in Iran for splenic trauma, this interventional study can help to preserving the spleen during the surgery.

The short gastric arteries are five to seven small branches arising from splenic artery and passes between the layers



**Figure 3:** In splenic hilum ligation group, all spleens were viable in the second operations

**Table 1: Studied variables in groups**

Variables	Group		P
	Splenic hilum ligation	Total splenectomy	
WBC ( $10^9/L$ )	3.2±0.67	4.07±1.43	0.024
RBC/ $\text{mm}^3$	6.24±0.22	6.14±0.45	0.442
Hb (mg/dl)	12.38±0.5	12.12±0.83	0.25
Hct (%)	35.55±1.13	34.94±2.42	0.333
Platelet/ $\text{mm}^3$	653.15±2.55	749.57±3.71	0.358
C3 (mg/dL)	38.73±6.78	40.94±5.91	0.292
C4 (mg/dL)	4.36±1.45	4.64±1.55	0.578
IgG (pg/ml)	248.31±26.78	265.26±56.69	0.246
IgM (pg/ml)	27±11.4	11.21±10.1	<0.001
IgA (pg/ml)	3.21±0.85	7.47±14.23	0.209
IgE (pg/ml)	28.45±5.45	31.87±6.51	0.088
Anisocyte/ $\text{mm}^2$	1.41±0.46	3.25±0.76	<0.001
Target cells/ $\text{mm}^2$	0.95±0.35	2.64±0.4	<0.001
Poikilocyte/ $\text{mm}^2$	1.35±0.3	3.85±0.51	<0.001
Schistocyte/ $\text{mm}^2$	1.4±0.37	3.26±0.48	<0.001
Howell–Jolly bodies (%)	4 (21.1%)	6 (31.6%)	0.461
Blood volume (cc)	1±0.47	3.15±1.01	<0.001
Surgery duration (min)	18.47±10.68	19.36±1.49	0.72

WBC: White blood cell count, RBC: Red blood cells count, Hb: Hemoglobin, Hct: Hematocrit, Ig: Immunoglobulin

of the gastrolineal ligament to distribute in the greater curvature of the stomach. The upper part of the spleen receives blood directly from the short gastric vessels which have some vascular connection with cardiac branches of the left gastric artery. However, the adequacy of short gastric vessels circulation as the blood supply of whole spleen is in controversy.

In Gürleyik *et al.*<sup>[12]</sup> study, with scintigraphic functional study of devascularized spleen showed that collateral circulation is inadequate for the entire spleen after disconnection of the main blood supply and its function is markedly impaired. They also showed that after reduction of spleen volume, the upper part of the spleen remains well vascularized by the short gastric vessels, with satisfactory activity.



In the year 2000, in following of two patients who had ligation of splenic artery at ages 4 and 2 years in 1977, patients had spleens with normal uptake. Immunoglobulins, complement fraction, antibodies response to vaccinations, and peripheral blood tests were in normal ranges. No Howell-Jolly bodies or side effects were found.<sup>[13]</sup>

In another study performed by Keramidas *et al.*<sup>[14]</sup> revealed 10-year experience in splenic artery ligation in children with splenic injuries. They showed splenic artery ligation was an effective mode of treatment for rare cases of splenic injury unable to be treated nonoperatively or by splenorrhaphy alone. In their study, there were no postoperative complications, and all imaging and immunological status remained undisturbed postoperatively. However, our results showed that IgM increased significantly in the SHL group, but other immunological status remained undisturbed postoperatively.

In another study of Carrapita *et al.*,<sup>[15]</sup> they showed that animals could tolerate the ligation of the splenic artery without complications. Keramidas *et al.*<sup>[16]</sup> showed that 2 months after splenic artery ligation, histology of the spleen showed no abnormalities, and healing of the spleen had been completed. Although the platelets and reticulocytes were temporarily increased, the hematocrit values, WBC counts, serum immunoglobulin M, bone marrow smears, and scintigrams remained within normal levels. These results are in consisting with our results.

Our study showed that short gastric vessels can supply an adequate circulation for small spleens in case of ligation of splenic vessels. According to our results, no significant changes were observed in immunoglobulin subunits except IgM, while we observed a significant reduction in blood smear subunits (target cells, schistocyte, poikilocyte, and anisocyte) except Howell-Jolly bodies in the SHL group.

According to mentioned studies and our results, it seems that splenic artery ligation closely to hilum without splenectomy can be used successfully to control bleeding after blunt injury to the small spleen (e.g. in children). It can be due to fairly extensive collateral blood supply to the spleen.<sup>[17]</sup> It has several benefits for patients, especially reduction in blood smear subunits and bleeding volume.

Platelet activation, hypercoagulability, endothelium activation, and altered lipid profiles are contributing factors of vascular events in splenic trauma and splenectomy.<sup>[4]</sup> Several studies have reported that splenectomy resulted in thrombocytosis, leukocytosis, concentrated hemoglobin, hyperlipidemia, and increased C-reactive protein levels.<sup>[18-22]</sup> However, we found that total splenectomy increased WBC counts significantly and other mentioned side effects did not different between two groups.

We found that just WBC increased significantly in total splenectomy and platelets remains similar between two groups. Moreover, IgM increased significantly in the SHL group. These differences may due to different type of animals, we studied

or may due to different methods. Moreover, in our study, the spleen of rats had small changes in function and appearance based on lower Howell-Jolly bodies and other variables in blood smear. However, several small studies demonstrated the preservation of splenic function after surgical splenic artery ligation based on the absence of Howell-Jolly bodies and normal uptake of technetium-99 on scintigraphy.<sup>[23,24]</sup>

## CONCLUSIONS

Our results showed SHL can be used in the management of traumatic splenic injuries. SHL has been shown to be safe and effective in increasing rates of splenic salvage in rats.

## Acknowledgments

We should thank of the investigators, the coordinators and the Clinical Research Development Units of Isfahan Alzahra Hospital.

## Financial support and sponsorship

Author B has received honoraria from Isfahan University of Medical Sciences, Isfahan, IRAN.

## Conflicts of interest

There are no conflicts of interest.

## REFERENCES

1. Naeem BK, Perveen S, Naeem N, Ahmed T, Khan I, Khan I, *et al.* Visceral injuries in patients with blunt and penetrating abdominal trauma presenting to a tertiary care facility in Karachi, Pakistan. *Cureus* 2018;10:e3604.
2. González-Nicolás Trébo MT, Pérez-Tierra Ruiz J, Miguélena Bobadilla JM. Abdominal injuries treated in a referral hospital: Analysis of outcomes, treatment approaches, and prognostic scales. *Emergencias* 2019;31:15-20.
3. Basaran A, Ozkan S. Evaluation of intra-abdominal solid organ injuries in children. *Acta Biomed* 2019;89:505-12.
4. Karadeniz Cerit K, Ergelen R, Abdullayev T, Tuğtepe H, Dağlı TE, Kiyani G, *et al.* The effectiveness of non-operative treatment in high-grade liver and spleen injury in children. *Ulus Travma Acil Cerrahi Derg* 2018;24:569-74.
5. Stylianos S. To save a child's spleen: 50 years from Toronto to ATOMAC. *J Pediatr Surg* 2019;54:9-15.
6. Freeman C, Moran V, Fang A, Isreal H, Ma S, Vyas K, *et al.* Nonoperative management of blunt splenic trauma: Outcomes of gelfoam embolization of the splenic artery. *J Emerg Trauma Shock* 2018;11:293-7.
7. Loya MF, Mangat S, Santoro GC, Martynov A, Shah SS. Prophylactic absorbable gelatin sponge embolization for angiographically occult splenic hemorrhage. *Radiol Case Rep* 2018;13:753-8.
8. Jambon E, Hocquet A, Petitpierre F, Le Bras Y, Marcelin C, Dubuisson V, *et al.* Proximal embolization of splenic artery in acute trauma: Comparison between penumbra occlusion device versus coils or amplatzer vascular plug. *Diagn Interv Imaging* 2018;99:801-8.
9. Renzulli P, Gross T, Schnüriger B, Schoepfer AM, Inderbitzin D, Exadaktylos AK, *et al.* Management of blunt injuries to the spleen. *Br J Surg* 2010;97:1696-703.
10. Ekeh AP, Khalaf S, Ilyas S, Kauffman S, Walusimbi M, McCarthy MC, *et al.* Complications arising from splenic artery embolization: A review of an 11-year experience. *Am J Surg* 2013;205:250-4.
11. Parihar ML, Kumar A, Gamanagatti S, Bhalla AS, Mishra B, Kumar S, *et al.* Role of splenic artery embolization in management of traumatic splenic injuries: A prospective study. *Indian J Surg* 2013;75:361-7.
12. Gürleyik E, Gürleyik G, Bingöl K, Akkaya L, Unalmişer S. Perfusion and functional anatomy of the splenic remnant supplied by short gastric

- vessels. *Am J Surg* 2000;179:490-3.
13. Keramidas DC, Soutis M. The function of the spleen in adults after ligation of the splenic artery of the traumatized spleen in childhood. *Surgery* 2003;133:583-5.
  14. Keramidas D, Büyükkinal C, Senyüz O, Dolatzas T. Splenic artery ligation: A ten-year experience in the treatment of selected cases of splenic injuries in children. *Jpn J Surg* 1991;21:172-7.
  15. Carrapita J, Abrantes AM, Campelos S, Gonçalves AC, Cardoso D, Sarmento-Ribeiro AB, *et al.* Impact of splenic artery ligation after major hepatectomy on liver function, regeneration and viability. *Sci Rep* 2016;6:34731.
  16. Keramidas DC, Voyatzis N, Anagnostou D, Stavrides J, Koutoulides C, Ziros A, *et al.* Ligation of the splenic artery; effects on the injured spleen and its function. *J Pediatr Surg* 1980;15:38-41.
  17. Song Z, Ye T, Ma L, Shao L, Lin D, Jiang S, *et al.* Splenic artery ligation for iatrogenic injury in esophagectomy operations. *Ann Thorac Surg* 2016;102:e387-8.
  18. Lin JN, Lin CL, Lin MC, Lai CH, Lin HH, Yang CH, *et al.* Increased risk of hemorrhagic and ischemic strokes in patients with splenic injury and splenectomy: A nationwide cohort study. *Medicine (Baltimore)* 2015;94:e1458.
  19. Conti S. Splenic artery ligation for trauma. An alternative to splenectomy. *Am J Surg* 1980;140:444-6.
  20. Hathirat P, Mahaphan W, Chuansumrit A, Pintadit P, Sasanakul W, Isarangkura P, *et al.* Platelet counts in thalassemic children before and after splenectomy. *Southeast Asian J Trop Med Public Health* 1993;24 Suppl 1:213-5.
  21. Boyle S, White RH, Brunson A, Wun T. Splenectomy and the incidence of venous thromboembolism and sepsis in patients with immune thrombocytopenia. *Blood* 2013;121:4782-90.
  22. Crary SE, Buchanan GR. Vascular complications after splenectomy for hematologic disorders. *Blood* 2009;114:2861-8.
  23. Troendle SB, Adix L, Crary SE, Buchanan GR. Laboratory markers of thrombosis risk in children with hereditary spherocytosis. *Pediatr Blood Cancer* 2007;49:781-5.
  24. Goldfarb AW, Rachmilewitz EA, Eisenberg S. Abnormal low and high density lipoproteins in homozygous beta-thalassaemia. *Br J Haematol* 1991;79:481-6.