

## A Woman with Knife *In situ* of Chest

Sayyed Majid Sadrzadeh, Behrang Rezvani Kakhki, Elnaz Vafadar Moradi, Paria Khosravi

Department of Emergency, Faculty of Medicine, Mashhad University of Medical Sciences, Mashhad, Iran

**ORCID:**

Sayyed majid sadrzade: <https://orcid.org/0000-0002-7261-025X>

Behrang Rezvani Kakhki: <https://orcid.org/0000-0003-3715-6618>

Elnaz Vafadar Moradi: <https://orcid.org/0000-0001-9579-7451>

Paria khosravi: <https://orcid.org/0000-0003-2303-3270>

### Abstract

The violence can be physical, psychological or sexual. Physical violence can be by the use of sharp objects. Chest stab wounds with retained penetrating objects are rare. Here, we have reported a case with a knife impaled in her upper back who was treated successfully without any complications. A 35-year-old woman presented to our emergency department with an *in situ* knife at T4–T5 level. Neurologic examination revealed normal and bedside sonography reveals no free fluid in the abdomen, but lung sliding was disrupted on the left hemithorax without evidence of tamponade. A portable chest-x ray showed that the knife passes through an oblique track from right to left. The patient transferred to the operating room and the 50 cm knife removed without traumatic force. Limited thoracotomy with chest tube placement was done. We have reported a case report of an *in situ* knife at the upper back of a young woman who was successfully treated. The patient was stabbed in the upper back due to her husband's violence and the knife passes through an oblique track from right to left without any vascular injury. We stabilized the patient and used bedside sonography as a modality for diagnosis and decision making.

**Keywords:** Stab, violence, wound

### INTRODUCTION

Violence against women is one of the causes of psychological and physical injuries in them.<sup>[1]</sup> The Centers for Disease Control and prevention 2010 National Intimate partner reported 35.6% of intimate partner violence in women's over their lifetimes.<sup>[1]</sup> These violence can be physical, psychological or sexual, physical violence can be by the use of sharp objects.<sup>[1]</sup> Chest stab wounds with retained penetrating objects are rare.<sup>[2]</sup> Here, we have reported a case report of impaled knife in the upper back who was treated successfully without any complications.

### CASE REPORT

A 35-year-old woman presented to our emergency department with multiple stab wound and an *in situ* knife at T4–T5 level. She told that her husbands stabbed her back when she tried to run away. At the time of admission, the blood pressure was 95/65 mmhg, the heart rate was 92 beats/min, the respiratory rate 24/min, and arterial oxygen saturation 94%. The physical

examination revealed a 4 cm stab wound in the second cervical zone without crossing platysma and a 10-cm stab wound in the lateral aspect of the left forearm with evidence of tendon cut. A kitchen knife was seen in the upper back alongside of T4–T5 and the exact location of the tip could not be visualized. Neurologic examination revealed normal and bedside sonography reveals no free fluid in the abdomen, but lung sliding was disrupted on the left hemithorax without evidence of tamponade.

A portable chest X-ray showed that the knife passes through an oblique track from right to left [Figure 1]. The patient transferred to the operating room and the 50 cm knife removed without traumatic force. Limited thoracotomy with

**Address for correspondence:** Dr. Elnaz Vafadar Moradi,  
Department of Emergency Medicine, Imam Reza Hospital, Razi Sq.,  
Mashhad, Iran.  
E-mail: [vafadarme@mums.ac.ir](mailto:vafadarme@mums.ac.ir)

This is an open access journal, and articles are distributed under the terms of the Creative Commons Attribution-NonCommercial-ShareAlike 4.0 License, which allows others to remix, tweak, and build upon the work non-commercially, as long as appropriate credit is given and the new creations are licensed under the identical terms.

**For reprints contact:** [reprints@medknow.com](mailto:reprints@medknow.com)

**How to cite this article:** Sadrzadeh SM, Kakhki BR, Moradi EV, Khosravi P. A woman with knife *In situ* of chest. Arch Trauma Res 2020;9:147-8.

**Received:** 10-05-2020, **Revised:** 30-05-2020

**Accepted:** 06-06-2020, **Published:** 22-08-2020

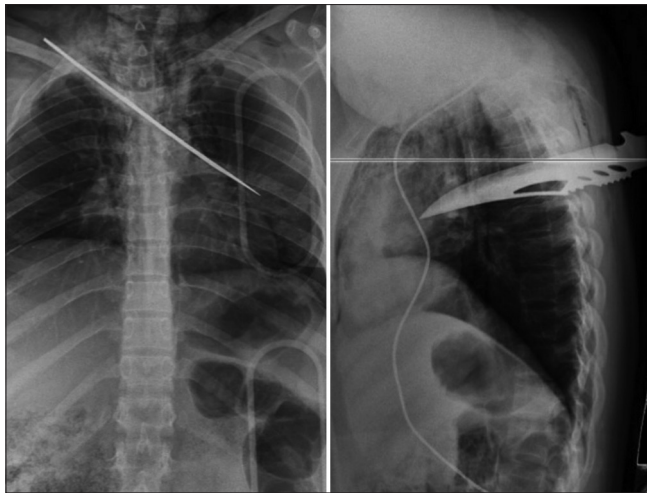
#### Access this article online

Quick Response Code:



**Website:**  
[www.archtrauma.com](http://www.archtrauma.com)

**DOI:**  
10.4103/atr.atr\_35\_20



**Figure 1:** Portal chest X-ray revealed the knife passes oblique track from right to left

chest tube placement was done [Figure 2]. After vascular surgeon consultation, computed tomography angiogram was done which revealed normal. One week later, the left forearm tendons repaired successfully, the patient discharged home after 3 weeks with psychological consultation and without any complication.

## RESULTS AND DISCUSSION

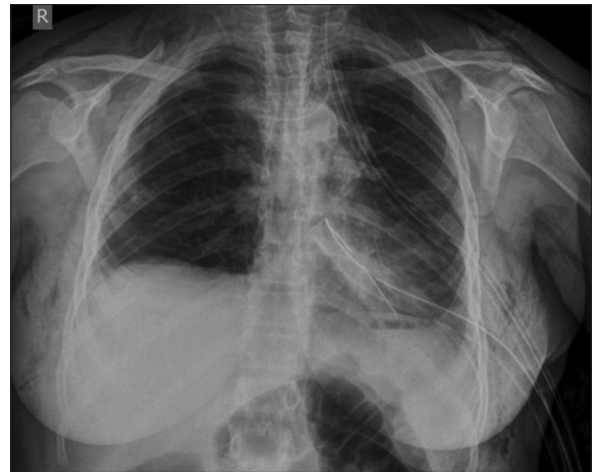
Case of *in situ* knife injuries are rare in the literatures, here we have reported a case report of an *in situ* knife at the upper back of a young woman who was successfully treated. Novakov also reported similar case with thoracic stab wound as suicidal attempts. He was presented with impaled knife in the left hemithorax without pericardium penetration and he was treated without any fatal injury.<sup>[2]</sup> Our patients were stabbed in the upper back by her husband's violence and the knife passes through an oblique track from right to left without any vascular injury.

Agarwal *et al.* have reported a retained blade to the intramedullary spinal cord, who was treated successfully. Their patients have stabbed by serrated knife in the T11–T12 laminar bone.<sup>[3]</sup> Our patients stab wound was near T4–T5 space without insertion into the spinal space or spinal bone injury.

The removal of embedded knives may lead to major bleeding and shock; so, they should remove in the operating room with direct visualization.<sup>[4]</sup> The assessment of other possible injuries should be considered in this patients.<sup>[2]</sup>

## LIMITATION AND CONCLUSION

The case reports of thorax *in-situ* knife was rare, the aim of this report was to present a nonfatal chest stab wound with huge knife *in situ*. We stabilize the patient and used bedside



**Figure 2:** Postoperation chest X-ray with chest tube in the left hemithorax

sonography as a modality for the diagnosis of concurrent tamponade.

## Consent

Before we prepared this manuscript, we informed the patient, and she gave informed consent to publish the manuscript without her name.

## Declaration of patient consent

The authors certify that they have obtained all patient consent forms. In the form, the patient has given her consent for her images and other clinical information to be reported in the journal. The patient understand that name and initials will not be published and due efforts will be made to conceal identity, but anonymity cannot be guaranteed.

## Acknowledgment

This study was performed with the moral support of the research deputy of Mashhad University of Medical Sciences.

## Financial support and sponsorship

Nil.

## Conflicts of interest

There are no conflicts of interest.

## REFERENCES

1. Choo EK, Linden JA. Intimate partner violence and abuse. In: Swadron SP, Gruber PF, editors. *Rosens Emergency Medicine*. 9<sup>th</sup> ed. United State of America: Elsevier Companies; 2018. p. 758-65.
2. Novakov IP. Thoracic stab wound: A curious case report. *Clin Surg* 2018;3:2183.
3. Agarwal P, Burke JF, Abdullah KG, Piazza M, Smith BP, Thawani JP, *et al.* Stab wound to the intramedullary spinal cord: Presurgical and surgical management options for a retained blade to optimize neurological preservation. *Surg Neurol Int* 2016;7:S1096-8.
4. Meer M, Siddiqi A, Morkel JA, Janse van Rensburg P, Zafar S. Knife inflicted penetrating injuries of the maxillofacial region: A descriptive, record-based study. *Injury* 2010;41:77-81.