

Predictors of Pleural Decompression in Blunt Traumatic Occult Hemothorax: A Retrospective Study

Pawit Sriprasit, Osaree Akaraborworn, Nantaka Kiranantawat¹, Jitpreedee Sungsir¹, Chanon Kongkamol²

Departments of Surgery and ¹Radiology, ²Research Unit of Holistic Health and Safety Management in Community, Prince of Songkla University, Hat Yai, Songkhla, Thailand

ORCID:

Pawit Sriprasit: <https://orcid.org/0000-0002-4302-0250>
Osaree Akaraborworn: <https://orcid.org/0000-0002-9343-9498>
Nantaka Kiranantawat: <https://orcid.org/0000-0003-0828-8486>
Jitpreedee Sungsir: <https://orcid.org/0000-0002-5174-4646>
Chanon Kongkamol: <https://orcid.org/0000-0003-3364-0664>

Abstract

Background: The increased use of computed tomography (CT) results in higher occult hemothorax detection in blunt chest trauma. The indication for pleural decompression is not well defined. This research aims to study the overall factors determining pleural decompression. **Methods:** All blunt chest injury patients were retrospectively reviewed from the institutional trauma registry. Patients who underwent chest or whole-abdomen CT within 24 h were reviewed by a radiologist to identify initial occult hemothorax defined as a negative chest X-ray with the presence of hemothorax in the CT. The data included demographic data, mechanism of injury, complications, treatments, and characteristics of the hemothorax from the CT. **Results:** Six hundred and eighty-six blunt chest injury patients were reviewed over a period of 30 months. Eighty-one (24.9%) patients had occult hemothorax. The mean time from injury to CT was 5.7 h. Most patients (87.6%) were male. Most patients (70.2%) suffered from traffic collisions and 84.4% had rib fractures. Pleural decompression was performed in 25 patients who had significantly thicker hemothorax (1.1 cm vs. 0.8 cm, $P < 0.01$), higher rate of occult pneumothorax (88% vs. 53.8%, $P < 0.01$), and lung contusion (44% vs. 15%, $P < 0.05$) than those who did not undergo decompression. Multivariable logistic regression showed that a thickness of hemothorax >1.1 cm was associated with increased risk of pleural decompression (odds ratio [OR]: 5.51, 95% confidence interval [CI]: 1.42–21.42) and occult pneumothorax (OR: 6.93, 95% CI: 1.56–30.77). **Conclusions:** Drainage of occult hemothorax after blunt chest trauma was significantly associated with concomitant occult pneumothorax, lung contusion, and hemothorax thicker than 1.1 cm.

Keywords: Catheter, chest injuries, hemothorax, nonpenetrating, occult hemothorax, thoracostomy

INTRODUCTION

Chest injury is considered one of the most frequent trauma events. Hemothorax is one of the consequences of chest trauma which accounts for 300,000 patients per year in the United States.^[1] Modern trauma care with the increased use of computed tomography (CT) as the initial evaluation has increased the detection of traumatic hemothorax even with small amounts of blood within the pleural cavity. When blood is not seen in the supine chest X-ray (CXR), the condition is called “occult hemothorax.”^[2,3] The incidence of this condition is around 30% of blunt trauma patients.^[4]

The current practice of treating occult hemothorax varies from conservative treatment, percutaneous drainage, and conventional thoracostomy.^[5] Considering the characteristics of an early detected small hemothorax, we can predict the trend of a developing overt hemothorax or other complications following this condition and properly schedule serial imaging

Address for correspondence: Dr. Osaree Akaraborworn, Department of Surgery, Faculty of Medicine, Prince of Songkla University, Hat Yai, Songkhla 90110, Thailand. E-mail: aosaree@gmail.com

This is an open access journal, and articles are distributed under the terms of the Creative Commons Attribution-NonCommercial-ShareAlike 4.0 License, which allows others to remix, tweak, and build upon the work non-commercially, as long as appropriate credit is given and the new creations are licensed under the identical terms.

For reprints contact: reprints@medknow.com

How to cite this article: Sriprasit P, Akaraborworn O, Kiranantawat N, Sungsir J, Kongkamol C. Predictors of pleural decompression in blunt traumatic occult hemothorax: A retrospective study. Arch Trauma Res 2018;7:150-4.

Access this article online

Quick Response Code:



Website:
www.archtrauma.com

DOI:
10.4103/atr.atr_52_18

times and make a decision whether to perform pleural decompression.

Previous studies showed that some significant associated factors determined pleural decompression. The major factor was a hemothorax thickness of >1.5 cm or 2.0 cm. Other factors were a higher Injury Severity Score (ISS), a need for intubation, and the occurrence of occult pneumothorax.^[2-4,6] Some other factors, such as the nature of Asian patients, smaller cut points of blood thickness, and association of other injuries, could affect the outcome of the decision to drain. The aim of this study was to determine the incidence, predicting factors for pleural decompression, treatment, and complications associated with this condition.

METHODS

Study design

This was a retrospective study from a prospectively collected trauma registry from January 2013 to June 2015.

Population and setting

All patients with blunt chest trauma were reviewed from our trauma registry at Songklanagarind Hospital which is on the campus of Prince of Songkla University. The hospital is a Level 1 trauma center in southern Thailand. Blunt chest trauma was defined as chest Abbreviated Injury Score (AIS) ≥ 1 . The number of admitted multiple trauma patients is between 1200 and 1600 per year. The inclusion criteria were age older than 15 years, primary admission in our department, and having a chest or

abdomen CT within 24 h of admission. The excluded patients were those who had a sustained injury >24 h, had previously stated pleural effusion, had undergone pleural drainage before the CT scan, and had incomplete medical records. An occult hemothorax was defined as a hemothorax that was not identified on the initial chest radiograph but was identified on the concurrent thoracic CT. If a thoracic CT was not performed, an abdominal CT was used instead. We considered only hemothorax seen at the time of the initial admission within 24 h according to the inclusion criteria. The presence of blood was seen in the most dependent part of the chest.^[3]

In our institute, the decision to decompress using percutaneous catheter drainage (PCD) is indicated when serial follow-up CXRs reveal overt hemothorax following initial occult hemothorax at admission or the CT chest or abdomen showed lung collapse with effusion. Decompression can be performed with an 8 or 10 Fr PCD catheterization or a 32–36 Fr tube thoracostomy depending on the attending physicians and the availability of radio interventionists.

This retrospective study was approved according to the Declaration of Helsinki by the Human Research Ethics Committee of Faculty of Medicine, Prince of Songkla University (No. 57-296-10-4).

Data collection process

All images of the patients were re-analyzed by a single thoracic radiologist blinded to the clinical data. Images were assessed for the presence of rib fractures, associated chest injury, and

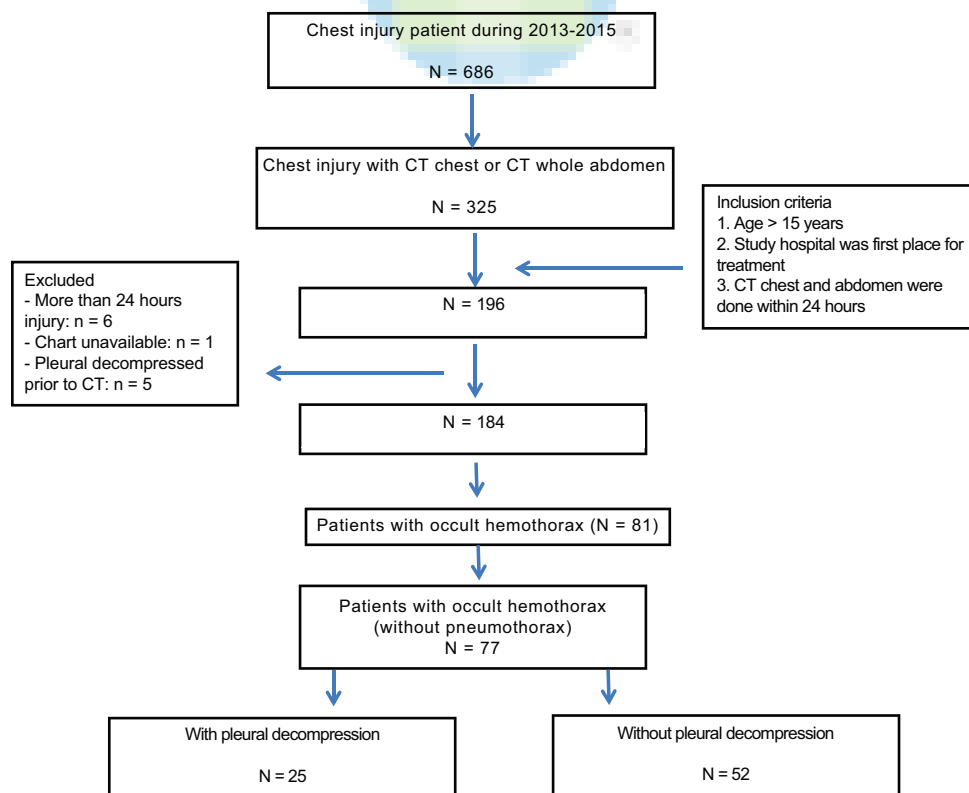


Figure 1: Study recruitment

the presence and maximal thickness of hemothorax. All of the occult hemothorax cases were identified, and all follow-up CXRs were reviewed until the delayed overt hemothorax was detected. Delayed overt hemothorax was defined as hemothorax seen on CXR following the initial occult hemothorax.^[6] Demographic data that included age, sex, ISS, length of stay, mechanism of injury, concurrent thoracic and abdominal injuries, ventilator use, and chest complications were recorded from the trauma registry.

Outcomes

All occult hemothoraces were included to determine associated factors for pleural decompression as an outcome. A pleural decompression could be either conventional intercostal drainage or PCD. The potential factors including mechanism of injury, ISS, presence and number of rib fractures, other chest wall trauma, abdominal trauma, and also delayed hemothorax were compared to see the correlations.

Statistical analysis

The statistical analysis was performed using the Chi-square test and Fisher's exact test for categorical variables. For continuous variables, the *t*-test was used. Multivariable logistic regression was also used for multiple predictor variable analysis. Statistical significance was considered if *P* < 0.05.

RESULTS

During the 30-month study, 686 patients sustained injuries from blunt torso trauma. Figure 1 illustrates the patient flow.

Three hundred and twenty-five patients underwent CT chest or abdomen as the initial evaluation. Eighty-one (24.9%) patients had occult hemothorax. Four patients with pneumothorax were excluded and they received pleural drainage. Sixty-seven patients were male and 10 were female. The percentage of patients who sustained traffic collision injuries was 70.2%. The average age was 48 years. The averages of the ISS and chest AIS were 17.5 and 2.77, respectively. The average CT chest and whole-abdomen time was 5.72 h after injury. Most patients (84.4%) with occult hemothorax had rib fractures. Delayed overt hemothorax occurred in 34 patients with an average time of 4 days. Chest drain insertion was done in 29 patients with an average procedural time of 30 h after injury. Three patients had bilateral hemothoraces, but pleural decompression was performed on the larger sides. The associated injuries are listed in Table 1. Other thoracic cage injuries were found in more than half of the patients. Scapula fracture was found in 28.6%.

After excluding patients with initial pneumothorax that indicated standard pleural decompression treatment, pleural decompression was performed in 25 patients. Compared to the nonintervention group, those with pleural decompression had a significantly higher rate of occult pneumothorax (88% vs. 53.8%, *P* < 0.01), higher rate of lung contusion (44% vs. 15%, *P* = 0.014), and thicker hemothorax by imaging (1.1 cm vs. 0.8 cm, *P* < 0.01). Multivariable logistic regression showed an increased risk for pleural decompression with

Table 1: Demographic data and factors associated pleural decompression

Demographic data	Total	No pleural decompression (n=52)	Pleural decompression (n=25)	P
Age (year), mean (SD)	48.42 (17.86)	49.3	46.7	0.555
Gender (male: female)	67:10	45:7	22:3	1
Injury to CT time (h), median (IQR)	5.72 (7.06)	3.8 (2.5-6.6)	3 (2.2-4.5)	0.199
Mechanism of injury (%)				
Road traffic accident	54 (70.2)	37 (71.1)	17 (68)	0.327
Fall	20 (26)	13 (25)	7 (28)	
Other	3 (3.8)	2 (3.8)	1 (4)	
ISS, median (IQR)	17.506 (9.61)	15.5 (12.8-19.8)	14 (9-7)	0.521
Chest AIS, median (IQR)	2.773 (0.48)	3 (3-3)	3 (3-3)	0.779
Intubation (%)	7 (9.09)	5 (9.6)	2 (8)	1
Rib fractures	65 (84.4)	42 (80.8)	23 (92)	0.317
Maximum number of fractures (ribs), mean (SD)	3.859 (2.13)	3.5 (2)	4.5 (2.4)	0.07
Occult pneumothorax (%)	50 (64.9)	28 (53.8)	22 (88)	0.007
Lung contusion (%)	19 (24.7)	8 (15)	11 (44)	0.014
Occult hemothorax thickness (cm), median (IQR)	0.941 (0.54)	0.8 (0.5-1)	1.1 (0.7-1.7)	0.007
HU, mean (SD)	29.56 (16.63)	29.5 (16.9)	32.2 (13.9)	0.491
Concomitant thoracic injury (%)	42 (54.5)			
Scapula	22 (28.6)	24 (46.2)	18 (72)	0.059
Clavicle	17 (22.1)			
Concomitant abdominal injury (%)	14 (18.2)			
Liver	9 (9.2)	11 (21.1)	3 (12)	0.529
Spleen	8 (10.4)			
Others	3 (3.9)			

ISS: Injury Severity Score, AIS: Abbreviated Injury Score, HU: Hounsfield unit, SD: Standard deviation, IQR: Interquartile range, CT: Computed tomography

Table 2: Logistic regression prediction of pleural decompression

Pleural decompression	Crude OR (95% CI)	Adjusted OR (95% CI)	P (LR test)
Thickness >1.1 cm	4.6 (1.4-15.06)	5.51 (1.42-21.42)	0.01
Occult pneumothorax	6 (1.59-22.62)	6.93 (1.56-30.77)	0.04
Lung contusion	3.93 (1.3-11.89)	3.33 (1-11.15)	0.049

OR: Odds ratio, CI: Confidence interval, LR: Likelihood ratio

Table 3: Delayed hemothorax associations

Delayed hemothorax	Presence (n=34)	Not (n=43)	P
Thickness (cm), median (IQR)	0.7 (0.5-1.1)	0.9 (0.6-1.2)	0.387
Maximum fractures number (ribs), median (IQR)	4 (2.8-6)	3 (2-5)	0.238
Mechanical ventilator (%)	1 (2.9)	6 (13.9)	0.126

IQR: Interquartile range

a hemothorax >1.1 cm in thickness (odds ratio [OR]: 5.51, 95% confidence interval [CI]: 1.42–21.42; $P < 0.01$), presence of occult pneumothorax (OR: 6.93, 95% CI: 1.56–30.77; $P < 0.05$), and lung contusion (OR: 3.33, 95% CI: 1.11–11.15; $P < 0.05$) [Table 2]. However, in patients with delayed hemothorax, there was no significant difference, and they tended to have thicker hemothorax, more rib fractures, and greater need for mechanical ventilation [Table 3].

Out of 25 patients with pleural decompression, 4 had PCD and 21 had intercostal chest drainage. One case appeared with occult hemothorax but turned into massive hemorrhage intraoperatively within 12 h and underwent thoracotomy. Only 3 complications of chest drainage occurred: 2 misplaced tubes and 1 recurrent pneumothorax.

DISCUSSION

The results of the study showed that occult hemothorax is a frequently detected condition in trauma care and can be found within a few hours after injury. Tube thoracostomy was performed in one-third of these patients and tended to be associated with the presence of occult pneumothorax and thick occult hemothorax. Half of the patients developed overt hemothorax and half of the patients underwent pleural decompression. The general indications for chest tube insertion were obvious traumatic hemothorax from CXR, traumatic hemothorax with dyspnea, or hypotension with possible massive hemothorax. However, for occult hemothorax, the indication has not yet been established in our institute.

Our study showed that the incidence of occult hemothorax was 24.9% which was slightly lower than a previous study by Poole *et al.*^[7] that reported occult hemothorax in 30% of only 67 thoracic trauma patients who had a chest injury score > 2 while our study population included all patients who presented with chest injury which increased the various degrees of chest

injury. Another study by Stafford *et al.*^[3] excluded all patients without a thoracic CT which resulted in an incidence of 20% of blunt thoracic injury patients. The rates of patients with thoracic trauma who underwent CT scan were not definitely identified in all previous studies. The true incidence of the occult hemothorax may be higher, but our study only included patients with a possible diagnosis based on the initial CT scan; therefore, it possibly caused an underestimation. Only half of our blunt chest trauma patients underwent a CT scan.

For the treatment of occult hemothorax, our study showed that 32% of the overall patients underwent pleural decompression, excluding those four patients with initial occult pneumothorax that was drained after CT scan. A previous study showed a higher rate of chest tube insertion with routine chest and abdominopelvic CT.^[8] However, patients with a chest drain characteristically have other associated thoracic injuries.^[4] Previous studies showed that an occult hemothorax thickness of 1.5 cm was significant which was similar to our study with a mean cut point thickness of 1.1 cm.^[2,4] The difference is possibly explained by the difference in the body sizes between our population and the previous studies. Almost all patients in our study were Asian while the previous studies were Caucasian.

The rate of turning to overt hemothorax in our study was 5% which was comparable to 7.2% from a previous study. Our study considered only hospitalized patients. Therefore, the true incidence could be higher compared to a previous study that also included outpatient management with delayed hemothorax.^[6] Our study did not define delayed hemothorax as a hemothorax that occurred after one or more days as defined in the study by Misthos *et al.*^[6] Instead, we used the term “delayed overt hemothorax” to denote any change from the initial investigation and whenever hemothorax was detected. However, we still found that these patients developed overt hemothorax in an average of 4 days after the normal CXR which corresponded with a previous study that reported overt hemothorax after 48 h. Based on the published studies, the same characteristic of delayed hemothorax could be its natural history of disease which suggests that the accumulation of blood takes at least 48 h. Only a small number of complications were found to be consistent with previously reported incidences.^[5,9]

This study has some limitations. First, the study has a small number of patients in a short study period. Second, the reasoning for pleural drainage was not available from the medical records and also there were no guidelines for chest tube insertion in occult hemothorax in our institute which probably caused a higher rate of chest tube insertion. This issue still requires a prospective study to address the nature of disease progression and critical decision for these conditions. Furthermore, a clear-cut guideline for occult hemothorax management should be established within the institute. However, the strength of this study is that all imaging was

reviewed by a thoracic radiologist for definite identification of occult hemothorax.

CONCLUSIONS

Hemothorax thicker than 1.1 cm accompanied by occult pneumothorax and lung contusion was significantly associated with chest tube drainage of occult hemothorax in patients after blunt chest trauma.

Financial support and sponsorship

Nil.

Conflicts of interest

There are no conflicts of interest.

REFERENCES

1. Khandhar SJ, Johnson SB, Calhoon JH. Overview of thoracic trauma in the United States. *Thorac Surg Clin* 2007;17:1-9.
2. Bilello JF, Davis JW, Lemaster DM. Occult traumatic hemothorax: When can sleeping dogs lie? *Am J Surg* 2005;190:841-4.
3. Stafford RE, Linn J, Washington L. Incidence and management of occult hemothoraces. *Am J Surg* 2006;192:722-6.
4. Mahmood I, Abdelrahman H, Al-Hassani A, Nabir S, Sebastian M, Maul K. Clinical management of occult hemothorax: A prospective study of 81 patients. *Am J Surg* 2011;201:766-9.
5. Deneuve M. Morbidity of percutaneous tube thoracostomy in trauma patients. *Eur J Cardiothorac Surg* 2002;22:673-8.
6. Misthos P, Kakaris S, Sepsas E, Athanassiadi K, Skottis I. A prospective analysis of occult pneumothorax, delayed pneumothorax and delayed hemothorax after minor blunt thoracic trauma. *Eur J Cardiothorac Surg* 2004;25:859-64.
7. Poole GV, Morgan DB, Cranston PE, Muakkassa FF, Griswold JA. Computed tomography in the management of blunt thoracic trauma. *J Trauma* 1993;35:296-300.
8. Moussavi N, Ghani H, Davoodabadi A, Atoof F, Moravveji A, Saidfar S, *et al.* Routine versus selective chest and abdominopelvic CT-scan in conscious blunt trauma patients: A randomized controlled study. *Eur J Trauma Emerg Surg* 2018;44:9-14.
9. Menger R, Telford G, Kim P, Bergey MR, Foreman J, Sarani B, *et al.* Complications following thoracic trauma managed with tube thoracostomy. *Injury* 2012;43:46-50.

