

Wandering Spleen in an Adult Man Associated With the Horseshoe Kidney

Mohammadreza Memari¹, Mohsen Nikzad², Hossein Nikzad^{3,*}, Aliakbar Taherian³

¹Najafabad Azad University, Najafabad, IR Iran

²Faculty of Medicine, Kashan University of Medical Sciences, Kashan, IR Iran

³Anatomical Sciences Research Center, Kashan University of Medical Sciences, Kashan, IR Iran

*Corresponding author: Hossein Nikzad, Anatomical Sciences Research Center, Kashan University of Medical Sciences, Kashan, IR Iran. Tel: +98-3615550480, Fax: +98-3615550480, E-mail: nikzad_h@kaums.ac.ir

Received: November 28, 2012; **Revised:** May 20, 2013; **Accepted:** May 29, 2013

Introduction: A wandering spleen occurs when there is a laxity of the ligaments that fix the spleen in its normal anatomical position.

Case Presentation: This is a case report of a wandering spleen with horseshoe kidney in a 29-year-old male admitted with acute lower abdominal pain and vomiting to emergency department of Shariati hospital in Isfahan province. Sonographic examination showed a homogeneous 21 × 15 × 8 cm mass in the lower part of the abdomen and pelvis associated with a horseshoe kidney. Laparotomy confirmed the clinical and ultrasound findings.

Conclusions: The association of horseshoe kidney with a wandering spleen in this case may be due to an embryological anomaly.

Keywords: Adult; Horseshoe Kidney; Splenectomy; Wandering Spleen

1. Introduction

Wandering spleen is displacement of the spleen from its normal location due to a loss or weakening of ligaments that hold the spleen in the left upper quadrant (1). Van Horne described the first case report of wandering spleen in 1667, while performing an autopsy (2). The real incidence of wandering spleen is unknown, as up to 50% of the cases remain asymptomatic. Wandering spleen is a rare entity, with a reported incidence less than 0.2% and accounts for only 2 per 1000 splenectomies and has a female predominance (3-5). Due to the long and mobile nature of the vascular pedicle, the possibility for torsion of the spleen is high. Generally, causes are asymptomatic. In delayed diagnosis situations, as a result of development of vascular congestion associated with chronic torsion, symptoms of splenomegaly, left portal hypertension, gastric fundal varices, pancreatitis and hypersplenism may emerge (6, 7).

2. Case Presentation

A 29-year-old man with acute lower abdominal pain and vomiting was admitted to the emergency department of Shariati hospital in Isfahan province. The physical examination revealed that there is a large tender and mobile mass in hypogastric region. An abdominal distension was noticed too (Figure 1A).

He was afebrile (36.9°C) with normal blood pressure (123/82 mm Hg) but with tachycardic (112 beats per min-

ute). White blood cell count, hemoglobin level, platelets count and urinary analysis were normal. A plain abdominal radiographic examination showed marked colonic gaseous distension present in the left upper quadrant.

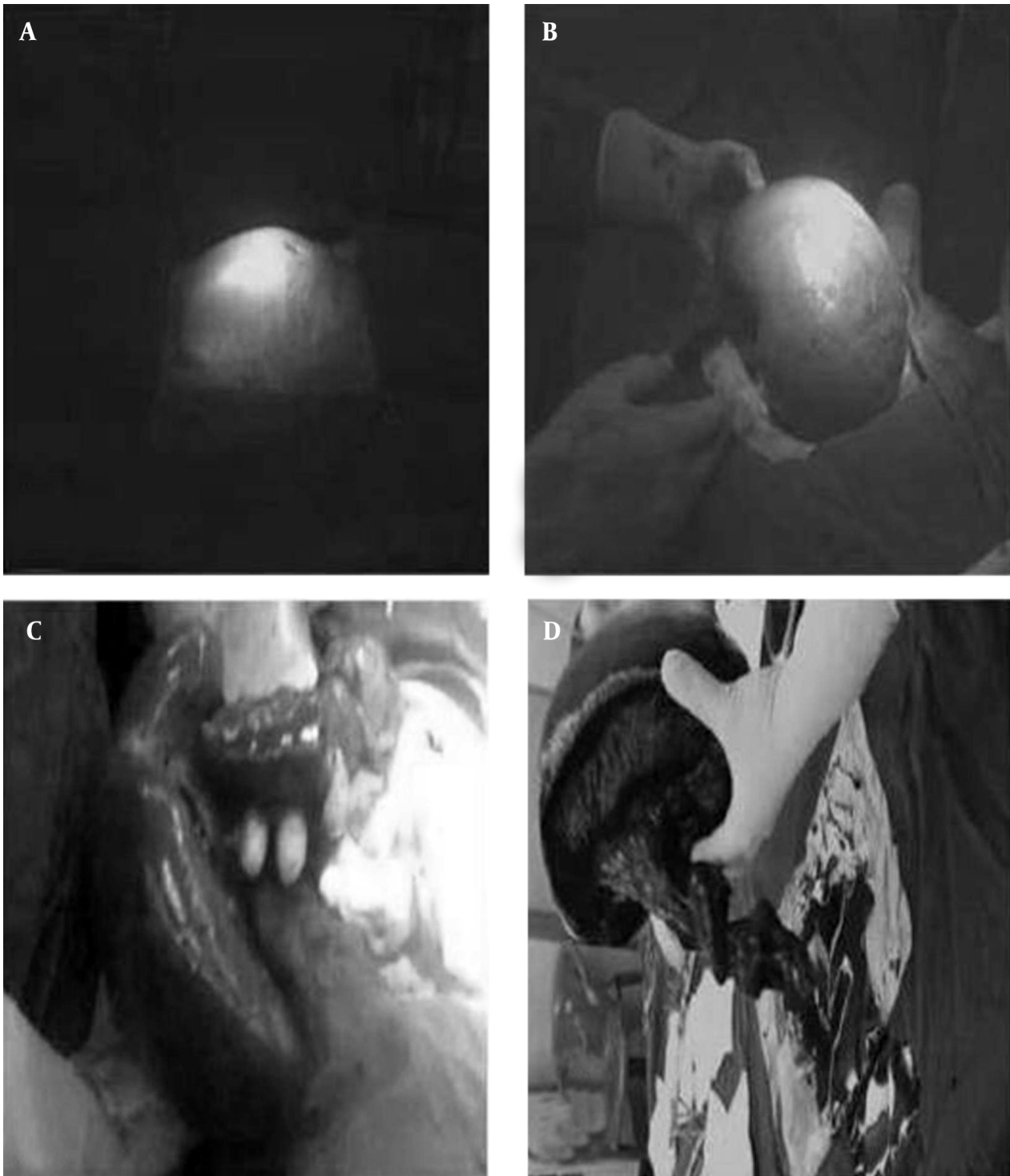
Sonographic examination showed a homogeneous 21 × 15 × 8 cm mass in the lower part of the abdomen and pelvis with echogenicity that was consistent with normal spleen tissue while the normal splenic bed in the left upper abdomen was empty. The left kidney was atrophic measuring 85 mm in length which is showing increased parenchymal echogenicity. Right kidney was also enlarged to 129 mm in length. The lower poles of both kidneys were deviated medially suggesting a horseshoe kidney. No sign of hydronephrosis or stone was detected in the kidneys. Laparotomy examination confirmed the clinical and ultrasound findings. The enlarged spleen mass in the lower part of the abdomen and pelvis had a 720 degree torsion around a 25-cm long splenic pedicle with a horseshoe kidney. The spleen had no holding ligaments. Although a detorsion of the spleen was attempted, there was no success since the pedicle had become fibrotic. There were varicose dilatations in the veins surrounding the pedicle of the spleen. The splenic artery was double tied and excised. Then the splenectomy completed by double tying and excising the vein as well. The excised spleen had 843 g weight. (Figure 1B, C, D). The patient had no additional problems during the follow-up period and was discharged three days later.

Implication for health policy/practice/research/medical education:

No specific implication has been declared.

Copyright © 2013, Kashan University of Medical Sciences; Published by Kowsar Corp. This is an open-access article distributed under the terms of the Creative Commons Attribution License, which permits unrestricted use, distribution, and reproduction in any medium, provided the original work is properly cited.

Figure 1. Photograph Taken During Splenectomy



A) Distension of abdomen in hypogastric region; B) An enlarged spleen; C) Varicose dilatations in the veins; D) Long splenic pedicle.

3. Discussion

This was the first report on a wandering spleen associated with horseshoe kidney in an adult man. Embryo-

logically, the spleen originates from the mesenchymal remnant of the dorsal mesogastrium at the left upper quadrant of the abdomen. During this process, the spleen

establishes its peritoneal connections with the left kidney and stomach by the splenorenal and gastrosplenic ligaments (8). When these ligaments are congenitally absent or abnormally elongated, the spleen becomes wanderlust. This condition has been described as wandering spleen, floating spleen, or splenic ptosis (9, 10).

Van Horne described a case of wandering spleen for the first time in 1667 while performing an autopsy (2). The cause of this phenomena is not precisely known, but the most common cause appears to be a failure of fusion of the dorsal mesogastrium during the fifth and sixth week of development resulting in an unusually long splenic pedicle (10). Wandering spleen has also been seen in some disorders where there is failure of foregut rotation and fusion of the dorsal mesogastrium, such as prune-belly syndrome (11, 12). Other causes of wandering spleen include postpartum laxity, splenomegaly, previous abdominal trauma, poor abdominal tone and surgery (13-15). The wandering spleen is mostly found in children and in women of reproductive age (16, 17). The wandering spleen in our report is of an adult man and might be due to an embryonic anomaly, splenomegaly or post traumatic condition.

Clinically, patients may present with normal complaints, such as occasional nausea, vomiting or mild cramp-like pain due to splenic congestion or intermittent torsion and spontaneous detorsion (6, 7). Because of these nonspecific symptoms, preoperative diagnosis of wandering spleen is rarely suggested based on clinical findings alone. Therefore, imaging methods such as plain radiography, sonography, Doppler sonography, computed tomography, and MRI may play a major role in establishing the diagnosis (18-23).

Surgical treatments include splenectomy and splenopexy. For many years, the preferred treatment was to remove the spleen surgically, initially by conventional laparotomy and more recently by laparoscopy (24). The first successful splenectomy for a wandering spleen was in 1878 by Martin and marked the beginning of surgical treatment for this condition (25). Rydygier described the first successful splenopexies using various techniques and from 1890 to 1920, most authors advocated splenopexy for the treatment of this condition (26-29). Splenectomy is done if there is functional asplenia due to torsion, splenic infarction, splenic vessel thrombosis or any suspicion of malignancy. Conversely, splenopexy is preferred when a viable wandering spleen is found at laparotomy. Splenic preservation is especially recommended in extremely young patients who are at particular risk for postsplenectomy sepsis (30). This can be performed by forming a retroperitoneal pouch in which the spleen is placed, or by inserting a Prolene or Vicryl bag that is fashioned around it and secured in the left upper quadrant (31, 32).

The wandering spleen usually is located in an anterior abdominal position and is more exposed to an abdominal impact in accidents. On the other hand, it should not

be denied that misplaced spleen sometimes can be the possible reason behind wrong diagnosis in cases that experience traumatic injuries. Wandering spleen is also at risk of iatrogenic traumatic injuries during surgical or endoscopic manipulation of the colon, stomach, pancreas and other abdominal organs in such cases. An increased awareness of this condition may help in reducing the incidence of mortality in emergency departments.

Acknowledgements

None declared.

Authors' Contribution

None declared.

Financial Disclosure

There is no competing interests/support by any grants from any sources in this report.

Funding/Support

None declared.

References

- Liu HT, Lau KK. Wandering spleen: an unusual association with gastric volvulus. *AJR Am J Roentgenol.* 2007;**188**(4):W328-30.
- Padilla David, Ramia JoseManuel, Martin Jesus, Pardo Ricardo, Cubo Teofilo, Hernandez-Calvo Jose. Acute abdomen due to spontaneous torsion of an accessory spleen. *Am J Emerg Med.* 1999;**17**(4):429-30.
- Mayo WJ. A Review of 500 Splenectomies with Special Reference to Mortality and End Results. *Ann Surg.* 1928;**88**(3):409-15.
- Whipple AO. The Medical-Surgical Splenopathies. *Bull N Y Acad Med.* 1939;**15**(3):174-6.
- Fujiwara T, Takehara Y, Isoda H, Ichijo K, Tooyama N, Kodaira N, et al. Torsion of the wandering spleen: CT and angiographic appearance. *J Comput Assist Tomogr.* 1995;**19**(1):84-6.
- Herman TE, Siegel MJ. CT of acute splenic torsion in children with wandering spleen. *AJR Am J Roentgenol.* 1991;**156**(1):151-3.
- Moran JosephC, Shah Udayan, Singer JohnA. Spontaneous rupture of a wandering spleen: case report and literature review. *Curr Surg.* 2003;**60**(3):310-2.
- Moore KL, Persaud TVN. The digestive system. In: Moore KL, Persaud TVN, editors. *The Developing Human, Clinically Oriented Embryology.* 6th ed. Philadelphia, PA: WB Saunders Co.; 1998. p. 271-302.
- Abell I. Wandering Spleen with Torsion of the Pedicle. *Ann Surg.* 1933;**98**(4):722-35.
- Lott HS. Case of floating spleen with twisted pedicle, celiotomy, splenectomy, recovery. *Am J Obstet.* 1912;**66**:985-6.
- Aliabadi Hossein, Foker John, Gonzalez Ricardo. Splenic torsion and the prune belly syndrome. *Ped Surg Intl.* 1987;**2**(6):369-71.
- Teramoto Roy, Opas LawrenceM, Andrassy Richard. Splenic torsion with prune belly syndrome. *J pediatrics.* 1981;**98**(1):91-2.
- Gilman RachelS, Thomas RonaldL. Wandering spleen presenting as acute pancreatitis in pregnancy. *Obstet Gynecol.* 2003;**101**(5, Part 2):1100-2.
- Koppikar MG, Vaze AM, Bapat RD. Wandering spleen. *J Postgrad Med.* 1981;**27**(1):42-3.
- Peitgen K, Schweden K. Management of intermittent splenic torsion ("wandering spleen"): a review. *Eur J Surg.* 1995;**161**(1):49-52.
- Cohen MS, Soper NJ, Underwood RA, Quasebarth M, Brunt LM. Laparoscopic splenopexy for wandering (pelvic) spleen. *Surg Laparosc Endosc.* 1998;**8**(4):286-90.

17. Ben Ely A, Segquier E, Lotan G, Strauss S, Gayer G. Familial wandering spleen: a first instance. *J Pediatr Surg*. 2008;**43**(5):E23-5.
18. Chawla S, Boal DK, Dillon PW, Grenko RT. Splenic torsion. *RadioGraphics*. 2003;**23**(2):305-8.
19. Deux JF, Salomon L, Barrier A, Callard P, Bazot M. Acute torsion of wandering spleen: MRI findings. *Am J Roentgenol*. 2004;**182**(6):1607-8.
20. Ityel H, Granot Y, Vaknine H, Judich A, Shimonov M. Splenic torsion of a wandering spleen. *Isr Med Assoc J*. 2011;**13**(2):119-20.
21. Karmazyn B, Steinberg R, Gayer G, Grozovski S, Freud E, Kornreich L. Wandering spleen—the challenge of ultrasound diagnosis: report of 7 cases. *J Clin Ultrasound*. 2005;**33**(9):433-8.
22. Matsumoto S, Mori H, Okino Y, Tomonari K, Yamada Y, Kiyosue H. Computed tomographic imaging of abdominal volvulus: pictorial essay. *Can Assoc Radiol J*. 2004;**55**(5):297-303.
23. Taori K, Ghonge N, Prakash A. Wandering spleen with torsion of vascular pedicle: early diagnosis with multiplaner reformation technique of multislice spiral CT. *Abdom Imaging*. 2004;**29**(4):479-81.
24. Rosin D, Bank I, Gayer G, Rimon U, Gur D, Kuriansky Y, et al. Laparoscopic splenectomy for torsion of wandering spleen associated with celiac axis occlusion. *Surg Endosc*. 2002;**16**(7):1110.
25. A. Martin. A Successful Case of Splenotomy. *BMJ*. 1878;**1**(893):191-192.
26. Rydygier D. Die Behandlung der Wandermilz durchsplenopexis. *Arch Klin Chir*. 1895;**50**:880-6.
27. Plucker P. Uber Splenopexis bei wandermilz. *Centr Bl Chir*. 1885;**40**:905-7.
28. Robinson AP. Wandering spleen: case report and review. *Mt Sinai J Med*. 1988;**55**(5):428-34.
29. Stringel Gustavo, Soucy Pierre, Mercer Stanley. Torsion of the wandering spleen: Splenectomy or splenopexy. *J Pediatr Surg*. 1982;**17**(4):373-5.
30. Buehner M, Baker MS. The wandering spleen. *Surg Gynecol Obstet*. 1992;**175**(4):373-87.
31. Lane TM, South LM. Management of a wandering spleen. *J R Soc Med*. 1999;**92**(2):84-5.
32. Cavazos S, Ratzler ER, Fenoglio ME. Laparoscopic management of the wandering spleen. *J Laparoendosc Adv Surg Tech A*. 2004;**14**(4):227-9.