



Functional and radiological outcome of proximal tibia fractures managed with Ilizarov technique with or without minimal internal fixation

Gandhi Ketankumar ¹, Joshi Satyen ¹, Pangavane Sandip ¹, Meher Akshaya ^{2*}, Vishal Patil ¹

¹ Department of Orthopaedics, Dr. Vasant Rao Pawar Medical College, Hospital and Research Centre, Nashik, Maharashtra, India

² Central Research Laboratory, Dr. Vasant Rao Pawar Medical College, Hospital and Research Centre, Nashik, Maharashtra, India

* **Corresponding author:** Meher Akshaya. Central Research Laboratory, Dr. Vasant Rao Pawar Medical College, Hospital and Research Centre, Nashik, Maharashtra, India. **Email:** akshu.biotech@gmail.com

Received: 8 November 2023 **Revised:** 16 December 2023 **Accepted:** 25 March 2024 **e-Published:** 29 March 2024

Abstract

Background: Proximal tibia fractures are often accompanied by extensive soft tissue injuries, which lead to frequent post-operative complications like wound dehiscence, infection, and non-union. In such injuries, there is a need for anatomical reduction and stable fixation for a good surgical outcome. The surgical procedures involving internal fixation have increased the complication rate of such fractures. Ilizarov ring fixation can provide stable fixation, does not need extensive soft tissue dissection, and encourages early mobilization.

Objectives: This study aimed to assess the functional and radiological outcome of proximal tibia fractures managed with Ilizarov technique with or without minimal internal fixation.

Methods: 35 patients with either intra-articular as well as extra-articular proximal tibia fractures between January 2018 and May 2022 were included in this study. All the included patients were operated on using Ilizarov technique. The functional outcome was assessed using the Modified Rasmussen Criteria for clinical assessment, and the radiological outcome by Modified Rasmussen Criteria for radiological assessment.

Results: All patients achieved radiological union at a mean duration of 16 weeks. Full weight-bearing was also allowed at a mean of 12 weeks. Functional results were excellent in 22 cases, good in 12 cases and poor in one. Most patients achieved functional range of motion at the knee joint (average flexion 128°) except one, who had a flexion of less than 110°. Axial malalignment of less than 10° was seen in 4 cases, and articular step of less than 5 mm was seen in 2 cases.

Conclusion: Ilizarov ring fixation is an excellent method of fixation in proximal tibia fractures, both extra-articular and intra-articular. It gives stable fixation, encourages early mobilization, has a higher union rate, and prevents damage to the soft tissue envelope, which is often compromised in such fractures.

Keywords: Extra articular proximal tibia fractures, Intra articular proximal tibia fractures, Ilizarov ring fixation.

Introduction

Proximal tibia fractures are one of the commonest fractures seen worldwide. High energy trauma leading to proximal tibia fractures are often associated with extensive soft tissue injuries, articular depression, condylar comminution and diphyseal involvement.^[1-3] Such injuries are seen in the form of swelling, degloving and blistering.^[4] Moreover, there is high incidence of associated open fractures, contamination and compartment syndrome.^[5]

Intra articular proximal tibia fractures are classified using the Schatzkers classification, which subdivides these fractures into six types.^[6] Arbeitsgemeinschaft für Osteosynthesefragen (AO) classification of proximal tibia fractures takes into account intra as well as extra articular fractures.^[7] Tscherné classification is used for the extent of soft tissue injuries associated with these fractures.^[8]

Conventional treatment protocol in such injuries is to wait till the soft tissue permits or apply an external fixator and then perform open reduction and internal fixation.^[9-11]

This approach usually exposes patients to multiple surgeries in the form of the external fixator first, followed by internal fixation in the second sitting. Even after taking the utmost precautions, these surgeries are associated with high incidence of complications in the form of wound dehiscence, infection and non-union.^[12] Primary issue in such fractures is whether soft tissue envelope overlying the fractured bone is able to tolerate further injuries caused by open reduction and internal fixation.^[13] Ilizarov ring fixation is a promising tool in such fractures as it can fix the fracture with significantly less damage to the soft tissues as compared to open reduction and internal fixation. It provides stable fixation for early mobilization of the patients. It is modular as finer re-adjustments in bone alignment can be done on an out-patient basis without the need for anaesthesia. As external fixation with a ring fixator is the definitive fixation, a single surgery achieves the surgeon's goal of preventing further soft tissue insults as well as achieving a stable fracture fixation. Hence, Ilizarov ring fixation could provide a better option for internal fixation in proximal tibia fractures with bad soft tissue injuries.

Several studies carried out worldwide have reported the good functional and radiological outcomes of Ilizarov ring fixation in the treatment of Schatzker type V and VI tibial plateau fractures.^[14-17] However, osteosynthesis by means of open reduction and internal fixation using locking plates is widely performed surgery in Indian population. Few studies carried out in the Indian population have shown the Ilizarov fixator to be a safe way to fix proximal tissue fractures with minimal complications of the soft tissue and early weight bearing.^[18-22] Thus, the prospects of Ilizarov ring fixation needs to be explored more in order to overcome the limitations of conventional methods of surgery to treat proximal tibia fractures.

Objectives

This study aimed to investigate the functional and radiological outcome of proximal tibia fractures managed with Ilizarov technique with or without minimal internal fixation.

Methods

The current study was carried out at the Department of Orthopaedics, Dr. Vasantrao Pawar Medical College, Nashik. All cases operated with the Ilizarov technique between January 2018 and May 2022 are included in the study. All patients aged between 18 and 65 years with intra-articular and extra-articular proximal tibia fractures were included in the study. Patients with neurovascular

injuries, with associated same-side femur fractures and any other systemic injuries, with compartment syndrome, and patients with intra-articular and extra-articular proximal tibia fractures operated using methods other than the Ilizarov technique were excluded from the study.

From the medical records, patients with extra-articular and intra-articular proximal tibia fractures from January 2018 to May 2022 were identified. Fracture patterns were classified as per the Schatzker classification^[23] and AO/OTA Classification,^[24] while the Tscherne classification^[25] was used to classify the soft tissue injury. Those patients who were operated on by Ilizarov ring fixator were included in the study. All the patients included in the study had extra articular (AO/OTA Classification) and type V/type VI intra articular proximal tibia fractures (Schatzker classification) with grade 2 and grade 3 category of soft tissue injury (Tscherne classification). Details of patients like gender, age, mode of injury, type of fracture, open or closed fracture, and time from injury to surgical intervention were noted pre-operatively from the medical records and through telephonic follow-ups. Preoperative and surgical management in these patients was as follows:

Preoperative Management

Pre-operative management was performed as per standard guidelines.^[26] Patients with intra-articular and extra-articular proximal tibia fractures were primarily immobilized with a posterior slab in the emergency room. Radiological evaluation was done by obtaining radiographs of the knee joint. In order to better understand the fracture morphology in some cases of intra-articular fracture patterns, a CT scan was done. Limb elevation and ice application were advised as edema control measures. Soft tissue status was assessed and classified according to Tscherne classification. Prophylactic antibiotics were started as per standard protocol for open fractures in cases of open injuries.

Patients were explained in detail about the nature of the injury, options for treatment (internal fixation with open reduction as compared to external Ilizarov ring fixation), and the advantages and disadvantages of each method of fixation.

Surgical Procedure

The surgical procedure was performed as per the standard guidelines.^[27] All patients were operated on in supine position under spinal anaesthesia. The operative leg was given traction using traction table attachments or calcaneal skeletal traction. The injured limb was painted and draped as per standard protocols, and the fracture pattern was assessed again using IITV control. Articular

reduction was assessed, and, if required, minimal open reduction was performed with small incisions along with the application of reduction clamps. Cannulated cancellous screws were used to achieve articular reduction in a few cases. If joint depression is present, a small cortical window was made at an appropriate location, and bone punches were used to elevate the depressed fragment.

Three ring Ilizarov construct was usually used to fix the fracture. First ring is juxta articular, at least 6 to 8 mm below the knee joint line, to prevent wires from piercing the synovial membrane. Olive wires were used for interfragmentary compression. Drop wires or Schanz pins were used for additional stability as per the fracture configuration. A second ring with two wires, with or without a Schanz pin, was placed immediately below the fracture line. The third ring was placed in the supra-malleolar region. Four rings were needed in a few cases of type VI Schatzker fracture patterns where diaphyseal extension of the fracture needed one extra ring for adequate reduction and fixation of the fragments as per the preference of the surgeon. Knee-spanning fixator configuration was applied in cases of severe articular comminution and/or ligamentous instability. The distal femoral ring used to span the knee joint was removed at six weeks of follow-up after surgery.

Post-Operative Management

Patients were mobilized with a walker (non-weight bearing on the operated limb) from the next day of surgery. Knee range of motion and bedside sitting were started as per pain tolerance and increased gradually. Pin tract care was demonstrated to patients and attendants in the ward during the course of their stay in the hospital. The patient or the attendant were taught to do pin tract care at home after discharge. Patients were discharged usually on the 5th postoperative day.

Patients were asked to follow up in outpatient department (OPD) at weekly intervals for one month and monthly thereafter for four months. Radiological investigations like X-rays were done immediately after surgery, at two weeks, and then monthly for four months. Weight bearing was started immediately in patients with a knee-spanning fixator and at 4 weeks in patients with a below-knee construct, which was gradually increased to full weight bearing as per pain tolerance.

If an x-ray done four months postoperatively suggested union at the fracture, then the ring fixator was dynamized by loosening the rods and was removed two weeks thereafter. A trial of walking without connecting rods was given before removing the fixator. Implant removal was

done as an OPD procedure. Aggressive exercises for the knee range of motion were initiated, and quadriceps strengthening was encouraged after ring removal. Patients were called for follow-up at six months after ring removal.

Functional and Radiological Assessment

Functional and radiological data of the patient was obtained six months after ring fixator removal from the medical records. Walking capacity, pain, knee range of motion, and knee stability were used to grade the clinical outcome using Rasmussen's clinical criteria [Table 1].^[25]

Table 1. Criteria for Rasmussens Clinical Assessment

Parameters	Points
A. Subjective Complaints	
a. Pain	
No pain	6
Occasional pain	5
Constant pain after activity	4
Significant rest pain	0
b. Walking Capacity	
Normal walking capacity (in relation to age)	6
Walking outdoors for atleast 1 hr	4
Short walk outdoors for >15 min	2
Walking indoors only	1
Wheel-chair/Bedridden	0
B. Clinical signs	
a. Extension	
Normal	6
Lack of extension (0 – 10°)	4
Lack of extension >10°	2
b. Total range of motion	
≥140°	6
≥120°	5
≥90°	4
≥60°	2
≥30°	0
c. Stability	
Normal stability in extension and 20° of flexion	6
Abnormal instability 20° of flexion	5
Instability in extension <10°	4
Instability in extension >10°	2
Grading	Points
Maximum	30
Excellent	27 - 30
Good	20 - 26
Fair	10 - 19

Poor	<10
------	-----

The clinical score was graded as excellent (27-30 points), good (20-26 points), fair (10-19 points), and poor (<10 points). Articular depression, condylar widening, and angulation were measured using X-rays, and Rasmussen's radiological criteria were used [Table 2].^[28] The radiological score was graded as excellent (9 points), good (7-8 points), fair (5-6 points), and poor (< 5 points).

Table 2. Criteria for Rasmussens Radiological Assessment

Radiological Parameters	Points
A. Articular depression	
None	3
≤ 5 mm	2
6-10 mm	1
> 10 mm	0
B. Condylar Widening	
None	3
≤ 5 mm	2
6-10 mm	1
> 10 mm	0
C. Varus/ Valgus Angulation	
None	3
< 10°	2
10-20°	1
> 20°	0
Grading	Points
Maximum	9
Excellent	9
Good	7 - 8
Fair	5 - 6
Poor	<5

Statistical Analysis

The collected data was analyzed using IBM SPSS software (Version 26.0) using descriptive statistical tools. In the descriptive statistics, the continuous variables were expressed in terms of mean and standard deviation, while the categorical variables were expressed in terms of frequency and percentage.

Ethical considerations

The study was conducted in accordance with the Declaration of Helsinki. The study was carried out after approval from the Institutional Ethics Committee (Dr. VPMCH & RC/IEC/85/2023-2024). Appropriate permissions from the head of department and the head of institute were obtained to access the data of the patients.

Results

The mean age of the patients was 40.97 ± 12.47 years, with 29 male and 6 female patients. Eleven patients had extra-articular proximal tibia fractures and twenty-four patients had intra-articular proximal tibia fractures. 26 patients had grade 2 soft tissue injuries and 8 patients had grade 3 soft tissue injury. All patients achieved radiological union at a mean duration of 16 weeks. Full weight-bearing was also allowed at a mean of 12 weeks. Functional results were excellent in 22 cases, good in 12 cases and poor in one case [Table 3, Table 4]. Functional results were marginally better in grade 2 than in grade 3 soft tissue injury while radiological outcomes did not vary. Most patients achieved functional range of motion at the knee joint (average flexion 128°) except one, who had a flexion of less than 110° . One patient had a major complication in the form of chronic septic arthritis of the knee joint, resulting in a poor outcome. 10 cases had pin tract infections, which were managed with oral antibiotics and pin tract care and did not require any surgical intervention for the same. Axial malalignment of less than 10° was seen in 4 cases, and articular step of less than 5 mm was seen in 2 cases. A few selected cases have been shown in Figures 1, 2, and 3.

Discussion

The high-velocity road traffic accidents have immensely contributed to the rise in the incidence of type V and VI tibial plateau fractures.^[29] The treatment of these fractures remains challenging due to the extensive nature of soft tissue injury, complications in the fixation of the articular surface, and the need for stable fixation for early mobilization.^[30] Thus, operating in such a scenario leads to a high incidence of complications like breakdown of wound, infections and compartment syndrome.^[9] The most popular option in practice remains open reduction and internal fixation with a dual plate so as to get good reduction and fixation along with anatomic restoration of the articular surface. However, this method is reported to have a high rate of wound-related complications, infection, stiffness, and secondary loss of reduction.^[31-33] Studies on open reduction and internal fixation have also reported collapse of articular fragments, loss of reduction, malunion and non-unions, and a higher reoperation rate.^[34,35] In a study reported by Barei et al., open reduction internal fixation with dual plating in 83 patients showed deep infection requiring repeat operation in 8.4% of cases, deep vein thrombosis in 16 cases, required manipulation of the knee for stiffness in 5 cases, heterotrophic ossification in 2 cases, and non-union in 1 case.^[36]

Thus, the research for the development of new techniques in order to get better outcomes in the high-energy proximal tibial plateau fractures is accelerating. In view of this, an Ilizarov fixation system with minimal internal fixation and subarticular screws is reported to offer several benefits in treating high-energy proximal tibia fractures.^[18-20] A recent meta-analysis by Li et al. reported that the Ilizarov ring fixator, in comparison with open reduction internal fixation, had no difference

between the union time, ROM, and functional and radiological outcome. However, it provided early ROM, weight-bearing, and early restoration to work.^[37] Another multicenter, prospective, randomized clinical trial reported lesser blood loss, fewer hospital stays, and a superior early outcome in terms of HSS scores at six months in the Ilizarov fixator group in comparison with open reduction and internal fixation.^[38]

Table 3. Radiological and functional scores of patients with intra-articular proximal tibia fractures

Patient Number	Rasmussen radiological score based on articular depression, condylar widening and alignment		Rasmussen clinical score based
	Pre-operative	Post-operative	
1	Poor (4)	Excellent (9)	Excellent (29)
4	Fair (5)	Excellent (9)	Excellent (28)
5	Fair (5)	Excellent (9)	Excellent (29)
7	Poor (3)	Good (7)	Good (24)
8	Fair (6)	Excellent (9)	Excellent (27)
9	Good (8)	Excellent (9)	Excellent (27)
10	Poor (4)	Good (7)	Good (22)
11	Good (7)	Excellent (9)	Excellent (28)
12	Fair (5)	Good (8)	Good (21)
13	Good (7)	Excellent (9)	Excellent (27)
15	Fair (6)	Excellent (9)	Excellent (28)
17	Fair (5)	Good (8)	Good (23)
18	Fair (5)	Good (8)	Good (21)
19	Good (7)	Excellent (9)	Excellent (29)
20	Fair (6)	Excellent (9)	Excellent (27)
21	Poor (3)	Poor (4)	Poor (9)
22	Good (8)	Excellent (9)	Excellent (28)
26	Fair (6)	Excellent (9)	Excellent (28)
27	Fair (6)	Excellent (9)	Excellent (27)
28	Fair (5)	Excellent (9)	Excellent (28)
29	Poor (4)	Good (7)	Good (22)
30	Fair (5)	Excellent (9)	Excellent (29)
33	Fair (6)	Good (7)	Good (24)
35	Fair (6)	Good (8)	Good (23)

Table 4. Radiological and functional scores of patients with extra-articular proximal tibia fractures

Patient Number	Rasmussen radiological score based on articular depression, condylar widening and alignment		Rasmussen clinical score based
	Pre-operative	Post-operative	
2	Good (7)	Excellent (9)	Excellent (28)
3	Fair (6)	Excellent (9)	Excellent (27)
6	Fair (6)	Good (8)	Good (21)
14	Poor (4)	Good	Good
16	Good (8)	Excellent (9)	Excellent (28)
23	Good (8)	Excellent (9)	Excellent (29)
24	Fair (6)	Excellent (9)	Excellent (28)
25	Fair (5)	Excellent (9)	Excellent (27)
31	Poor (4)	Good (7)	Good (21)

32	Good (7)	Excellent (9)	Excellent (28)
34	Good (7)	Good (8)	Good (26)

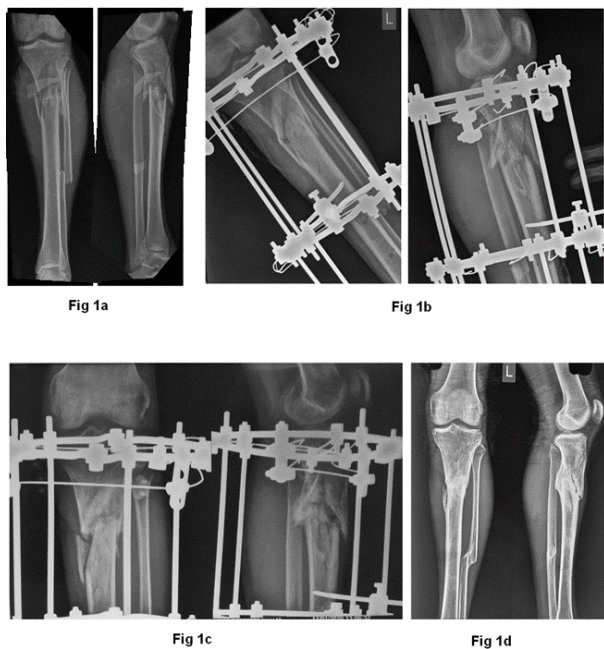


Figure 1. 19-year-old male with grade II open, comminuted, Extra-articular proximal tibia fracture, a) Pre-operative radiograph of tibia Antero posterior and lateral View b) post-operative radiographs showing correction of alignment c) 3.5 moths post-operative radiograph showing progressive union at the fracture site; d) 6 months after ring removal radiographs showing well united fracture in good alignment.

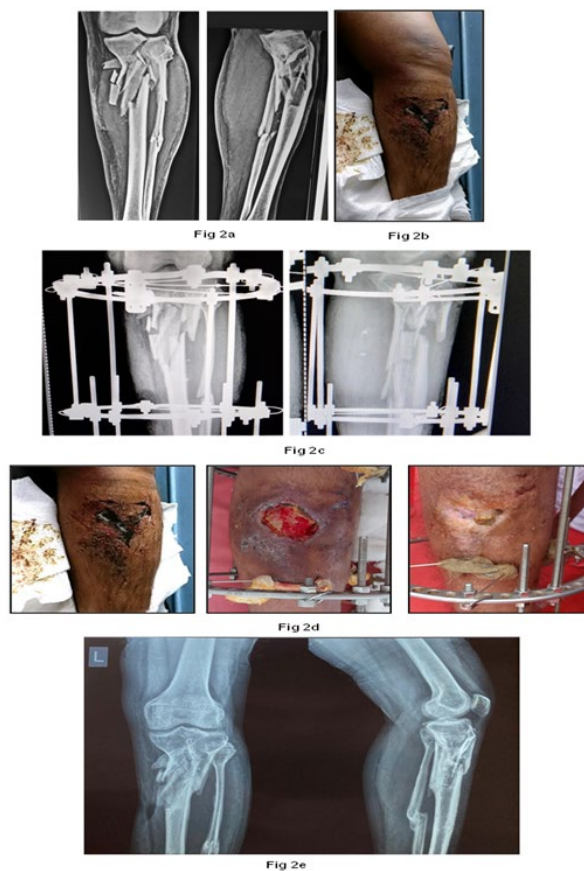


Figure 2. 50-year-old male, Road Traffic Accident a) Radiographs showing Schatzker type VI Intra articular Proximal tibia fracture; b) Bad skin condition with full thickness patchy skin necrosis; c) Post-Operative radiographs after Ilizarov ring fixation; d) Gradual wound healing without need for extra plastic surgery procedures; e) 6 months after ring removal radiograph showing well united fracture in good alignment.

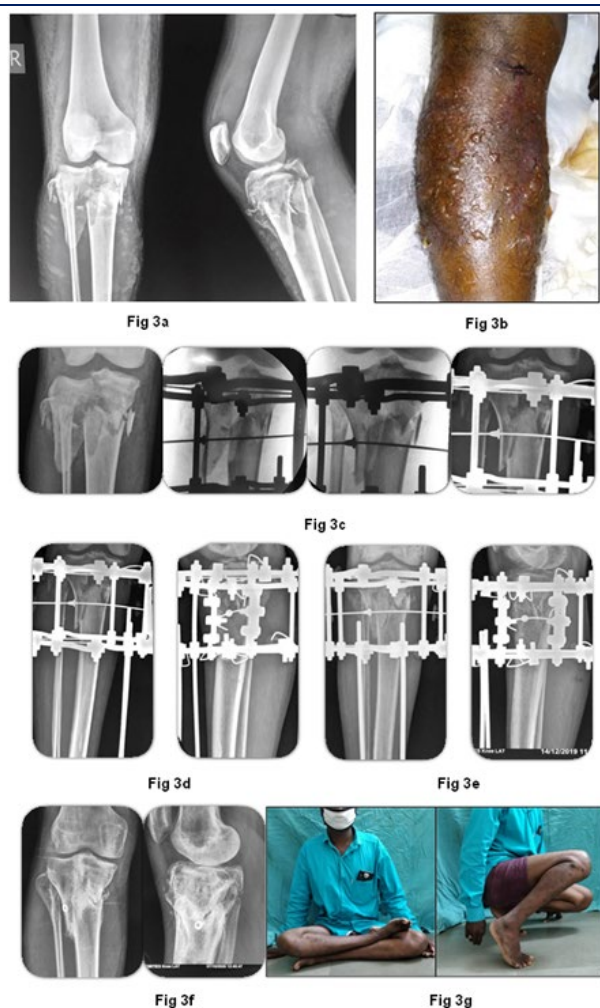


Figure 3. 25-year-old male, Road Traffic Accident a) Radiograph showing Schatzker type VI intra articular proximal tibia fracture; b) Skin condition showing hemorrhagic blisters c) Intra Operative X ray images showing Metaphysical reduction with the use of olive wires; d) Post-Operative radiographs of tibia AP and Lat views; e) 3 months Post-Operative radiographs showing good alignment and progressive fracture union; f) Knee radiograph 6 months after ring removal showing good union at fracture site and intra articular congruity; g) Excellent functional outcome 6 months after ring removal.

Ali et al., describes the advantages of the ring fixation system in an already compromised soft tissue environment by probably reducing and stabilizing the fracture with minimal or no soft tissue dissection. As compared to conventional external fixators, the ring construct with tensioned wires is observed to facilitate increased mechanical stability and better meta diaphyseal purchase in soft cancellous bone. The bridging device helps in acting as a scaffold for increasing the strength of the subchondral bone, thereby restoring the intrinsic stability of the fracture site and preventing the collapse of

the subchondral bone. This allows the patient to transfer his or her weight through this flexible scaffold to the distal diaphysis. The ring construct thereby facilitates the early movement of joints and early weight bearing while maintaining reduction.^[39] The opportunity to add mini-open reduction, minimal internal fixation, and a brief period of knee immobilization make the procedure practically simpler without compromising the final outcome. The illizarov fixator system uses percutaneous wires to avoid additional devitalization of the bone since the periosteal and endosteal blood supply do not undergo a secondary insult. The olive wire acts as lag screws, compresses the fragments against the condyle by holding the fragments against vertical shear, and creates a relatively stable joint surface configuration.^[40] The mechanical axis of the lower limb can be managed and observed by adjustment of the frame postoperatively in the outpatient department. Spanning the knee with the external fixators also permits a stable environment for the healing of the collateral ligaments.

In the current study, all patients achieved radiological union at a mean duration of 16 weeks, and full weight-bearing was allowed at a mean of 12 weeks. Our results are in accordance with the earlier reported studies where radiological union among the patients was observed between 11.8 weeks and 17 weeks.^[5,14,18,19,22] We observed functional outcomes to be excellent in 22 cases, good in 12 cases, and poor in one. Catagni et al. reported excellent to good results in their hybrid Ilizarov with minimal internal fixation.^[41] Ferreira et al., reported good results in 46 cases of Schatzker V and VI tibial plateau fractures without any loss of reduction or wound complications using limited open reduction, cannulated screw fixation, and a circular fixator.^[42] Katsenis et al., reported excellent to good results in 81% of the cases of high-velocity tibial plateau fractures treated with ring fixator.^[43] In a study on 15 patients, Debnath et al. reported excellent outcomes in 7 cases, good outcomes in 7 cases, and fair outcome in 1 case.^[22] Apart from a few pin tract infections in 10 cases, which were managed with proper pin tract care without requiring any additional surgical procedure, the current study reports a major infection in one patient. The patient had chronic septic arthritis of the knee joint, which we presume was due to intrasynovial wire placement in the proximal tibia, very close to the articular surface.

All the patients in the current study did not present any major soft tissue complications, no significant malunion and the restoration of the articular surface as evident the radiological reports bring forth the advantages of the external fixator technique having minimal invasion as the

preferred treatment in such high-velocity fractures. The low incidence of malunion observed in the current study can be attributed to the possibility of correcting any malalignment even in the post-operative period with the Ilizarov technique. The low incidence of non-union and deep infections is possibly due to the maximum preservation of the soft tissue envelope around the highly comminuted fracture fragments alongwith the undisturbed fracture hematoma in the Ilizarov technique. Despite the advantages provided by the Ilizarov technique, the outcome of this technique is largely affected by the treating surgeon's understanding of the fracture anatomy and his decisions regarding the safe zones for wire placements, appropriate use of olive wires or interfragmentary screws, intra-operative restoration of the articular surface, and stable fixation. While most of the articular congruence can be brought about by indirect means, impacted fragments are dealt with fragment specific, limited open reduction.

In general, the results of our study are comparable to the reported results. We had a high union rate, the reoperation rate of our cases was very low, and none of our patients needed further surgery. The patient with chronic septic arthritis of the knee joint has not yet been operated on again, but we believe that he will require re-operation in the form of knee arthrodesis in the near future. The technique of hybrid modification in the form of 5/8th ring fixation in some cases of stable condyles and the incorporation of a uni-planner fixator distally can probably help us minimize the discomfort of the bulky nature of the ring fixator.

The current study has strengths as well as disadvantages. The strength involves the data on a significant number of patients with no loss of follow-up, focusing on both clinical and radiological assessments of the patients. The disadvantages of the current study involve the retrospective nature of the study. The study has been conducted at a single center, and cases have been operated by a single surgeon. Multicenter studies on larger sample sizes, longer follow-ups, and in comparison, the open reduction internal fixation group are warranted.

Conclusions

Despite the high complication rates, open reduction internal fixation remains a widely used method for high-energy proximal tibia fractures. The current study provides evidence for the Ilizarov ring fixator method to be an excellent method for the treatment of proximal tibia fractures with low morbidity. This technique is highly recommended in such high-velocity injuries with severe

comminution of bony fragments and a jeopardized soft tissue envelope.

Acknowledgment

Authors would like to thank all the participants in the study.

Competing interests

The authors declare that they have no competing interests.

Abbreviations

Arbeitsgemeinschaft für Osteosynthesefragen: AO;
Outpatient Department: OPD.

Authors' contributions

Conceptualization: KG, SJ, SP, AM; Methodology: KG; Formal analysis and investigation: KG, AM Writing - original draft preparation: KG, AM; Writing - review and editing: AM, SJ, SP; Resources: SJ, SP; Supervision: SJ, SP. All authors read and approved the final manuscript. All authors take responsibility for the integrity of the data and the accuracy of the data analysis.

Funding

None.

Role of the funding source

None.

Availability of data and materials

The data used in this study are available from the corresponding author on request.

Ethics approval and consent to participate

The study was conducted in accordance with the Declaration of Helsinki. The study was carried out after approval from the Institutional Ethics Committee (Dr. VPMCH & RC/IEC/85/2023-2024). Appropriate permissions from the head of department and the head of institute were obtained to access the data of the patients.

Consent for publication

By submitting this document, the authors declare their consent for the final accepted version of the manuscript to be considered for publication.

References

1. Buckle R, Blake R, Watson JT, Morandi M, Browner BD. Treatment of complex tibial plateau fractures with the Ilizarov external fixator. *J Orthop Trauma*. 1993;7:167 doi:[10.1097/00005131-199304000-00044](https://doi.org/10.1097/00005131-199304000-00044)
2. Patel T, Brod B, Ahmed SS, Khoja MZ, Sainvil F, Rizvi SA. Chronic Thromboembolic Pulmonary Hypertension (CTEPH) presenting as a right atrial myxoma-A case report and review of the literature. *Novel Clin Med* 2023;2(4):209-18. doi:[10.22034/ncm.2023.407925.1100](https://doi.org/10.22034/ncm.2023.407925.1100)
3. Watson JT, Coufal C. Treatment of complex lateral plateau

- fractures using Ilizarov techniques. *Clin Orthop Relat Res.* 1998; 353:97-106. doi:10.1097/00003086-199808000-00012 PMID:9728164
4. El Barbary H, Abdel Ghani H, Misbah H, Salem K. Complex tibial plateau fractures treated with Ilizarov external fixator with or without minimal internal fixation. *Int Orthop.* 2005;29(3): 182-5. doi:10.1007/s00264-005-0638-6 PMID:15756605 PMCid:PMC3456886
 5. Dendrinis GK, Kontos S, Katsenis D, Dalas A. Treatment of high-energy tibial plateau fractures by the Ilizarov circular fixator. *J Bone Joint Surg Br.* 1996;78(5):710-7. doi:10.1302/0301-620X.78B5.0780710 PMID:8836055
 6. Schatzker J, McBroom R, Bruce D. The tibial plateau fracture. The Toronto experience 1968-1975. *Clin Orthop Relat Res.* 1979; (138): 94-104.
 7. AO/OTA Fracture and Dislocation Classification Compendium-2018. www.aofoundation.org
 8. Tschernse H and Gotzen L. Fractures with soft tissue injuries. Berlin: Springer; 1984. doi:10.1007/978-3-642-69499-8
 9. Oestern H-J, Tschernse H. Pathophysiology and Classification of Soft Tissue Injuries Associated with Fractures. *Fract with Soft Tissue Inj.* 1984;3:1-9. doi:10.1007/978-3-642-69499-8_1
 10. Scotland T, Wardlaw D. The use of cast-bracing as treatment for fractures of the tibial plateau. *J Bone Joint Surg Br.* 1981; 63B(4): 575-8. doi:10.1302/0301-620X.63B4.7298688 PMID:7298688
 11. Ambroziak M, Durka M, Maciąg B, Hadamus A, Strzelczyk P. Intraoperative Complications in an Open Intra-articular Fracture of the Proximal Tibia. A Case Study. *Ortop Traumatol Rehabil* 2017;19(3):301-9. doi:10.5604/15093492.1241410
 12. Henkelmann R, Frosch KH, Glaab R, Lill H, Schoepp C, Seybold D, Josten C, Hepp P; Committee TRAUMA of the AGA-Society for Arthroscopy and Joint Surgery. Infection following fractures of the proximal tibia - a systematic review of incidence and outcome. *BMC Musculoskelet Disord.* 2017;18(1):481. doi:10.1186/s12891-017-1847-z PMID:29162084 PMCid:PMC5699108
 13. Arnold JB, Tu CG, Phan TM, Rickman M, Varghese VD, Thewlis D, Solomon LB. Characteristics of postoperative weight bearing and management protocols for tibial plateau fractures: Findings from a scoping review. *Injury.* 2017;48(12):2634-42. doi:10.1016/j.injury.2017.10.040 PMID:29102370
 14. Pandey S, Bidary S. Functional and Radiological Outcome of Schatzker Type V and VI Tibial Plateau Fracture Treated with Closed Reduction and Ilizarov Fixation with or without Minimally Invasive Screw Supplementation. *J Coll Med Sci Nepal* 2022;18(3):244-53 doi:10.3126/jcmsn.v18i3.47475
 15. Kumar J, Siddiqui AA, Katto MS, Jamil M, Wasim MA, Yaqoob U. Treatment of high-energy intra-articular fractures of tibia with Ilizarov external fixator in adults: A tertiary centre experience. *Int J Clin Pract.* 2021;75(9):e14488. doi:10.1111/ijcp.14488
 16. Naude JJ, Manjra MA, Birkholtz F, Barnard AC, Tetsworth K, Glatt V, Hohmann E. Functional Outcomes and Quality of Life Following Complex Tibial Fractures Treated with Circular External Fixation: A Comparison between Proximal, Midshaft, and Distal Tibial Fractures. *Strategies Trauma Limb Reconstr.* 2021;16(1):32-40. doi:10.5005/jp-journals-10080-1506 PMID:34326900 PMCid:PMC8311744
 17. Bove F, Sala F, Capitani P, Thabet AM, Scita V, Spagnolo R. Treatment of fractures of the tibial plateau (Schatzker VI) with external fixators versus plate osteosynthesis. *Injury.* 2018 Nov;49 Suppl 3:S12-8. doi:10.1016/j.injury.2018.09.059 PMID:30415663
 18. Kawoosa AA, Mantoo SA, Ali N, Dar GN. Clinico - Radiological Results of Tibial Bicondylar Fractures Managed with Ilizarov Technique with or without Minimal Internal Fixation. *Malays Orthop J.* 2022;16(1):18-27. doi:10.5704/MOJ.2203.004 PMID:35519521 PMCid:PMC9017920
 19. Subramanyam KN, Tammanaiah M, Mundargi AV, Bhoskar RN, Reddy PS. Outcome of complex tibial plateau fractures with Ilizarov external fixation with or without minimal internal fixation. *Chin J Traumatol.* 2019;22(3):166-71. doi:10.1016/j.cjtee.2018.11.003 PMID:31072699 PMCid:PMC6543267
 20. Hegde AS, Madegowda A, Khanna V, Rao S. Clinical and Radiological Outcome of Complex Proximal Tibia Fractures Managed with Hybrid/Ilizarov Fixator with or without Minimal Internal Fixation. *Ortop Traumatol Rehabil.* 2021;23(4):279-85. doi:10.5604/01.3001.0015.2365 PMID:34511431
 21. Bhowmick K, Boopalan PRJVC, Gunasekaran C, Livingston A, Jepeganam TS. Management of Chronic Infected Intra-Articular Fractures of the Proximal Tibia with Ilizarov Ring Fixation. *J Knee Surg.* 2020;33(2):213-22. doi:10.1055/s-0038-1677512 PMID:30650438
 22. Debnath UK, Jha DK, Pujari PK. Results of ring (Ilizarov) fixator in high energy Schatzker type VI fractures of proximal tibia. *J Clin Orthop Trauma.* 2018;9(2):186-91. doi:10.1016/j.jcot.2017.08.005 PMID:29896026 PMCid:PMC5995004
 23. Markhardt BK, Gross JM, Monu JU. Schatzker classification of tibial plateau fractures: use of CT and MR imaging improves assessment. *Radiographics.* 2009;29(2):585-97. doi:10.1148/rg.292085078 PMID:19325067
 24. AO/OTA Fracture and Dislocation Classification Compendium-2018. https://www.aofoundation.org/trauma/clinical-library-and-tools/journals-and-publications/classification.
 25. Ibrahim DA, Swenson A, Sassoon A, Fernando ND. Classifications In Brief: The Tschernse Classification of Soft Tissue Injury. *Clin Orthop Relat Res.* 2017;475(2):560-564. doi:10.1007/s11999-016-4980-3 PMID:27417853 PMCid:PMC5213932
 26. Court-Brown, C. M., Paul Tornetta, I., McQueen, M. M., Ricci, W. Rockwood and Green's Fractures in Adults. (2019). United States: Wolters Kluwer Health.
 27. Solomin L. The Basic Principles of External Skeletal Fixation Using the Ilizarov and Other Devices. (2013). Italy: Springer Milan. doi:10.1007/978-88-470-2619-3
 28. Rasmussen PS. Tibial condylar fractures. Impairment of knee joint stability as an indication for surgical treatment. *J Bone Joint Surg Am.* 1973;55:1331-50. doi:10.2106/00004623-197355070-00001
 29. Reátiga Aguilar J, Rios X, González Ederly E, De La Rosa A, Arzuza Ortega L. Epidemiological characterization of tibial plateau fractures. *J Orthop Surg Res.* 2022;17(1):106. doi:10.1186/s13018-022-02988-8 PMID:35183211 PMCid:PMC8858541
 30. Ranatunga IR, Thirumal M. Treatment of Tibial Plateau Schatzker Type VI Fractures with the Ilizarov Technique Using Ring External Fixators Across the Knee: A Retrospective Review. *Malays Orthop J.* 2010;4(2). doi:10.5704/MOJ.1007.006
 31. DeCoster TA, Nepola JV, el-Khoury GY. Cast brace treatment of proximal tibia fractures. A ten-year follow-up study. *Clin Orthop Relat Res.* 1988;(231):196-204. doi:10.1097/00003086-198806000-00026
 32. Ruffolo MR, Gettys FK, Montijo HE, Seymour RB, Karunakar MA. Complications of high-energy bicondylar tibial plateau fractures treated with dual plating through 2 incisions. *J Orthop Trauma.* 2015; 29(2): 85-90. doi:10.1097/BOT.000000000000203 PMID:25050747
 33. Khatri K, Sharma V, Goyal D, Farooque K. Complications in the management of closed high-energy proximal tibial plateau fractures.

- Chin J Traumatol. 2016;19(6):342-7. doi:10.1016/j.cjtee.2016.08.002
PMid:28088939 PMCID:PMC5198935
34. Yu Z, Zheng L, Zhang Y, Li J, Ma B. Functional and radiological evaluations of high-energy tibial plateau fractures treated with double-buttress late fixation. Eur J Med Res. 2009;14(5): 200-5. doi:10.1186/2047-783X-14-5-200 PMid:19541576
PMCID:PMC3351978
35. Unno F, Lefavre KA, Osterhoff G, Guy P, Broekhuysen HM, Blachut PA, et al. Is early definitive fixation of bicondylar tibial plateau fractures safe? An observational cohort study. J Orthop Trauma. 2017;31:151e157. doi:10.1097/BOT.0000000000000779
PMid:28072649
36. Barei DP, Nork SE, Mills WJ, Henley MB, Benirschke SK. Complications associated with internal fixation of high-energy bicondylar tibial plateau fractures utilizing a two-incision technique. J Orthop Trauma. 2004; 18:649e657. doi:10.1097/00005131-200411000-00001 PMid:15507817
37. Li Z, Wang P, Li L, Li C, Lu H, Ou C. Comparison between open reduction with internal fixation to circular external fixation for tibial plateau fractures: A systematic review and meta-analysis. PLoS One. 2020; 15(9): e0232911. doi:10.1371/journal.pone.0232911
PMid:32941429 PMCID:PMC7498044
38. Hall JA, Beuerlein MJ, McKee MD; Canadian Orthopaedic Trauma Society. Open reduction and internal fixation compared with circular fixator application for bicondylar tibial plateau fractures. Surgical technique. J Bone Joint Surg Am. 2009; 91(2):74-88. doi:10.2106/JBJS.G.01165 PMid:19255201
39. Ali AM, Burton M, Hashmi M, Saleh M. Outcome of complex fractures of the tibial plateau treated with a beam-loading ring fixation system. J Bone Joint Surg Br. 2003;85(5):691-9. doi:10.1302/0301-620X.85B5.13855 PMid:12892192
40. Ramos T, Ekholm C, Eriksson BI, Karlsson J, Nistor L. The Ilizarov external fixator-a useful alternative for the treatment of proximal tibial fractures. A prospective observational study of 30 consecutive patients. BMC Musculoskelet Disord. 2013;14:11. doi:10.1186/1471-2474-14-11 doi:10.1186/1471-2474-14-30
41. Catagni MA, Ottaviani G, Maggioni M. Treatment strategies for complex fractures of the tibial plateau with external circular fixation and limited internal fixation. J Trauma. 2007; 63(5): 1043-53. doi:10.1097/TA.0b013e3181238d88 PMid:17993949
42. Ferreira N, Marais LC. Bicondylar tibial plateau fractures treated with fine-wire circular external fixation. Strategies Trauma Limb Reconstr. 2014;9(1): 25-32. doi:10.1007/s11751-014-0185-z
PMid:24510395 PMCID:PMC3951617
43. Katsenis D, Athanasiou V, Megas P, Tyllianakis M, Lambiris E. Minimal internal fixation augmented by small wire transfixion frames for high-energy tibial plateau fractures. J Orthop Trauma. 2005;19(4):241-8. doi:10.1097/01.bot.0000155309.27757.4c
PMid:15795572

How to Cite this Article:

Ketankumar G, Satyen J, Sandip P, Akshaya M, Patil V. Functional and radiological outcome of proximal tibia fractures managed with Ilizarov technique with or without minimal internal fixation. Arch Trauma Res. 2024;13(1):27-35. doi: 10.48307/ATR.2024.422300.1048