

Interdisciplinary Sequential Management of Combination Traumatic Dental Injuries

Prabhat Kumar Chaudhari, Nitesh Tewari¹, Sandhya Maheshwari², Syed Sayeed Ahmed³, Sanjeev Kumar Verma², Mohammed Tariq²

Division of Orthodontics and Dentofacial Deformities, ¹Division of Pedodontics and Preventive Dentistry, Centre for Dental Education and Research, All India Institute of Medical Sciences, New Delhi, Departments of ²Orthodontics and Dentofacial Orthopedics and ³Oral and Maxillofacial Surgery, Dr Z.A. Dental College, Aligarh Muslim University, Aligarh, Uttar Pradesh, India

ORCID:

Prabhat Kumar Chaudhari: <https://orcid.org/0000-0001-9566-4405>

Nitesh Tewari: <https://orcid.org/0000-0002-6747-5110>

Sandhya Maheshwari: <https://orcid.org/0000-0002-0440-0701>

Syed Sayeed Ahmed: <https://orcid.org/0000-0001-8103-1316>

Sanjeev Kumar Verma: <https://orcid.org/0000-0003-1364-9426>

Mohammed Tariq: <https://orcid.org/0000-0001-5333-8185>

Abstract

Combination dental trauma or combination traumatic dental injuries (C-TDIs) are often seen with unique presentations. Although most guidelines address the evidence-based management of such injuries in detail, a sequential protocol and classifications for C-TDI are lacking. In these scenarios, clinical details with imaging tools play an essential role by helping the clinician apply the elements of the TDI protocol in the correct sequence. However, most cases of C-TDI are attended by a general dentist, who often finds it difficult to make such clinical decisions, adversely affecting the prognosis. This article reports a case of a 14-year-old male patient with avulsion of 12, intrusion of 11, 21, and 13, and uncomplicated crown fracture of 11, 21, and 14, with a sequential interdisciplinary approach for the management and long-term follow-up of 10 years.

Keywords: Combination trauma, intrusion, traumatic dental injury

INTRODUCTION

In recent years, traumatic dental injuries (TDIs) have emerged as a public health concern.^[1] The dental traumatology literature has abundant descriptions of the prevalence, etiology, and management of TDI in both the primary and the permanent dentition.^[2] However, these injuries do not always occur in isolation, but are often associated with bodily injuries, panfacial traumas, and various “Combination Dental Traumas.” Guidelines from the International Association of Dental Traumatology (IADT) have been considered as the best available evidence- and consensus-based protocol for the management of TDI^[2-4] and have been updated to reflect newer scientific evidence. Further, mobile applications and clinical decision support tools (CDST), such as the Dental Trauma Guide, have increased worldwide awareness of appropriate protocols.^[5]

One of the shortcomings of most available protocols and CDST is their description of TDIs in isolation. For example, a sequential approach and management protocol are lacking for Combination Dental Trauma or Combination TDI (C-TDI).^[1] The present case describes the interdisciplinary management of a C-TDI with intrusive luxation, avulsion, and crown fracture, along with a follow-up of 10 years.

CASE REPORT

A 14-year-old boy reported with a history of trauma to the face and maxillary anterior teeth. Injury had been sustained

Address for correspondence: Dr. Nitesh Tewari, Division of Pedodontics and Preventive Dentistry, Room Number 602, 6th Floor, Centre for Dental Education and Research, All India Institute of Medical Sciences, New Delhi - 110 029, India. E-mail: dr.nitesht@gmail.com

This is an open access journal, and articles are distributed under the terms of the Creative Commons Attribution-NonCommercial-ShareAlike 4.0 License, which allows others to remix, tweak, and build upon the work non-commercially, as long as appropriate credit is given and the new creations are licensed under the identical terms.

For reprints contact: reprints@medknow.com

How to cite this article: Chaudhari PK, Tewari N, Maheshwari S, Ahmed SS, Verma SK, Tariq M. Interdisciplinary sequential management of combination traumatic dental injuries. Arch Trauma Res 2018;7:169-72.

Access this article online

Quick Response Code:



Website:
www.archtrauma.com

DOI:
10.4103/atr.atr_96_18

20 h previously in a dairy farm, where he was hit by the back leg of a cow. The child complained of pain and the loss of maxillary anterior teeth. Medical history was noncontributory, and his immunizations had been completed according to the national guidelines. On clinical examination, 11, 13, and 21 were found to be intruded, whereas 12 was missing. Orthopantomograms revealed avulsion of 12 and intrusion of 11 mm × 9 mm, 13 mm × 5 mm, and 21 mm × 5 mm. In addition, there were uncomplicated crown fractures in 11, 21, and 14, with lacerations in the surrounding gingiva [Figure 1a-c].

The dental trauma team comprised a pediatric dentist, orthodontist, oral surgeon, endodontist, periodontist, and prosthodontist, formulated a treatment plan which consisted of emergency management, surgical repositioning of 11, and orthodontic extrusion of 13 and 21, along with space closure for avulsed 12. The crown fractures were planned to be managed by composite restoration. Endodontic treatment of repositioned teeth was also suggested.

Surgical repositioning of 11 was performed with the patient under local anesthesia. Intruded teeth were stabilized by the placement of 0.022 × 0.028-inch edge-wise orthodontic brackets (Leone, Anaheim, CA, USA) on 15, 13, 11, 21, 22, 23, and 24 and splinting by 0.016 × 0.022-inch titanium molybdenum alloy (TMA) archwire [Figure 2a-d]. The gingival lacerations were sutured, and the patient was discharged with prescriptions for antibiotics (amoxicillin 250 mg TDS) and analgesics for 5 days. Pulp extirpation was performed in 11 on the 10th day after the injury and was replaced by calcium hydroxide-iodoform paste (Metapex, MetaBiomed, India) with obturation after 2 weeks. Composite restorations were done in 11, 21, and 14, followed by a maxillary 0.016-inch Nickel–titanium archwire ligation and progression to heavy archwires for alignment in the first 3 months. Space closure for the missing tooth 12 was done by means of a 0.016 × 0.022-inch TMA archwire with multiple loops in the ensuing 6 months [Figure 3]. The discoloration

and loss of vitality in 21 were managed subsequently by root canal treatment. Alignment in the mandibular arch was accomplished with a 0.022 × 0.028-inch edge-wise appliance, followed by finishing and detailing of occlusion by means of lighter wire.

Fixed appliances were removed after a total treatment time of 15 months [Figures 4 and 5]. At this stage, crown preparation was done in 11 and 21, and metal ceramic crowns were cemented to mask the discoloration present in 11 and 21. To establish an esthetic smile, 13 was shaped to match 12. Acrylic retainers were used for 6 months (2 months full-time and nightly thereafter). The patient was recalled after 3 months, 6 months, and 1 year, and then annually for 5 years. There were no adverse clinical or radiographic signs observed in follow-ups. The patient did not report subsequently, only to appear in November 2017 complaining of crown discoloration. Clinical and radiographic features were indicative of healthy and stable teeth, with ceramic fracture on the palatal surfaces of 11 and 21, which had been designated for replacement by full ceramic crowns [Figures 6 and 7].

DISCUSSION

“Combination TDI” presents with unique scenarios requiring rapid decision-making based on evidence-based protocols. The present case was managed according to the IADT guidelines of 2007 (the TDI occurred in 2007), focusing on intrusive luxation, avulsion, and uncomplicated crown fractures of the permanent dentition.^[2,3] Teeth with intrusion >7 mm were recommended for immediate surgical repositioning, while those <7 mm could be managed by orthodontic extrusion.^[2,6] In this case, 11 was surgically repositioned and stabilized, whereas 21 and 13 were extruded orthodontically. Andreasen *et al.* emphasized that the adverse consequences of intruded permanent teeth are based on the age of the patient, the stage of root development, tooth location, and the extent of injury.^[6] Recommendations for the management of intrusion are aimed at the prevention of tooth ankylosis, which might start with time.^[2,4,7]

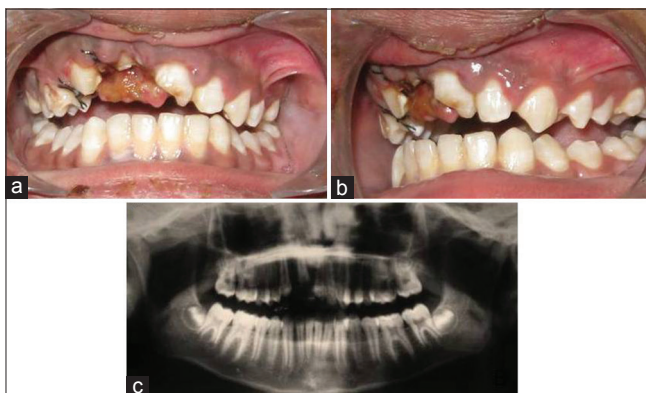

Figure 1: (a and b) Preoperative intraoral images of a 14-year-old boy 20 h after traumatic dental injuries, showing intrusive luxation in 13, 11, and 21 and uncomplicated crown fracture in 14, 11, and 21. (c) Orthopantomogram revealing extent of intrusion and avulsion of 12

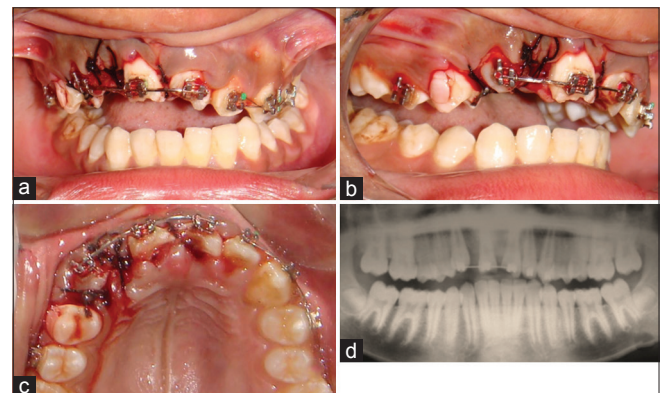


Figure 2: (a-d) Surgically repositioned 11 and flexible splinting with 0.022 × 0.028-inch edge-wise orthodontic brackets on 15, 13, 11, 21, 22, 23, and 24 with 0.016 × 0.022-inch titanium molybdenum alloy archwire

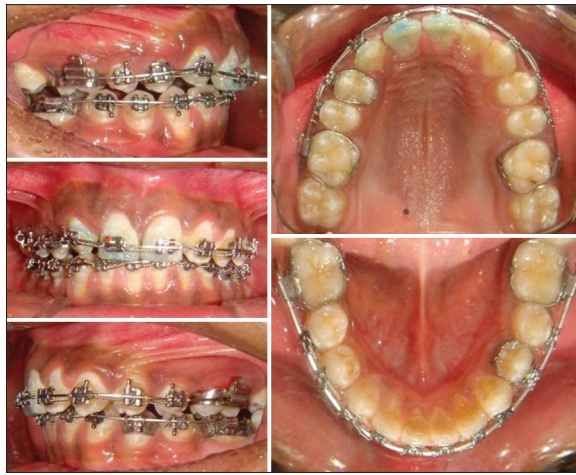

Figure 3: Intraoral images of the patient's orthodontic appliances in the maxillary and mandibular arches

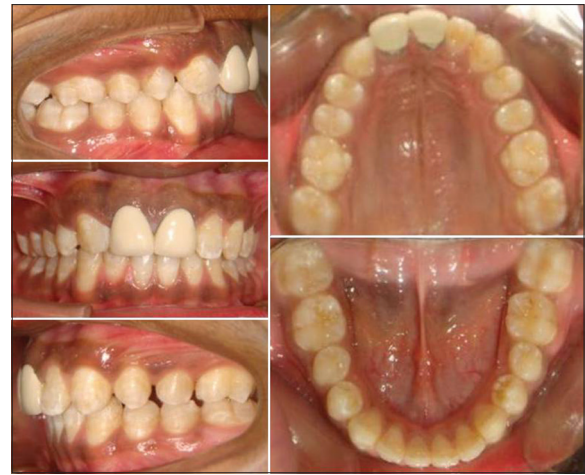

Figure 4: Intraoral images after the completion of orthodontic treatment, endodontic treatment, and placement of metal-ceramic crowns in 11 and 21

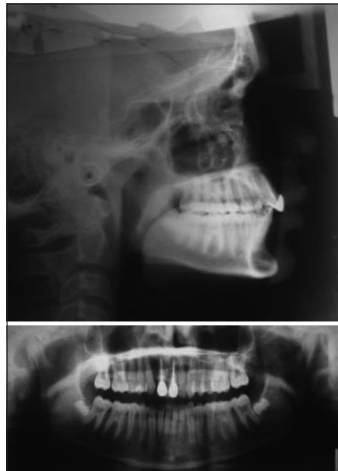

Figure 5: Postoperative posttreatment orthopantomogram and lateral cephalogram

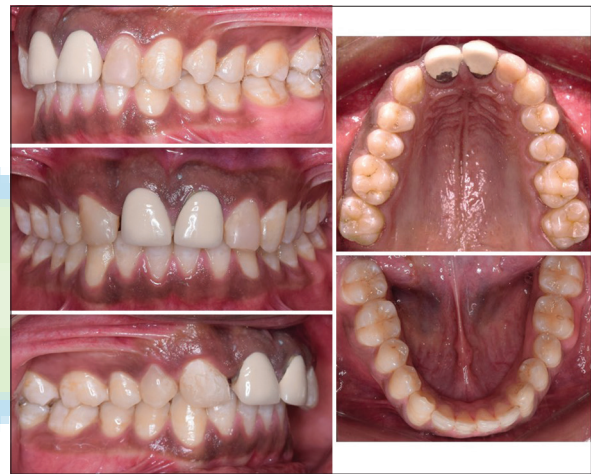

Figure 6: Intraoral images after 10 years of follow-up

One important aspect of combination dental injuries is the sequence of management. A clinical judgment warrants initial management of luxation injuries so that time can be saved for better prognosis and accessibility to the operating field can be improved.^[4,6,9] In the present case, composite build-up was done at the second appointment, while the teeth had been stabilized by flexible splint with orthodontic brackets. Pulp extirpation is a critical step in the prevention of external root resorption of mature permanent teeth, since it reduces the chances of pulp necrosis and subsequent inflammation in periradicular structures.^[4,6,8] Endodontic treatment for surgically repositioned 11 was performed on the 10th day with an intermediate dressing, followed by obturation after 2 weeks. Luxation injuries often result in the loss of vitality in teeth due to pulp strangulation and necrosis,^[6] has occurred in 21, which had to be managed endodontically; although, this did not affect the overall outcome.

Poor awareness of options for the emergency management of TDI in developing countries often results in their delayed or

compromised management.^[1] In the present case, avulsed 12 was not restored, and the trauma team had to work on space closure for 12 using an edge-wise orthodontic appliance, followed by metal-ceramic crowns in 11 and 21 and reshaping of 13 into a lateral incisor. A similar protocol was followed by Elbay *et al.* for the management of extrusive luxation, avulsion, and crown fracture for a patient who reported after a delay.^[10] The IADT guidelines have emphasized the importance of long-term follow-up for all TDI.^[4] This is even more important in luxation injuries and combination traumas. This guideline was followed in the present case, with no adverse outcome observed after 10 years.

The predictability of long-term success in the management of TDI remains controversial,^[8] with multiple contributing factors that can be patient-related, such as age, stage of development, medical condition, and awareness of the emergency management of TDI. The likelihood of long-term success can also be attributed to the type of trauma, such as severity, force, intensity, resiliency of the object, and its size

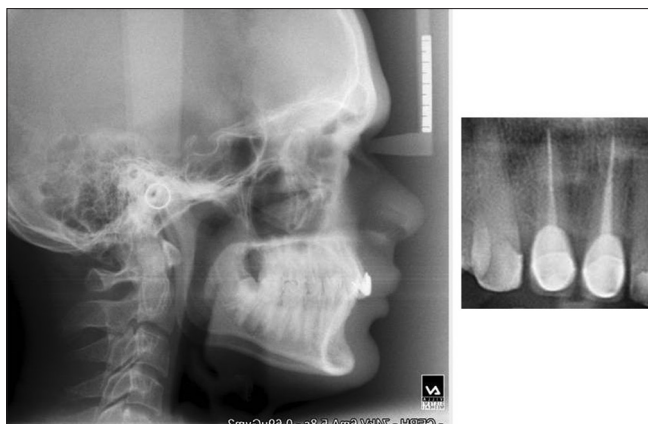


Figure 7: Radiographs after 10 years of follow-up

and shape. Another aspect is the type of emergency treatment, the protocol followed, the time elapsing before the patient seeks care and patient compliance.^[6-8] In the present case, the long-term success of treatment can reasonably be attributed to adherence to the IADT guidelines, sequencing of phases of treatment, and long-term follow-up.

CONCLUSION

The interdisciplinary dental trauma team is critical for the effective management of C-TDI. A sequential approach based on IADT guidelines can improve the prognosis of cases; however, more scientific evidence is needed for the development of specific protocols and increasing the predictability of management.

Informed consent

Patient consent was obtained before taking records and preparation of manuscript.

Declaration of patient consent

The authors certify that they have obtained all appropriate consent and assent forms. In the form, the parents have given their consent and the boy his assent for the images and other

clinical information to be reported in the journal. The parents and the patient understand that name and initials will not be published and due efforts will be made to conceal identity, but anonymity can not be guaranteed.

Financial support and sponsorship

Nil.

Conflicts of interest

There are no conflicts of interest.

REFERENCES

1. Lam R. Epidemiology and outcomes of traumatic dental injuries: A review of the literature. *Aust Dent J* 2016;61 Suppl 1:4-20.
2. Flores MT, Andersson L, Andreassen JO, Bakland LK, Malmgren B, Barnett F, *et al.* International association of dental traumatology. Guidelines for the management of traumatic dental injuries. I. Fractures and luxations of permanent teeth. *Dent Traumatol* 2007;23:66-71.
3. Flores MT, Andersson L, Andreassen JO, Bakland LK, Malmgren B, Barnett F, *et al.* International association of dental traumatology. Guidelines for the management of traumatic dental injuries. II. Avulsion of permanent teeth. *Dent Traumatol* 2007;23:130-6.
4. Diangelis AJ, Andreassen JO, Ebeleseder KA, Kenny DJ, Trope M, Sigurdsson A, *et al.* International association of dental traumatology guidelines for the management of traumatic dental injuries: 1. Fractures and luxations of permanent teeth. *Dent Traumatol* 2012;28:2-12.
5. Djemal S, Singh P. Smartphones and dental trauma: The current availability of apps for managing traumatic dental injuries. *Dent Traumatol* 2016;32:52-7.
6. Andreassen JO, Bakland LK, Andreassen FM. Traumatic intrusion of permanent teeth. Part 2. A clinical study of the effect of preinjury and injury factors, such as sex, age, stage of root development, tooth location, and extent of injury including number of intruded teeth on 140 intruded permanent teeth. *Dent Traumatol* 2006;22:90-8.
7. Owtad P, Shastry S, Papademetriou M, Park JH. Management guidelines for traumatically injured teeth during orthodontic treatment. *J Clin Pediatr Dent* 2015;39:292-6.
8. Moule A, Cohenca N. Emergency assessment and treatment planning for traumatic dental injuries. *Aust Dent J* 2016;61 Suppl 1:21-38.
9. Chaushu S, Shapira J, Heling I, Becker A. Emergency orthodontic treatment after the traumatic intrusive luxation of maxillary incisors. *Am J Orthod Dentofacial Orthop* 2004;126:162-72.
10. Elbay ÜŞ, Baysal A, Elbay M, Sarıdağ S. Multidisciplinary approach to delayed treatment of traumatic teeth injuries involving extrusive luxation, avulsion and crown fracture. *Oper Dent* 2014;39:566-71.