

Spinal Cord Injury Without Radiological Abnormality in Adult Thoracic Spinal Trauma

Kavin Khatri^{1,*}; Kamran Farooque¹; Ankit Gupta¹; Vijay Sharma¹

¹Department of Orthopaedics, Jai Prakash Narayan Apex Trauma Centre, All India Institute of Medical Sciences, Safdarjung Enclave, New Delhi, India

*Corresponding author: Kavin Khatri, Department of Orthopaedics, Jai Prakash Narayan Apex Trauma Centre, All India Institute of Medical Sciences, Safdarjung Enclave, New Delhi, Delhi, India. Tel: +91-8743878077, E-mail: kavinkhatri84@gmail.com

Received: March 27, 2014; Revised: May 22, 2014; Accepted: September 21, 2014

Introduction: Spinal cord injury without radiological abnormality (SCIWORA) is a rare entity and usually involves the cervical spine. Thoracic spine involvement is very rare due to the stability provided by the rib cage. The mechanisms of injury and pathophysiology are still debatable.

Case Presentation: We present a case of adult male who had road traffic accident and presented with paraplegia. The initial radiological investigations carried out in the emergency department were reported to be normal, however, subsequent magnetic resonance imaging revealed spinal cord contusion without vertebral column disruption. The patient recovered partially with conservative treatment measures including bed rest and methylprednisolone.

Conclusions: Spinal trauma patients presenting with neurological deficit but no radiological abnormality should be treated as a case of SCIWORA.

Keywords: Spinal Cord Injuries; Trauma; Spine

1. Introduction

The term spinal cord injury without radiological abnormality (SCIWORA) was first described by Pang and Wilberger in year 1982 (1). They used this term to define the cases of spinal cord injury that had no evidence of vertebral fractures or mal-alignment on radiographs or computerized tomography. With the advent of magnetic resonance imaging (MRI), there has been a surge in detection of the acute disc prolapse, ligamentous injuries, intramedullary and extramedullary lesions in the cases which were previously categorized as SCIWORA. SCIWORA is commonly seen in paediatric population and its reported incidence in literature ranges from 4 to 66% (2-4). Very few cases of SCIWORA have been reported in adult population and majority of these cases are in cervical spine (5). The thoracic involvement in SCIWORA is unusual and we present such a case with review of literature.

2. Case Presentation

A 40 year-old male presented with paraplegia following road traffic accident. There was no history of loss of consciousness, seizures, vomiting or previous neurological disorder. On examination there was no sensation below T12 (twelfth thoracic vertebrae) dermatome level. Motor strength as per MRC (medical research council) grading in upper limb was grade 5/5, while it was 0/5 in both the lower limbs. There was a complete loss of bladder and bowel

function. There was diffuse tenderness extending from T8 (eighth thoracic vertebrae) to T11 (eleventh thoracic vertebrae) vertebral level. Deep and superficial tendons reflexes were absent in bilateral lower limbs. The rest of the systemic examination was unremarkable. There was no evidence of any other musculoskeletal injuries. Radiographic examination of the whole spine (Figure 1 A and B) was carried out, but there was no significant radiological finding correlating with the clinical examination. Computerized tomography (CT) Scan of the whole spine was performed, which revealed the fracture of the head of 11th rib (Figure 2 A and B). Magnetic resonance imaging of the whole spine showed hyperintense lesions in the spinal cord at the T9 and T10 vertebrae on T2 weighted images and STIR sequences with no blooming noted in gradient sequences, suggestive of non-haemorrhagic cord contusion (Figures 3 A and B). The patient was managed with complete bed rest. He was given intravenous methylprednisolone 30 mg/kg bolus followed by 5.4 mg/kg/h infusion over next 23 hours as per NASCIS 3 (national acute spinal cord injury) protocol (6). There was significant sensory improvement in bilateral lower limbs 10 days after the injury. Patient had regained bowel and bladder control and the muscle strength was grade 4/5 at two months following injury. His last follow-up was at eight months following injury and there was no further muscular or sensory improvement.

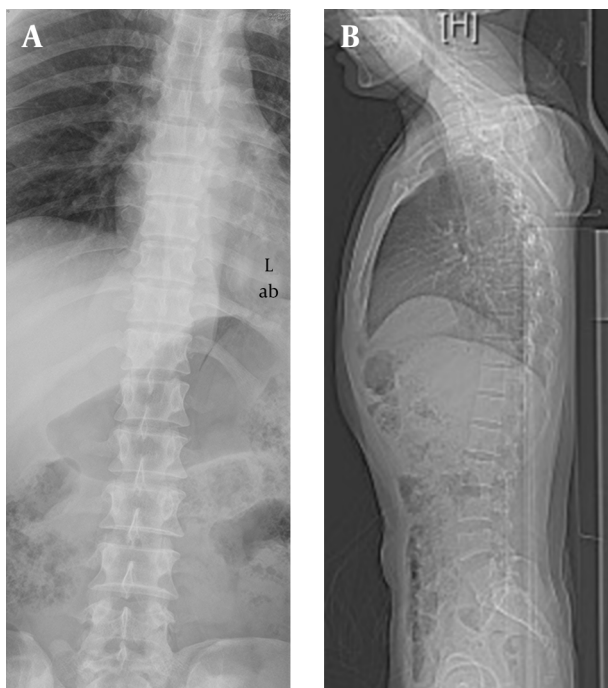


Figure 1. Radiographs of Spine (Anteroposterior and Lateral) Showing no Sign of Vertebral Column Disruption

3. Discussion

SCIWORA accounts for approximately 18% of the paediatric spinal cord injuries (7). The higher incidence of SCIWORA in children has been attributed to the inherent soft tissue elasticity of spine in children (7). There is a decrease in elasticity of the spine as the child grows leading to higher incidence of bony fractures in adults. Cervical spine injuries account for the vast majority of the SCIWORA cases in both adult and paediatric population. Crooks et al. (8) had reported higher chances of this type of injury in cases of cervical spondylosis. The rarity of SCIWORA in thoracic spine may be due to the splinting effect of the rib cage, which prevents translation of the vertebral column and subsequent spinal cord injury. However, longitudinal distraction due to hyperextension can lead to thoracic cord injury (9). Pang et al. (1) had described that damage to the vertebral body, neural arch or facet joint dislocation occurs prior to any injury to the spinal cord. The mechanism of injury in SCIWORA is still debatable. Hirsh et al. (10) were the first to report a case of traumatic thoracic SCIWORA in an adult. They had reported injury to the posterior ligamentous complex of the spine along with injury to the spinal cord and postulated that the mechanism of injury could have been hyperflexion of the thoracic spine. Samsani et al. (11) had reported bilateral traction injury of the sciatic nerve with subsequent transmission of the force to the spinal cord level and hence its injury. Koizumi et al. (12) had attributed the etiology of injury to the direct trauma. Van Buul et al. (13) had reported traction injury to the thoracic nerve

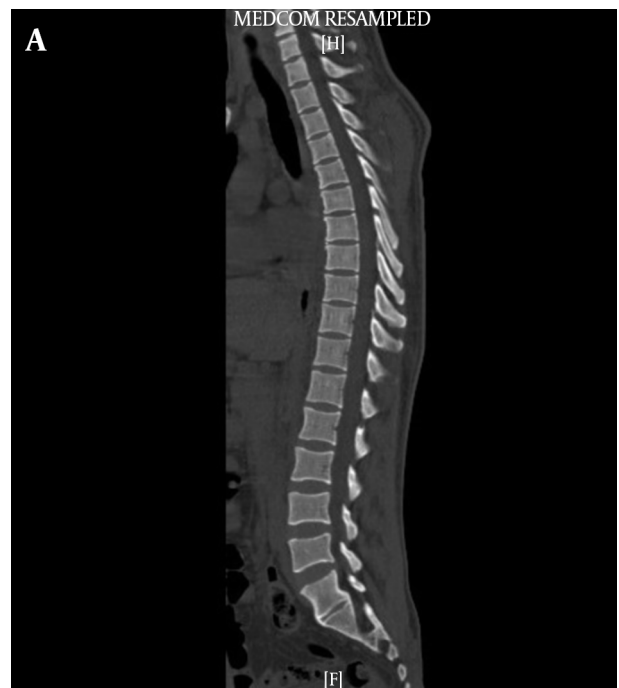

Figure 2. Computerized Tomography of Spine Showing Fracture of Head of 11th Rib and no Other Bony Injury

root leading to its avulsion and force transmission to the spinal cord and cord injury. In our case, the patient was hit by a four-wheeler from behind while he was pushing another vehicle. The displacement at the spinal column could have been prevented by the rib cage (though one of the rib heads got fractured due to the impact) but hyperextension at the thoracic spine with buckling of ligamentum flavum could have led to the injury of the spinal cord. The few reported cases in the literature of the thoracic SCIWORA were managed conservatively (9, 13). Some of the authors had included steroids as part of their treatment along with bed rest. The use of steroids is

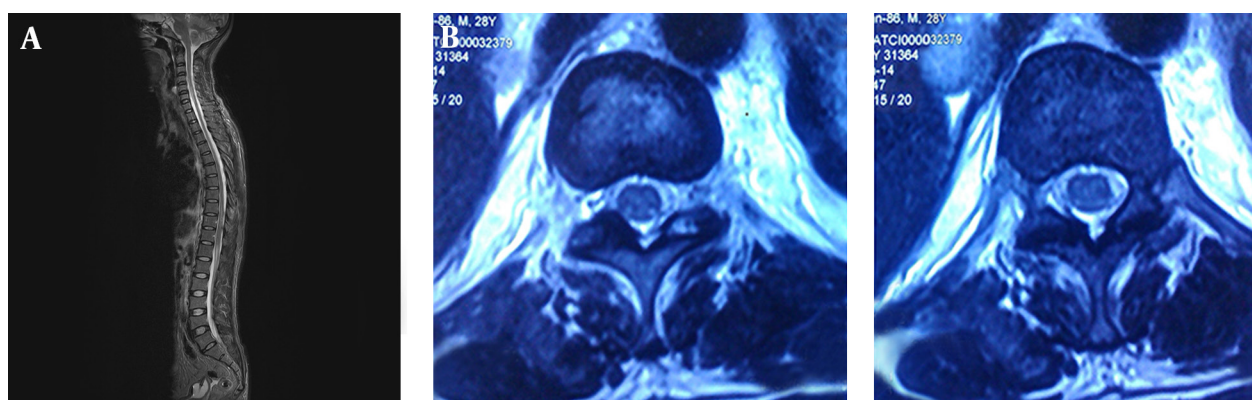


Figure 3. Magnetic Resonance Imaging (MRI) of the Whole Spine Showing Hyperintense Lesions in the Spinal Cord at the T9 and T10 Vertebrae

Table 1. Review of Cases of Traumatic Dorsal Spine Spinal Cord Injury Without Radiological Abnormality Reported in Literature ^a

Authors	Year	Age, y	Gender	Mode of Injury	Level of Injury (Dermatome)	Frankel Grade at Admission	MRI/CT Findings	Management	Frankel Grade at Last Follow up
Koizumi et al. (12)	2002	19	female	road traffic accident	T5	C	fracture dislocation at T4 and T5 costovertebral junction with hyperintense lesion in T2 weighted images at T5 level	methyl prednisolone and bed rest	E
Koizumi et al. (12)	2002	63	male	industrial accident	T4	A	hyper intense lesion in T2 weighted images extending between T4 and T5 vertebral level	methyl prednisolone and bed rest	A
Samsani et al. (11)	2003	17	male	road traffic accident	L2	A	hyper intense lesion at the T10 vertebral level in T2WI.	bed rest	A
Van Buul et al. (13)	2009	27	male	road traffic accident	T8	A	hyper intense lesions in T2WI extending from T3 to T5 with nerve root avulsion at T4 vertebral level and T5	bed rest	D
Present study	2014	40	male	road traffic accident	T12	A	hyper intense lesions in the spinal cord at the T9 and T10 vertebrael level on T2 weighted images and STIR sequences with no blooming noted in gradient sequences, suggestive of non-haemorrhagic cord contusion	methyl prednisolone and bed rest	D

^a Abbreviations: MRI, magnetic resonance imaging; CT, computerized tomography.

not supported by substantial evidence in these cases. The predictor of neurological recovery in paediatric SCIWORA has been the neurological status at the time of admission (14) and this holds true in adult cases as well. Incomplete spinal cord syndromes had shown better results in terms of neurological improvement than complete injuries (15). The appropriate management in the adult SCIWORA cases is still debatable and not well-established. SCIWORA is rare entity and usually occurs in children; however, an increasing number of SCIWORA cases in adults are being reported in the literature (Table 1) Routine radiographs and sometimes even computerized tomography can

miss this injury and SCIWORA should be suspected in these cases of spinal injury presenting with neurological involvement.

Authors' Contributions

Kavin Khatri and Kamran Farooque developed the original idea and protocol; Kavin Khatri abstracted and analyzed the data, wrote the manuscript, and is a guarantor; Ankit Gupta and Vijay Sharma contributed to the development of the protocol, abstracted the data, and prepared the manuscript.

References

1. Pang D, Wilberger JE, Jr. Spinal cord injury without radiographic abnormalities in children. *J Neurosurg.* 1982;**57**(1):114-29.
2. Choi JU, Hoffman HJ, Hendrick EB, Humphreys RP, Keith WS. Traumatic infarction of the spinal cord in children. *J Neurosurg.* 1986;**65**(5):608-10.
3. Hill SA, Miller CA, Kosnik EJ, Hunt WE. Pediatric neck injuries. A clinical study. *J Neurosurg.* 1984;**60**(4):700-6.
4. Ruge JR, Sinson GP, McLone DG, Cerullo LJ. Pediatric spinal injury: the very young. *J Neurosurg.* 1988;**68**(1):25-30.
5. Tewari MK, Gifti DS, Singh P, Khosla VK, Mathuriya SN, Gupta SK, et al. Diagnosis and prognostication of adult spinal cord injury without radiographic abnormality using magnetic resonance imaging: analysis of 40 patients. *Surg Neurol.* 2005;**63**(3):204-9.
6. Bracken MB, Shepard MJ, Holford TR, Leo-Summers L, Aldrich EF, Fazl M, et al. Administration of methylprednisolone for 24 or 48 hours or tirilazad mesylate for 48 hours in the treatment of acute spinal cord injury. Results of the Third National Acute Spinal Cord Injury Randomized Controlled Trial. National Acute Spinal Cord Injury Study. *JAMA.* 1997;**277**(20):1597-604.
7. Burke DC. Traumatic spinal paralysis in children. *Paraplegia.* 1974;**11**(4):268-76.
8. Crooks F, Birkett A. Fractures and dislocations of the cervical spine. *Br J Surg.* 1944;**31**(123):252-65.
9. Kothari P, Freeman B, Grevitt M, Kerslake R. Injury to the spinal cord without radiological abnormality (SCIWORA) in adults. *J Bone Joint Surg Br.* 2000;**82**(7):1034-7.
10. Hirsh LF, Duarte L, Wolfson EH. Thoracic spinal cord injury without spine fracture in an adult: case report and literature review. *Surg Neurol.* 1993;**40**(1):35-8.
11. Samsani SR, Calthorpe D, Geutjens G. Thoracic spinal cord injury without radiographic abnormality in a skeletally mature patient: a case report. *Spine (Phila Pa 1976).* 2003;**28**(4):E78-80.
12. Koizumi M, Ueda Y, Iida J, Matsuyama E, Yoshikawa T, Takakura Y, et al. Upper thoracic spinal cord injury without vertebral bony lesion: a report of two cases. *Spine (Phila Pa 1976).* 2002;**27**(21):E467-70.
13. Van Buul G, Oner FC. Thoracic spinal cord injury without radiographic abnormality in an adult patient. *Spine J.* 2009;**9**(3):e5-8.
14. Hadley MN, Zabramski JM, Browner CM, Rekeate H, Sonntag VK. Pediatric spinal trauma. Review of 122 cases of spinal cord and vertebral column injuries. *J Neurosurg.* 1988;**68**(1):18-24.
15. Grabb PA, Pang D. Magnetic resonance imaging in the evaluation of spinal cord injury without radiographic abnormality in children. *Neurosurgery.* 1994;**35**(3):406-14.