



# Clinical and radiological outcomes of polymethyl methacrylate vertebroplasty versus posterior spinal fixation in thoracolumbar burst fracture: a randomized clinical trial

Hamed Yazdanpanah <sup>1</sup>, Majid Reza Farrokhi <sup>1,2\*</sup>, Seyed Reza Mousavi <sup>1</sup>, Keyvan Eghbal <sup>1</sup>, Mohammad E. Majd <sup>3</sup>, Mohammad Safdari <sup>4</sup>

<sup>1</sup> Department of Neurosurgery, Shiraz University of Medical Sciences, Shiraz, Iran

<sup>2</sup> Shiraz Neuroscience Research Center, Shiraz University of Medical Sciences, Shiraz, Iran

<sup>3</sup> Indiana University School of Medicine, Indianapolis, Indiana, USA

<sup>4</sup> Department of Neurosurgery, Khatam-Al-Anbia Hospital, Zahedan University of Medical Sciences, Zahedan, Iran

\* **Corresponding author:** Majid Reza Farrokhi, MD, Professor of Neurosurgery. Chamran Hospital, Shiraz Neurosciences Research Center, Shiraz University of Medical Sciences, Shiraz, Iran. **E-mail:** farrokhimr@yahoo.com

**Received:** 22 January 2024 **Revised:** 28 February 2024 **Accepted:** 7 March 2024 **e-Published:** 8 March 2024

## Abstract

**Background:** Management of thoracolumbar burst fracture patients with no neurological deficit is still a controversial issue. Vertebroplasty, as a minimally invasive technique, can be used as an alternative to open surgical procedures to avoid major complications.

**Objectives:** This study aims to compare the radiological and clinical outcomes of standalone polymethyl methacrylate (PMMA) vertebroplasty (VP), as a relatively safe, feasible, and uncomplicated procedure, to those of short-segment posterior spinal fixation (POSF).

**Methods:** A prospective, single-blind, randomized clinical trial was conducted between April 2021 and May 2022. The patients were randomly devoted to group I or PMMA vertebroplasty (n=25), and group II or POSF (n=25). The vertebral height reduction and kyphotic deformity as well as visual analog scale (VAS) and Oswestry Disability Index (ODI) were assessed to determine the radiological and clinical results, respectively.

**Results:** The vertebral height reduction, kyphotic deformity, VAS, and ODI were decreased significantly compared to preoperative treatment in both groups. There was a significant reduction in group I in comparison to group II in kyphotic deformity (5.16 vs. 8.45, P = 0.04, respectively) and vertebral height reduction (8.78 vs. 13.47, P = 0.01, respectively), especially after 12 months. Moreover, the VAS and ODI scores were significantly reduced in VP group than POSF group (2.16 vs. 4.51 and 10.36 vs. 16.10, respectively), 12 months postoperatively.

**Conclusion:** Due to the lack of neurological deficit, vertebroplasty with fewer intraoperative complications, low incidence of side effects, immediate spinal stability, and better postoperative pain control can be considered as an alternative for thoracolumbar burst fractures.

**Keywords:** Thoracolumbar burst fracture, Pedicle screw fixation, Vertebroplasty, Anterior vertebral height, Kyphotic deformity.

## Introduction

Thoracolumbar spine and burst injuries are the most common site and type of spinal fractures respectively,<sup>[1]</sup> and the burst subtype comprises 30% of the total.<sup>[2]</sup> Thoracolumbar burst fractures were first described by Holdsworth in 1963 and defined as vertebral body fractures due to axial compression with or without flexion forces.<sup>[3]</sup> The AOSpine thoracolumbar spine injury classification (AOSTLIC) system provides guidance for clinicians regarding the best treatment option selection for

the intended patients. With this classification system, thoracolumbar fractures were divided into type A (compression), type B (tension band disruption), and type C (displacement/translation) injuries. Neurological deficits are more common in type C (55%) and type B fractures (32%) than in type A. Besides, type A and B injuries are subdivided into five (A0, A1, A2, A3, and A4) and three (B1, B2, B3) subtypes, respectively. The A3 type, as an incomplete burst fracture, involves a single endplate; whereas the A4 type is a complete burst fracture with the

involvement of both endplates. Type-A injuries can either occur alone or in combination with type B or C injuries.<sup>[4]</sup> Without the neurological deficit, conservative or surgical treatment represents a common procedure for type A patients;<sup>[5]</sup> although conservative treatment includes bed rest, postural reduction, casting/bracing, and analgesia for at least six to eight weeks.<sup>[5,6]</sup> In burst fractures, the stability of the vertebral body is an important factor to choose the treatment procedure. Surgical treatment should be done in unstable burst fractures due to post-traumatic kyphosis, neurological deficits, and persistent radiating pain.<sup>[7]</sup>

Two surgical approaches of posterior or a combination of anterior and posterior have been known as the popular ones to stabilize thoracolumbar fractures.<sup>[8-10]</sup>

Long-term bedridden patients represent more complications, and on the other hand, traditional surgical treatment is associated with high morbidity followed by infection, pseudarthrosis, and instrumentation failure.<sup>[11]</sup>

Less invasive techniques conducted in the last decades and are associated with minimal destruction of the overlying soft tissues, smaller incisions, less blood loss, shorter hospital stay, less opioid use, and decreased postoperative pain compared to open surgery techniques. In addition, these techniques represent faster recovery and rehabilitation than open surgery procedures.<sup>[7,12]</sup>

Vertebroplasty (VP), as a safety and efficacy technique, offers a minimally invasive alternative to traditional surgery for thoracolumbar burst fractures and prevents complications of major open surgical procedures.<sup>[13]</sup> Percutaneous augmentation with polymethyl methacrylate (PMMA), as one of the multiple minimally invasive spine surgeries, is widely used for osteoporotic compression fractures.<sup>[14-16]</sup> In addition, few publications have been conducted on percutaneous augmentation in non-osteoporotic fractures; which indicated primary vertebral stability, relieved the patient's pain after the surgical procedure, and returned to their normal life within 3 months.<sup>[17,18]</sup> In the VP method, the posterior bilateral transpedicular cement augmentation reinforces the strength of fractured vertebral bodies. Furthermore, in order to reduce PMMA leakage to the epidural space, high-viscous PMMA cement should be created and injected into the space between fractured bone fragments; that can be easily performed in the hands of a skilled surgeon.

## Objectives

This study aimed to undertake a randomized controlled trial of vertebroplasty vs. posterior spinal fixation (POSF) to compare the long-term radiological outcomes (vertebral

height reduction and kyphotic deformity) as well as visual analog scale (VAS) and Oswestry Disability Index (ODI) (as clinical outcomes) between these two groups.

## Methods

### Study design

This prospective, single-blind, randomized clinical trial study was conducted on patients who were admitted and operated in the Chamran and Emtiaz hospitals of Shiraz University of Medical Sciences, Shiraz, Iran, between April 2021 and May 2022. Thoracolumbar burst fractures (type A3, A4, B1+A3, or B1+A4) were diagnosed in 50 patients out of 57. Patients were randomly allocated to one of the two treatment groups: group I or PMMA vertebroplasty (n=25), and group II or short-segment posterior spinal fixation (n=25) [Figure 1]. The long-term clinical (VAS and ODI) and radiologic (vertebral height reduction and kyphotic deformity) outcomes were compared in these two groups. This clinical trial was registered at the Iranian Registry of Clinical Trials (IRCT) under the registration number IRCT20180604039980N2 on 21/03/2021. This study was approved by the Medical Research Ethics Committee of Shiraz University of Medical Sciences, Shiraz, Iran (approval number: IR.SUMS.REC.1398.378). Written informed consent was obtained from all the patients and/or their legal guardian(s) before surgery.

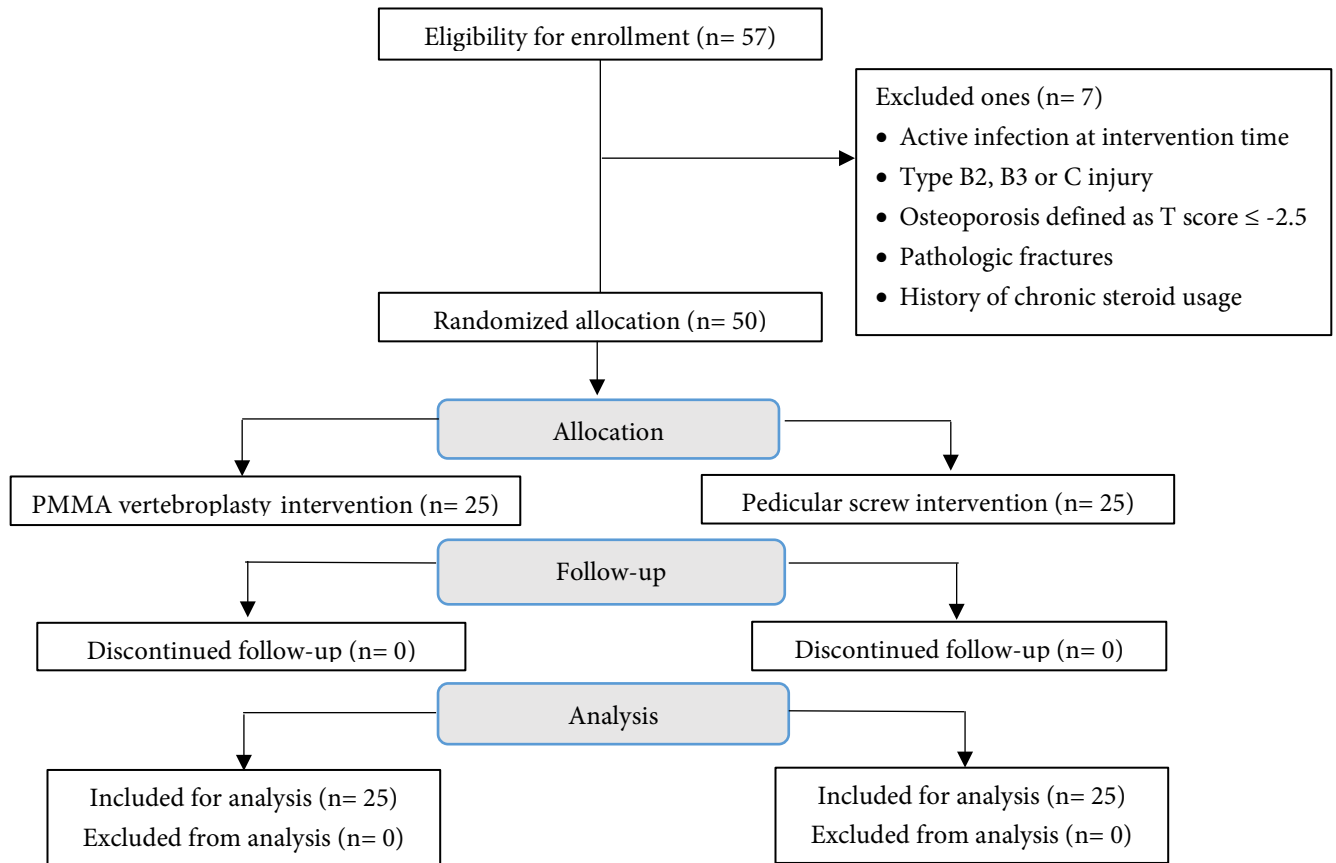
### Participants

Patients (age range: 18-65 years) with the following features were included in the study: traumatic fracture, burst fracture (40-60% vertebral height reduction; 20-40% canal compromise; kyphotic angulation 20 to 40 degrees), hemodynamic stability, fracture below T6 level, type A3, A4, B1+A3 or B1+A4 fracture in the last 2 weeks, intact neurological exam, and one- or two-level fractures. Exclusion criteria included patients with any documented active infection at intervention time, type B2, B3, or C injury according to the AOSTLIC system, osteoporosis defined as T score  $\leq -2.5$  according to medical history or a recent bone mineral density, pathologic fractures, and history of chronic steroid usage.

The patients, 36 men (72 %) and 14 women (28 %) were enrolled from April 2021 to May 2022 (Mean age  $40.58 \pm 13.55$  years; range 19-62). Group I (Mean age  $41.65 \pm 15.22$  years; range 20-62) consisted of 16 men (64%) and 9 women (36%) and group II (Mean age  $39.56 \pm 10.24$  years; range 25-54) consisted of 20 men (80%) and 5 women (20%). Patients were evaluated by spine X-ray, computed tomography scan, and magnetic resonance imaging. Patient demographic information, including sex, age, body mass index (BMI), days between trauma and surgery,

hospitalization time, surgery time, duration of radiation exposure, and smoking habits were documented. Fracture characteristics, including the type of fracture according to the AOSTLIC system, the number of injured levels,

mechanism of trauma (fall, motor vehicle, others) and level of injury (thoracic, thoracolumbar, lumbar) were taken for each case.



**Figure 1.** Diagram detailing the study process from enrollment to analysis.

### Randomization and masking

Eligible cases were determined randomly by selecting a sealed envelope that was prepared beforehand and sorted through computerized random allocation software to generate random numbers. A neurosurgery resident performed randomization after the inclusion of the patients into the study. The patients were randomly divided into group I or PMMA vertebroplasty (n=25), and group II or POSF (n=25). As it was a single-blind trial, the data analysts and evaluators were kept blinded in this study.

### Intervention

In the VP group, a radiolucent operating room table (carbon fiber) and mobile C-arm fluoroscopic were used to obtain anterior-posterior and lateral images. Each case was positioned prone on an anti-decubitus device. After the induction of general anesthesia and radiological level check (the fractured level, the size of the fractured vertebra, and contiguous levels), the skin was incised

approximately 1 cm on the projection of the right pedicle of the fractured vertebra. Using sterile techniques, an 11-gauge needle was inserted into the vertebral body via a bilateral transpedicular approach. Following placement of the needle, about 4 to 8 cc of high-viscosity PMMA bone cement (Mendec Spine-kit<sup>®</sup>, Tecres, Verona, Italy) was injected under the guide of C-arm fluoroscopy, until the surgeon fills the vertebral body satisfactorily. The wound was closed at the end of the operation. Patients were then mobilized within a day unless the residual pain did not allow them.

In the short-segment fixation group, patients were placed in the same position as the VP group. The skin was incised and Bovie cautery was used to carry the incision through the subcutaneous fat to the fascia and muscle. After the facets and transverse processes (TP) were exposed, the junction of TP and the superior articular process was used as a landmark to identify the pedicle entry point. A Pedicle probe was inserted to navigate down the isthmus of the

pedicle into the vertebral body. After the pedicle track was created free-hand, pedicle screw, long arm monoaxial (6.5 × 45-mm screws and 5-mm rods at most of the time), was inserted after checking with C-Arm fluoroscopy. Instrumentation was performed on one level above and one below the fractured level [8]. Because all the patients were neurologically intact, we did not perform a laminectomy. After final fluoroscopic examinations, the surgical site was washed with a saline solution mixed with gentamicin, and wound closure was done meticulously.

#### Clinical and radiological assessment

The radiological outcomes were determined with vertebral height reduction and kyphotic deformity (Cobb's method) before the operation, and on postoperative days

of 2, 6, and 12 months after surgery. Moreover, the clinical outcomes were assessed with VAS and ODI criteria before the operation, at 2, 6, and 12 months postoperatively. The VAS was used to evaluate the severity of postoperative pain, which scores ranging from 1 (as no pain) to 10 (as excruciating pain) [17]. A questionnaire based on the ODI (version 2) was used to assess the Quality of life (QOL). This questionnaire is designed to measure functional disability comprising 6 items in 10 dimensions, including pain severity, individual caring, walking, sitting, lifting, standing, sleeping, normal life, going on to trip, and changes in the pain degree [Table 1]. Because of the English language of ODI, its Persian translation (with permission from Tehran University of Medical Sciences) was used to be completed by patients.

**Table 1.** Correlation between ODI score ranges and disability severity

Degree of disability severity	Interpretation
Minimal disability (0–20%)	- The patient can cope with most living activities. Usually, no treatment is indicated apart from advice on lifting sitting, and exercise
Moderate disability (21–40%)	- The patient experiences more pain and difficulty with sitting, lifting, and standing. Travel and social life are more difficult and they may be disabled from work. Personal care, sexual activity, and sleeping are not grossly affected and the patient can usually be managed by conservative means
Severe disability (41–60%)	- Pain remains the main problem in this group but activities of daily living are affected. These patients require a detailed investigation
Cripple, affecting all aspects of life (61–80%)	- Back pain impinges on all aspects of the patient's life. Positive intervention is required
Exaggeration of disease symptoms (81–100%)	- These patients are either bed-bound or exaggerating their symptoms

This table is obtained from Baker D. (1989) [19]

#### Statistical analysis

All data were analyzed in SPSS software version 23.0 (SPSS Inc., Chicago, USA). Paired Samples *t* Test, Independent Samples *t* Test, and Chi-square test were used to compare the differences within and between the two groups. All data were represented as mean ± standard deviation (SD) and frequencies characterized as a percentage. The analysis process with  $P < 0.05$  was considered statistically significant.

#### Ethical considerations

The study was conducted in accordance with the Declaration of Helsinki. This study was approved by the Medical Research Ethics Committee of Shiraz University of Medical Sciences, Shiraz, Iran (approval number: IR.SUMS.REC.1398.378). The written informed consent was obtained from all the patients and/or their legal guardian(s) before surgery.

## Results

#### Patients' characteristics

The mean age of participants in group I (VP) was slightly older than that of group II (POSF), but it was not significant ( $P=0.633$ ). There was no significant difference between these two groups due to gender ( $P=0.208$ ). Moreover, no significant differences were identified in BMI, smoking status, and days between trauma and surgery between the two groups ( $P>0.05$ ). The average operative time was reduced in Group I compared to Group II ( $44.08\pm 3.47$  min; range 40–50 min vs.  $128.92\pm 8.64$  min; range 120–145 min, respectively,  $P<0.001$ ). Additionally, the mean duration of hospitalization in Group I was lower than Group II ( $29\pm 6.93$  hours; range 24–36 vs.  $92.64\pm 15.66$  hours; range 72–120, respectively,  $P<0.001$ ). The duration of exposure to radiation in Group I was  $45.04\pm 5.42$  (40–55) seconds, while it was  $15.72\pm 3.9$  (12–22) seconds in Group II ( $P<0.001$ ) [Table 2].

**Table 2.** Demographic information and surgical outcomes of patients operated with vertebroplasty and pedicular screw fixation methods

Characteristics	Vertebroplasty group	Pedicular screw group	P-value
Number of patients (n)	25	25	1.00
Male/female (n)	16/9	20/5	0.208
Mean age (years)	41.65 ± 15.22	39.56 ± 10.24	0.633
BMI	22.28 ± 5.12	23.84 ± 4.68	0.874
Days between trauma and surgery	6.40 ± 0.71	5.16 ± 0.45	0.560
Hospitalization time (hours)	29 ± 6.93	92.64 ± 15.66	0.000*
Operation time (minutes)	44.08 ± 3.47	128.92 ± 8.64	0.000*
Duration of exposure to radiation (seconds)	45.04 ± 5.42	15.72 ± 3.91	0.000*
Smoker/non-smoker	9/25	10/25	0.512

BMI: Body mass index, P < 0.05 indicated as significant

The thoracolumbar junction fracture was the most common in 70 % of the patients (35/50). All patients in both groups suffered from type A4 injury at first (51 %) and type A3 injury later (21 %). Besides, six patients (24 %) in group I and seven patients (30 %) in group II had sustained type B1 in combination with type A3 or A4 injuries. The major traumatic mechanism was motor vehicle accidents (50 %), followed by falls (46 %). Out of 50 patients, 41 (82 %) patients had single-level thoracolumbar burst fractures, and 9 (18 %) patients had two-level thoracolumbar burst fractures. In terms of the functional disability of patients after 24 months, the vertebroplasty group showed a moderate degree of 84%, while the pedicular screw fixation group indicated a moderate degree of 76% [Table 3].

#### Radiological evaluations

The postoperative kyphotic deformity (Cobb's method) and vertebral height reduction significantly decreased in both groups compared with the preoperative values (P < 0.001) [Table 4, Figure 2 & Figure 3]. The postoperative vertebral height reduction and kyphotic deformity represented a significant reduction in the VP group compared to POSF group, especially after 12 months (P= 0.010 vs. P= 0.042, respectively). Also, the correction loss of kyphotic deformity and height reduction was about twice in the POSF group in comparison to the VP group (P= 0.031 vs. P= 0.044, respectively) [Table 5].

#### Clinical evaluations

In the postoperative treatment, VAS and ODI scores represented significantly lower values than the preoperative treatment in both groups (P= 0.01 and P < 0.001, respectively) [Table 4]. Moreover, these scores in the VP group showed a significant reduction in

comparison to the POSF group, especially after 6 and 12 months (P<0.05); which can indicate a faster improvement in the VP group [Table 5].

**Table 3.** Fracture characteristics of patients in vertebroplasty and pedicular screw fixation groups

Characteristics	Vertebroplasty group N (%)	Pedicular screw group N (%)
<b>Mechanism of trauma</b>		
Motor vehicle accident	12 (48)	13 (52)
Fall	12 (48)	11 (44)
Others	1 (4)	1 (4)
<b>Number of injured Level</b>		
Single level	21 (84)	20 (80)
Double level	4 (16)	5 (20)
<b>Level of injury</b>		
Thoracic	4 (16)	4 (16)
Thoracolumbar	18 (72)	17 (68)
Lumbar	3 (12)	4 (16)
<b>Type of burst fractures</b>		
A3	5 (20)	6 (23)
A4	14 (56)	12 (47)
A3+B1	4 (16)	3 (13)
A4+B1	2 (8)	4 (17)
<b>Functional disability after 24 m</b>		
Minimal: 0-20	21 (84%)	19 (76%)
Moderate: 21-40	4 (16%)	6 (24%)
Severe: 41-60	0	0
<b>Total</b>	<b>25</b>	<b>25</b>

**Table 4.** Comparing radiological and clinical outcomes before and after a 12-month follow-up in vertebroplasty and pedicular screw fixation groups

Groups	Variables	Preoperation (Mean ± SD)	Postoperation (12 m) (Mean ± SD)	P-value
<b>Vertebroplasty</b>	kyphotic deformity (°)	15.81 ± 9.78	5.16 ± 1.08	0.000*
	height reduction (%)	35.88 ± 11.85	8.78 ± 11.83	0.000*
	VAS score	8.68 ± 0.75	2.16 ± 1.47	0.010*
	ODI score	89.12 ± 6.75	10.36 ± 8.42	0.000*
<b>Pedicular screw fixation</b>	kyphotic deformity (°)	18.16 ± 7.93	8.45 ± 9.63	0.000*
	height reduction (%)	36.61 ± 13.09	13.47 ± 8.53	0.000*
	VAS score	9.00 ± 0.78	4.51 ± 1.36	0.010*
	ODI score	88.24 ± 5.61	16.10 ± 7.18	0.000*

VAS: Visual analog pain scale, ODI: Oswestry disability index, P < 0.05 indicated as significant

**Table 5.** Comparison of the radiological and clinical outcomes between vertebroplasty and pedicular screw fixation groups after 2, 6, and 12 months postoperatively

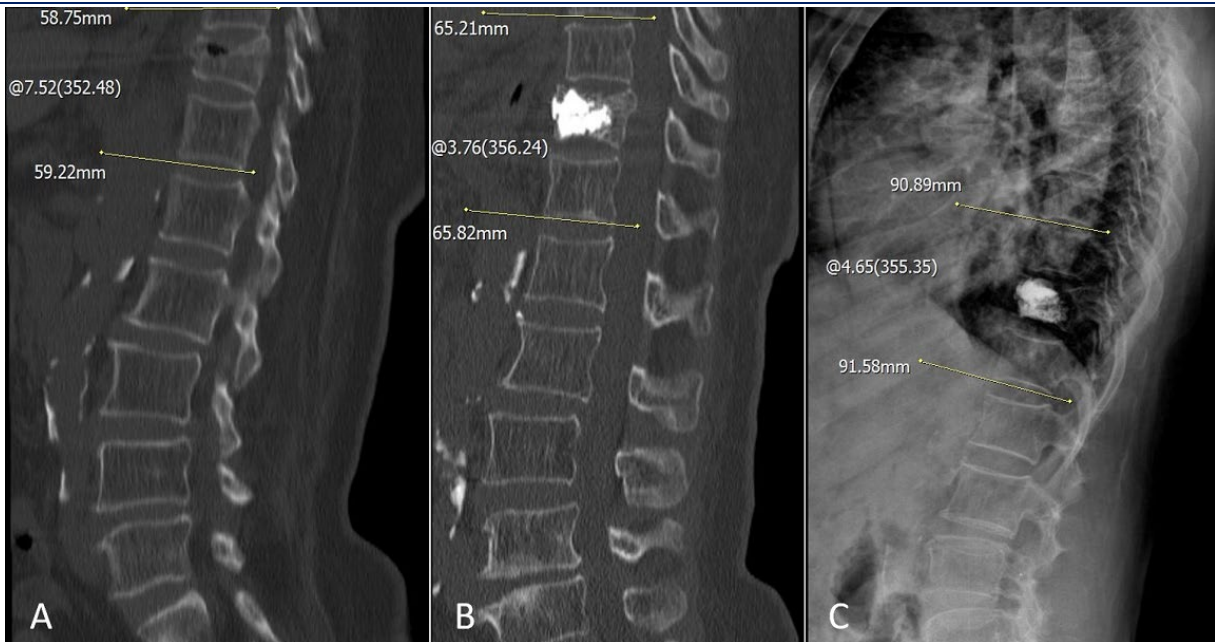Parameters	Vertebroplasty (Mean ± SD)	Pedicular screw fixation (Mean ± SD)	P-value
<b>Preop kyphotic deformity (°)</b>	15.81 ± 9.78	18.16 ± 7.93	0.189
<b>Postop kyphotic deformity (°)</b>			
Early	12.82 ± 9.86	15.16 ± 1.62	0.410
2 months	10.05 ± 4.22	13.24 ± 7.39	0.304
6 months	7.94 ± 8.76	10.16 ± 8.03	0.058
12 months	5.16 ± 1.08	8.45 ± 9.63	0.042*
Correction loss	2.12 ± 5.16	4.25 ± 4.56	0.031*
<b>Preop height reduction (%)</b>	35.88 ± 11.85	36.61 ± 13.09	0.839
<b>Postop height reduction (%)</b>			
Early	23.88 ± 8.41	25.48 ± 8.64	0.869
2 months	20.24 ± 11.71	22.52 ± 8.47	0.110
6 months	12.21 ± 13.11	17.84 ± 8.48	0.021*
12 months	8.78 ± 11.83	13.47 ± 8.53	0.010*
Correction loss	4.93 ± 9.51	7.99 ± 5.75	0.044*
<b>Preop VAS score</b>	8.68 ± 0.75	9.00 ± 0.78	0.141
<b>Postop VAS score</b>			
2 months	3.24 ± 1.63	5.48 ± 1.41	0.040*
6 months	2.32 ± 1.07	4.76 ± 1.33	0.020*
12 months	2.16 ± 1.47	4.51 ± 1.36	0.010*
<b>Preop ODI score</b>	89.12 ± 6.75	88.24 ± 5.61	0.601
<b>Postop ODI score</b>			
6 months	12.41 ± 8.12	16.86 ± 6.72	0.042*
12 months	10.36 ± 8.42	16.10 ± 7.18	0.033*

VAS: Visual Analog pain Scale, ODI: Oswestry Disability Index, P < 0.05 indicated as significant

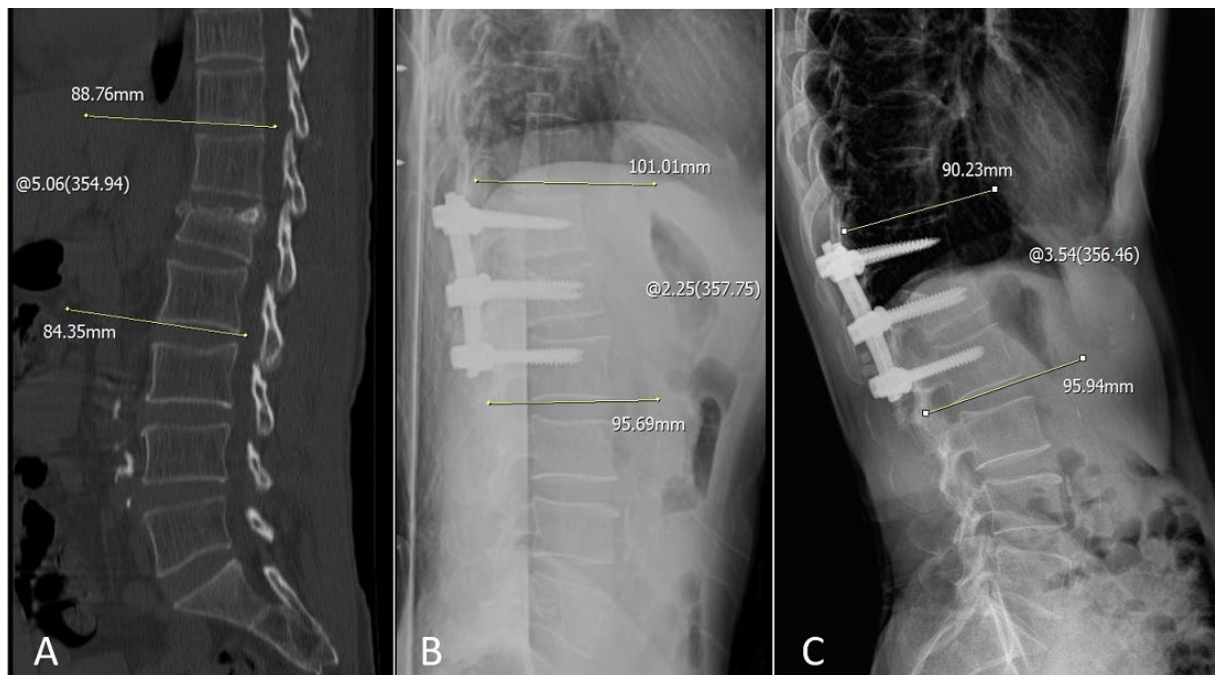**Discussion**

Typically thoracolumbar burst fractures often occur in the T10-L2 region, and most of them are a result of high-energy injuries.<sup>[20]</sup> The proper treatment of thoracolumbar burst fractures with no neurological deficit is still a controversial issue.<sup>[5,18]</sup> The therapeutic strategy ranges

from conservative to operative treatments. Long-term bedridden patients face progressive residual deformity, unrelieved pain, neurological dysfunction, pulmonary complications, and depression; although elimination of surgical complications and affordable has been stated as the main reasons of conservative treatment proponents.<sup>[13,21]</sup>



**Figure 2.** (A) A 60-year-old woman with T11 burst fracture after a fall from 3-m height. (B) Postoperative thoracolumbar CT scan of T11 fracture treated with vertebroplasty, showing no obvious bone cement leakage and good diffusion of bone cement. (C) 6-month follow-up, X-ray films displayed the vertebral height and Cobb's angle was well recovered.



**Figure 3.** (A) Sagittal CT scan of a 45-year-old man with a burst fracture of L1 after a collision in a traffic accident. (B) Postoperative scan demonstrates T12-L2 instrumentation. (C) Thoracolumbar 6-month follow-up X-ray representing the stability of the thoracolumbar spine and good arrangement of fractures and Cobb's angle was recovered a little.

Short-segment pedicle screw fixation has been considered as the most common surgical treatment for thoracolumbar burst fractures in comparison with conservative treatment; it leads to effective and faster pain relief, correction of kyphosis, and reduces the period of immobility.<sup>[8]</sup> However, long-term clinical studies have demonstrated surgical morbidities and disadvantages,

including instrumentation failure, blood loss, long periods of hospital rest, iatrogenic permanent muscle deformity, and paraspinal muscle injuries.<sup>[22]</sup>

Surgical treatment should be preferred for stabilizing acute unstable thoracolumbar fractures due to post-traumatic kyphosis, neurological deficits, and persistent radiating pain.<sup>[7]</sup>

Based on analyzing the time trend of annual publication outputs, a promising future is expected ahead for a minimally invasive approach to the spine; they reduce postoperative back pain, operation time, and blood loss and cause the patient to return to work faster; however, the functional results may not be different from the outcomes of open techniques.<sup>[22,23]</sup> Vertebroplasty is a minimally invasive technique with less overall treatment burden. It is not as complicated as open surgery, nor is it as simple as conservative procedures, so we can differentiate it from both strategies.<sup>[20]</sup>

Several studies have reported the role of percutaneous cement augmentation alone or in combination with other methods in the treatment of traumatic spinal injuries.<sup>[24-27]</sup> Vertebroplasty has been proven as a proper approach for both osteoporotic and vertebral fracture patients.<sup>[13-17]</sup> However, few publications have been conducted regarding percutaneous augmentation in non-osteoporotic fractures. In a retrospective study, Wen et al. represented a potential alternative technique of vertebroplasty tool-aided surgery for treating single-level thoracolumbar fractures. Their findings showed that this tool can restore the height of the fractured vertebrae more effectively and reduce the VAS and ODI than traditional surgery.<sup>[28]</sup> Chen et al. evaluated six patients with thoracolumbar spine burst fracture treated with percutaneous vertebroplasty; their findings indicated that the pain decreased from  $84.3 \pm 5.4$  mm at baseline to  $34.7 \pm 4.4$  mm on the third day after the operation in all patients. Furthermore, the mobility was at least 2 levels of improvement at 12 months postoperative.<sup>[29]</sup> In a study, the percutaneous curved vertebroplasty (PCVP) method was conducted to treat thoracic and lumbar vertebral compression fractures. According to their findings, PCVP group represented less complicated surgery with shorter duration, lower complication rate, lowest bone cement leakage rate, and faster recovery after operation versus unilateral and bilateral percutaneous vertebroplasty.<sup>[30]</sup>

In a prospective controlled trial study in patients with thoracic-lumbar spine fractures, the vertebroplasty group represented a faster improvement in VAS score and functional ability compared to conservative treatment; which is consistent with our findings.<sup>[17]</sup> Moreover, Choi et al. indicated vertebroplasty as a promising treatment choice for burst fractures by reducing the VAS score and holding the fractured bone fragments tightly.<sup>[13]</sup>

The current research is a comparative prospective randomized case-control study that was conducted between standalone PMMA vertebroplasty and short-segment pedicular screw fixation groups in the

management of thoracolumbar burst fractures (AO/type A3, A4, or B1 in combination with A3 or A4). In this study, the fractured height restoration and correction of kyphosis in the PMMA vertebroplasty group represented significant differences compared to the POSF group, all in the absence of related complications. In addition, in the vertebroplasty group, pain intensity (VAS), recovery in activities of daily living (ODI), hospitalization, and operation time were decreased in comparison to the POSF group. In the VP group, patients were discharged from the hospital within 24-36 hours post-operatively, without the risk of traditional open surgery. Therefore, the current findings were similar to the results of the former studies, which indicated the efficacy of vertebroplasty for patients with thoracolumbar burst fractures. The posterior bilateral transpedicular cement augmentation reinforces the strength of fractured vertebral bodies and provides anterior support by quickly filling the space between fractured bone fragments; it will accelerate the pain relief and ability of the patient to start the activity.<sup>[31]</sup>

Although, in the vertebroplasty approach, PMMA leakage to the epidural space may be seen, in surgeon-experienced hands its related complications are rarely accrued. Moreover, understanding the fracture pattern, as well as the creation of high-viscous PMMA cement and allowing it to harden before injection, following the use of low pressure can reduce the rate of leakages, which depends on sticking to a proper time frame;<sup>[32]</sup> the cement leakage was not seen in any of our patients. Finally, in the absence of neurological deficit, PMMA vertebroplasty with fewer intraoperative complications and low incidence of side effects can be a valid and alternative method for the treatment of thoracolumbar burst fractures.

## Conclusions

Treatment of thoracolumbar fractures has remained controversial. However, vertebroplasty confers additional advantages, such as shorter hospitalization and operation time, less manipulation in the muscles and tissues around the spine, less blood loss, and fewer complications. In addition, it provides immediate spinal stability and better postoperative pain control compared to patients without vertebroplasty.

## Acknowledgment

The authors thank the Neuroscience Research Center members for their contributions to this work.

## Competing interests

The authors declare that they have no competing interests.



## Abbreviations

Polymethyl methacrylate: PMMA; Vertebroplasty: VP; Posterior spinal fixation: POSF; AOSpine thoracolumbar spine injury classification: AOSTLIC; Visual analogue scale: VAS; Oswestry Disability Index: ODI; Bone mineral density: BMD; Transvers processes: TP.

## Authors' contributions

Conceptualization: MRF, HY; Data curation: HY; Formal analysis: MEM; Investigation: KE; Methodology: SRM; Project administration: MRF; Resources: HY, MS; Software: KE; Supervision: MRF; Writing – original draft: MRF, HY; Writing – review & editing: MRF, HY. All authors read and approved the final manuscript. All authors take responsibility for the integrity of the data and the accuracy of the data analysis.

## Funding

This investigation was supported by the Vice Chancellor for Research, Shiraz University of Medical Sciences, Shiraz, Iran (Grant no. 97-01-01-17322). The funder had no role in the study design, data collection, data analysis and manuscript preparation.

## Role of the funding source

None.

## Availability of data and materials

The data used in this study are available from the corresponding author on request.

## Ethics approval and consent to participate

The study was conducted in accordance with the Declaration of Helsinki. This study was approved by the Medical Research Ethics Committee of Shiraz University of Medical Sciences, Shiraz, Iran (approval number: IR.SUMS.REC.1398.378). The written informed consent was obtained from all the patients and/or their legal guardian(s) before surgery.

## Consent for publication

By submitting this document, the authors declare their consent for the final accepted version of the manuscript to be considered for publication.

## References

- Rajasekaran S, Kanna RM, Shetty AP. Management of thoracolumbar spine trauma. *Indian J orthopaedics* 2015; 49(1):72-82. doi:10.4103/0019-5413.143914 PMID:25593358 PMCID:PMC4292328
- Leucht P, Fischer K, Muhr G, Mueller EJ. Epidemiology of traumatic spine fractures. *Injury* 2009;40(2):166-72. doi:10.1016/j.injury.2008.06.040 PMID:19233356
- Holdsworth F. Fractures, dislocations, and fracture-dislocations of the spine. *J Bone Joint Surgery Br* 1963;45(1):6-20. doi:10.1302/0301-620X.45B1.6
- Reinhold M, Audigé L, Schnake KJ, Bellabarba C, Dai L-Y, Oner FC. AO spine injury classification system: a revision proposal for the thoracic and lumbar spine. *Eur Spine J* 2013;22(10):2184-201. doi:10.1007/s00586-013-2738-0 PMID:23508335 PMCID:PMC3804719
- Yi L, Jingping B, Gele J, Wu T, Baolier X. Operative versus non-operative treatment for thoracolumbar burst fractures without neurological deficit. *Cochrane Database of Systematic Reviews* 2006(4). doi:10.1002/14651858.CD005079.pub2
- Butler J, Walsh A, O'byrne J. Functional outcome of burst fractures of the first lumbar vertebra managed surgically and conservatively. *Int orthopaedics* 2005;29(1):51-4. doi:10.1007/s00264-004-0602-x PMID:15538564 PMCID:PMC3456945
- Hong S-H, Suh S-P, Yeom J, Kim J-Y, Lee SG, Han J-W. Minimally Invasive Spine Surgery versus Open Posterior Instrumentation Surgery for Unstable Thoracolumbar Burst Fracture. *Asian Spine J* 2021;15(6):761. doi:10.31616/asj.2020.0572 PMID:34000798 PMCID:PMC8696052
- Farrokhi M-R, Razmkon A, Maghami Z, Nikoo Z. Inclusion of the fracture level in short segment fixation of thoracolumbar fractures. *Eur spine j* 2010;19(10):1651-6. doi:10.1007/s00586-010-1449-z PMID:20495932 PMCID:PMC2989232
- Oprel PP, Tuinebreijer WE, Patka P, den Hartog D. Combined anterior-posterior surgery versus posterior surgery for thoracolumbar burst fractures: a systematic review of the literature. *open orthopaedics j* 2010;4:93. doi:10.2174/1874325001004020093 doi:10.2174/1874325001004010093 PMID:21283533 PMCID:PMC3031139
- Alpantaki K, Bano A, Pasku D, Mavrogenis AF, Papagelopoulos PJ, Sapkas GS, et al. Thoracolumbar burst fractures: a systematic review of management. *Orthopedics* 2010;33(6):422-9. doi:10.3928/01477447-20100429-24 PMID:20806752
- Siebenga J, Leferink VJ, Segers MJ, Elzinga MJ, Bakker FC, Henk JTM, et al. Treatment of traumatic thoracolumbar spine fractures: a multicenter prospective randomized study of operative versus nonsurgical treatment. *Spine* 2006;31(25):2881-90. doi:10.1097/01.brs.0000247804.91869.1e PMID:17139218
- Bruckner J, Hashmi S, Williams SK, Ludwig S, editors. Minimally invasive surgery for the management of thoracolumbar burst fractures. *Seminars in Spine Surgery*; 2021: Elsevier. doi:10.1016/j.semss.2021.100848
- Choi YH, Pee YH, Jang I-T. Percutaneous vertebroplasty: can it be an alternative treatment option for thoracolumbar burst fractures? *J Korean Society Geriatric Neurosurgery* 2020;16(2):67-70. doi:10.51638/jksgn.20.00472
- Martikos K, Greggi T, Faldini C, Vommaro F, Scarale A. Osteoporotic thoracolumbar compression fractures: long-term retrospective comparison between vertebroplasty and conservative treatment. *Eur Spine J* 2018;27(2):244-7. doi:10.1007/s00586-018-5605-1 PMID:29675674
- Kim JH, Yoo SH, Kim JH. Long-term follow-up of percutaneous vertebroplasty in osteoporotic compression fracture: minimum of 5 years follow-up. *Asian Spine J* 2012;6(1):6.

- doi:10.1016/j.spinee.2012.08.037 doi:10.4184/asj.2012.6.1.6  
PMid:22439082 PMCID:PMC3302917
16. Farrokhi MR, Alibai E, Maghami Z. Randomized controlled trial of percutaneous vertebroplasty versus optimal medical management for the relief of pain and disability in acute osteoporotic vertebral compression fractures. *J Neurosurgery: Spine* 2011;14(5):561-9. doi:10.3171/2010.12.SPINE10286 PMid:21375382
  17. D'Oria S, Dibenedetto M, Squillante E, Somma C, Hannan CJ, Giraldi D, et al. Traumatic compression fractures in thoracolumbar junction: vertebroplasty vs conservative management in a prospective controlled trial. *J NeuroInterventional Surgery* 2022;14(2):202-6. doi:10.1136/neurintsurg-2020-017141 PMid:33758067
  18. Zhang Q, Luo J, Yang L-z, Li R-l, Li Z-f, Yan X-p, et al. Percutaneous vertebroplasty repairs non-osteoporotic single-segmental vertebral traumatic compression fractures. *Chinese J Tissue Engineering Research* 2016;20(4):534.
  19. Baker D. The Oswestry disability index revisited. *Back pain: new approaches to rehabilitation and education* 1989:174-86.
  20. Trungu S, Forcato S, Bruzzaniti P, Frascchetti F, Miscusi M, Cimatti M, et al. Minimally Invasive Surgery for the Treatment of Traumatic Monosegmental Thoracolumbar Burst Fractures. *Clinical Spine Surgery* 2019;32(4):E171-E6. doi:10.1097/BSD.0000000000000791 PMid:31048604
  21. Shen W-J, Shen Y-S. Nonsurgical treatment of three-column thoracolumbar junction burst fractures without neurologic deficit. *Spine* 1999;24(4):412-5. doi:10.1097/00007632-199902150-00024 PMid:10065527
  22. Kocis J, Kelbl M, Kocis T, Návrát T. Percutaneous versus open pedicle screw fixation for treatment of type A thoracolumbar fractures. *European J Trauma and Emergency Surgery* 2020;46(1):147-52. doi:10.1007/s00068-018-0998-4 PMid:30167741
  23. Pishnamaz M, Oikonomidis S, Knobe M, Horst K, Pape H, Kobbe P. Open versus percutaneous stabilization of thoracolumbar spine fractures: a short-term functional and radiological follow-up. *Acta Chir Orthop Traumatol Cech* 2015;82(4):274-81. doi:10.55095/achot2015/042
  24. Oner FC, Verlaan J-J, Verbout AJ, Dhert WJ. Cement augmentation techniques in traumatic thoracolumbar spine fractures. *Spine* 2006;31(11S):S89-S95. doi:10.1097/01.brs.0000217950.60516.e6 PMid:16685242
  25. ZARYANOVA AV, Park DK, Khalil JG, Baker KC, Fischgrund JS. Cement augmentation in vertebral burst fractures. *Neurosurgical focus* 2014;37(1):E5. doi:10.3171/2014.5.FOCUS1495 PMid:24981904
  26. Elnoamany H. Percutaneous vertebroplasty: a first line treatment in traumatic non-osteoporotic vertebral compression fractures. *Asian Spine Journal* 2015;9(2):178. doi:10.4184/asj.2015.9.2.178 PMid:25901227 PMCID:PMC4404530
  27. Cho D-Y, Lee W-Y, Sheu P-C. Treatment of thoracolumbar burst fractures with polymethyl methacrylate vertebroplasty and short-segment pedicle screw fixation. *Neurosurgery* 2003;53(6):1354-61. doi:10.1227/01.NEU.0000093200.74828.2F PMid:14633301
  28. Wen Y, Zhou H, Liao Y, He Y, Wang F, Li J. Posterior pedicle screw fixation combined with transpedicular bone grafting for treatment of single-level thoracolumbar fractures with the aid of a vertebroplasty tool. *J International Medical Research* 2022;50(2):1-13. doi:10.1177/03000605221081290 PMid:35216537 PMCID:PMC8891865
  29. Chen J-F, Lee S-T. Percutaneous vertebroplasty for treatment of thoracolumbar spine bursting fracture. *Surgical neurology* 2004; 62(6):494-500. doi:10.1016/j.surneu.2003.10.049 PMid:15576113
  30. Cheng Y, Liu Y. Percutaneous curved vertebroplasty in the treatment of thoracolumbar osteoporotic vertebral compression fractures. *J Int Med Res* 2019;47(6):2424-33. doi:10.1177/0300060519836917 PMid:31007103 PMCID:PMC6567733
  31. Chen J, Xu C, Yu J. Vesselplasty for the treatment of osteoporotic vertebral compression fractures with peripheral wall damage: a retrospective study. *British J Neurosurgery* 2020:1-11. doi:10.1080/02688697.2020.1862054 PMid:33319625
  32. Saad A, Botchu R, James S. The Rates of Cement Leakage Following Vertebroplasty in Osteoporotic versus Metastatic Disease. *Indian J Radiology and Imaging* 2022;32(01):046-50. doi:10.1055/s-0042-1744122 PMid:35722636 PMCID:PMC9200480

**How to Cite this Article:**

Yazdanpanah H, Farrokhi MR, Mousavi SR, Eghbal K, E Majd M, Safdari M. Clinical and Radiological Outcomes of Polymethyl Methacrylate Vertebroplasty versus Posterior Spinal Fixation in Thoracolumbar Burst Fracture: a randomized clinical trial. *Arch Trauma Res.* 2024;13(1):49-58. doi: 10.48307/atr.2024.437121.1083