

# Complex Pinna Lacerations and their Management

Kartikesh Gupta, Rachit Sood<sup>1</sup>, Priyanshi Awasthi<sup>2</sup>, Amit Kumar<sup>1</sup>

Department of Otorhinolaryngology, Government Medical College, Kanker, Chattisgarh, <sup>1</sup>Department of Otorhinolaryngology and Head-Neck Surgery, All India Institute of Medical Sciences, Rishikesh, Uttarakhand, <sup>2</sup>Department of Ophthalmology, All India Institute of Medical Sciences, Patna, Bihar, India

## ORCID:

Kartikesh Gupta: <https://orcid.org/0000-0002-9930-7154>

Rachit Sood: <https://orcid.org/0000-0002-4644-1296>

Priyanshi Awasthi: <https://orcid.org/0000-0003-4288-6447>

Amit Kumar: <https://orcid.org/0000-0002-6491-5010>

## Abstract

**Context:** External ear trauma is common and may range from simple abrasion to complete amputations. The auricle is an exposed part of the head which can be easily damaged by road traffic accidents. Early treatment in such patients may prevent cosmetic disfigurement and multiple sittings for secondary repair. **Aims:** The aim was to study the presentation and management of patients with cartilage-involving untidy complex lacerations of the pinna. This article mainly focuses on the management of such traumatic ear wounds. **Settings and Design:** A retrospective study was done in a tertiary care hospital from January 2019 to January 2020. **Subjects and Methods:** All patients with cartilage-involving complex lacerations of the pinna were included in the study. **Results:** All patients had a successful recovery. The pinna wounds have a higher success rate even after primary repair despite the wound often being contaminated. **Conclusions:** Primary repair of the pinna is a straightforward and reliable treatment method as it can survive even with a narrow pedicle (superiorly or inferiorly based) due to its rich dual vascular network. Cosmesis being the realm of plastic surgeons, the majority of such cases can be managed with primary wound closure by otolaryngologists and physicians without causing much inconvenience, delay, and higher cost to the patient.

**Keywords:** Ear auricle, ear pinna, injury, laceration, trauma

## INTRODUCTION

Ears are prominent parts of the body, and hence these are prone to trauma.<sup>[1]</sup> Ear lacerations are common and can be caused by a variety of injuries such as road traffic accidents, assaults, occupational (sports), and fall from heights. The most common cause of ear trauma is road traffic accidents (35.9%).<sup>[2]</sup> Shearing injury of the pinna causes the disruption of the adhered cartilage with its perichondrium and overlying skin.<sup>[3,4]</sup> It commonly presents with pain and open wounds on examination. Laceration increases the risk of infection, which delays healing.<sup>[3]</sup> Surgical repair remains the mainstay of treatment. If not managed in time, these can be disfiguring to the patient. One of the challenges that remains crucial for such injuries is the prevention of complications such as chondritis (secondary to infection), primarily then cosmesis. Here, we present 15 cases of cartilage-involving injuries of the pinna due to trauma and their management. Existing literature is scarce on such injuries.

## Terminology

Pinna laceration is a deep cut that is still attached to the body. Avulsion or amputation terms are misleading and reserved for segment separation from the body. Complex pinna laceration is any laceration extending into the external auditory canal, involving cartilage break or disrupting the perichondrium of either side.

## Anatomy

The pinna cartilage lies between the adherent lateral and loose medial surface of the skin, maintaining its vascular

**Address for correspondence:** Dr. Amit Kumar,  
Department of Otorhinolaryngology and Head-Neck Surgery, All  
India Institute of Medical Sciences, Rishikesh, Uttarakhand, India.  
E-mail: [dramit4111@gmail.com](mailto:dramit4111@gmail.com)

This is an open access journal, and articles are distributed under the terms of the Creative Commons Attribution-NonCommercial-ShareAlike 4.0 License, which allows others to remix, tweak, and build upon the work non-commercially, as long as appropriate credit is given and the new creations are licensed under the identical terms.

**For reprints contact:** [WKHLRPMedknow\\_reprints@wolterskluwer.com](mailto:WKHLRPMedknow_reprints@wolterskluwer.com)

**How to cite this article:** Gupta K, Sood R, Awasthi P, Kumar A. Complex Pinna Lacerations and their Management. Arch Trauma Res 2022;11:129-32.

**Received:** 15-07-2022,

**Revised:** 02-10-2022,

**Accepted:** 03-10-2022,

**Published:** 20-12-2022.

## Access this article online

### Quick Response Code:



**Website:**  
[www.archtrauma.com](http://www.archtrauma.com)

**DOI:**  
10.4103/atr.atr\_38\_22

supply from the perichondrium. It can be 1–3 mm thick.<sup>[5]</sup> The vascular supply of pinna is by arcade formed by branches of the superficial temporal artery (STA) laterally and posterior auricular artery (PAA) medially [Figure 1].<sup>[4,6,7]</sup> STA runs into parotid-masseteric fascia in parotid region and enters the superficial temporal fascia in temple 1 cm superior and 1 cm anterior to tragus. STA has three branches – superior, middle, and inferior. The superior branch makes an arcade with branches of PAA around the superior third of the helical rim, whereas the middle branch connects with perforating branches of PAA (helical root perforator, inferior crus perforator, and conchal perforators) as well as the inferior branch of STA. The inferior branch of STA connects with the antitragal perforator of PAA.<sup>[6]</sup> PAA runs in the conchomastoid groove. These vascular anastomoses occur in the lateral aspect of the pinna between perforating branches from PAA (which pierce the auricular cartilage posteriorly and emerge anteriorly) and branches from STA.<sup>[6]</sup> PAA gives three to seven branches, out of which two to four pierce auricular cartilage to reach the lateral surface, supply, and anastomose at the helical rim, scaphoid fossa, concha, and lobule.<sup>[5,6,8]</sup>

## SUBJECTS AND METHODS

Fifteen cases who presented to us in the emergency department with complex pinna lacerations between January 2019 and January 2020 were included in the study. All the cases were surgically repaired after counseling and consent.

### Surgery

Tetanus toxoid injection was given prophylactically. Ring block around the pinna was given with 2% Xylocaine and 1:200000 adrenaline. The wound was irrigated using normal saline and a 10% povidone-iodine solution. Necrosed tissue was debrided, and primary skin closure was done in one layer

using a nylon 5.0 cutting suture, sparing the cartilage, and perichondrium [Figure 2]. Wounds extending to the external auditory canal were packed with a medicated wick. Contour dressing was done using multiple cotton balls soaked with 2% Betadine solution all around the pinna. The dressing was changed after 48 h and after 5 days of wound repair. The patient was sent on oral amoxicillin + clavulanate 625 mg thrice daily regimen for 7 days along with analgesic. Sutures were removed on day 7, ointment neomycin was applied, and the wound was kept open. The patient who developed perichondritis/chondritis during treatment was additionally given oral ciprofloxacin 500 mg twice daily for 7 days. All patients had a successful outcome at 2 weeks.

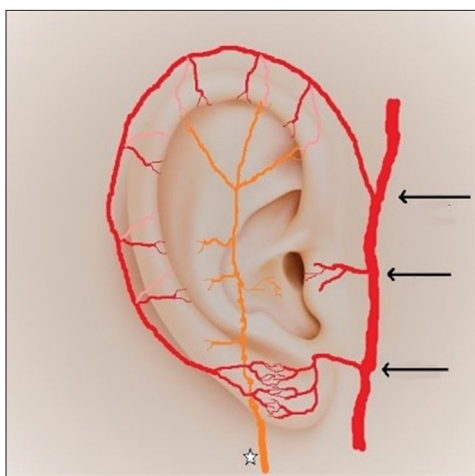
## RESULTS

The mean age of patients was 26.9 years, with the majority being male (93%). Etiologies included road traffic accident (73.3%), assault (20%), and fall from height (6.6%). The mean duration of presentation in the emergency was 6.06 h posttrauma, with a range of 2–14 h. Laceration of the pinna involved the lateral surface of the pinna in 100% of cases, whereas the medial surface in 80%. All wounds were open, contaminated, and lacerated (contained dirt and sand) as per Rank-Wakefield classification with cartilage destruction. All the wounds were repaired primarily. Only 13.3% of cases developed postrepair chondritis of the pinna, which was treated successfully with oral ciprofloxacin. One patient had small devitalized tissue in the wound, who presented 14 h after injury, which was excised and then repaired. One patient also had an arterial bleed (spurter) at the presentation from the superior branch of STA, which was ligated first, and then the wound was repaired. All patients finally had a successful outcome and did not require second-stage surgery [Figure 2 shows a photograph of 2 patients]. No skin necrosis was found in any postoperative cases and pinna's contour was maintained.

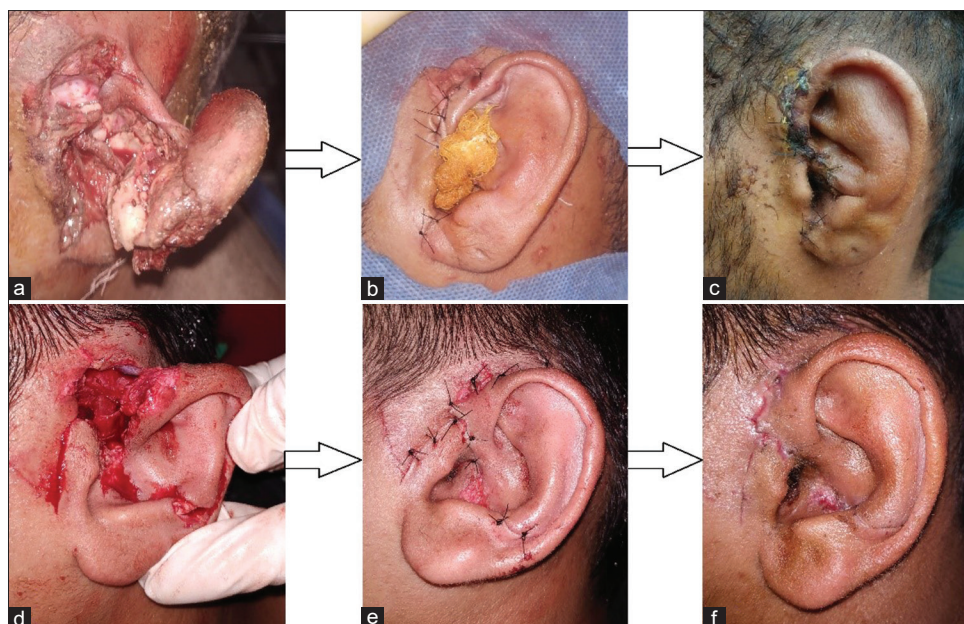
## DISCUSSION

Ear pinna plays its role in facial esthetics. Its importance is known from the old times of Susruta, which mentioned its reconstruction using a cheek flap.<sup>[9]</sup> The etiology of ear trauma is mainly due to road accidents, fights, and contact sports injuries.<sup>[2,4]</sup> The ideal way of treating any traumatic wound includes preoperative preparation, wound repair with or without debridement, postoperative medications, and dressing. All such cases need tetanus prophylaxis.<sup>[4,5]</sup> Regarding the timing of intervention, the sooner, the better, as in our study. This not only gives a better result but also reduces complications.<sup>[1]</sup>

Skin adhering to the pinna's lateral surface poses a challenge to repair in cases with skin loss compared to its medial surface. The dual supply of pinna makes it unique for wound healing. Helical arcades and perforators from the crus of the helix to the lobule are responsible for the survival of complex pinna lacerations.<sup>[6,8]</sup> It is suggested in studies that pinna can survive



**Figure 1:** Artistic diagram of the helical arcade and its position on the helical rim in the upper third of the helical rim along with anastomoses (Posterior branch is shown in dull red and anterior branch in bright red); → Superficial temporal artery and its branches (in bright red) (black arrows indicate superior/middle/inferior anterior auricular arteries); \*Posterior auricular artery and branches (in orange)



**Figure 2:** Preoperative (a and d), their intraoperative (b and e) and postoperative (c and f) photographs of few patients

even if a single arterial pedicle is left, as seen in our cases where a branch of STA was ligated due to injury or only a narrow pedicle was left.<sup>[8]</sup>

Regarding anesthesia, there are multiple options such as greater auricular nerve block (ultrasound-guided) and ring block of the pinna.<sup>[10]</sup> In our study, none of the patients had any discomfort while undergoing the procedure or any anesthesia complication, which explains the efficacy and safety of ring block in any external ear surgery. This is important not only for otolaryngologists but to all emergency physicians who may need to perform procedures such as drainage of abscess or hematoma of the pinna.

Few studies suggest layer-to-layer suturing involving perichondrium and cartilage first<sup>[2,5]</sup> and then skin using absorbable sutures,<sup>[5]</sup> whereas others suggest suturing only perichondrium and not cartilage.<sup>[11]</sup> In our study, we directly sutured skin to skin, sparing perichondrium, and cartilage using nonabsorbable interrupted sutures in accordance with Eagles *et al.*<sup>[3]</sup> We used 5.0 suture material in all our cases, whereas others recommended 6.0 sutures.<sup>[3]</sup> Medicated wicks have been used for skin laceration extending into EAC, similar to our study.<sup>[5]</sup> Lacerations with tissue loss <2 cm are repaired primarily.<sup>[3]</sup> Margins of the crushed or gangrenous wounds should be debrided, similar to our case.<sup>[12]</sup> Our technique maintained the configuration of the pinna despite the loss of cartilage. Suturing perichondrium in our patients was not feasible as cartilage was torn into multiple small pieces. The reason for cartilage survival in our cases may be due to intact perichondrium on one side in a few cases or supply from overlying skin and subcutaneous tissue. Contour dressing helped maintain the shape and gave the pressure needed for the skin to attach to the underlying cartilage, thereby preventing pressure necrosis. Iodine in contour dressing additionally

protected the wound from getting infected.<sup>[2]</sup> Our study found that pinna can survive even if it is attached to a narrow bridge as small as 1 cm either at the helix or lobule, unlike Lavasani *et al.*<sup>[5,12]</sup>

Decisions regarding the management of such cases depend on surgeons' expertise, resources available in an emergency, time of presentation, and condition of the ear.<sup>[8]</sup> Treatment options for complete avulsed or unviable pinna differ and may include local or regional flap and amputation followed by reconstruction.<sup>[8]</sup> Local flaps such as postauricular island flaps or helical advancement flaps may be needed for cases with a very narrow pedicle or skin loss >2 cm.<sup>[3,5]</sup> Other local flaps are the Limberg flap, Gavello flap technique, Baudet technique, Rhomboid flap, etc.<sup>[13]</sup> Direct attachment is also one option for minor amputations.<sup>[2]</sup> Susruta, Brent, Preaux, and Davis have mentioned many other techniques in the literature.<sup>[9]</sup> Pocket methods are also recommended for amputations of <15 mm.<sup>[2]</sup> For completely avulsed pinna, microvascular reimplantation remains the primary treatment option, if a patient presents in time (within 3 h to a maximum reported 33 h postinjury) with a vital avulsed segment or delayed repair as for microtia can be other option with total amputations.<sup>[2,3,5,14]</sup> Criteria for microvascular repair are suitable vessels, salvageable ear, technical facility, and willing patient.<sup>[14]</sup> Materials that can be used for secondary auricular reconstruction are rib cartilage, auricular cartilage, and porous ethylene.<sup>[2]</sup>

Complications of such injuries may include blood loss (if the vessel is injured), perichondritis/chondritis, and deformity. In our study, we used anti-staphylococcal as the first line similar to other studies,<sup>[3]</sup> and reserved antipseudomonal as the second line for patients who developed perichondritis/chondritis. It is also evident by studies that trauma is the cause for perichondritis in 46% of cases of pinna lacerations.<sup>[15]</sup>

Although evidence is lacking whether to use antibiotics or not, no strong evidence rests regarding the use of antibiotics.<sup>[1,5]</sup> Few studies advocate only one postoperative antibiotic injection,<sup>[2]</sup> whereas few advocate antipseudomonal as first-line or to be used if at all.<sup>[1,4]</sup>

The use of this anatomy not only helps in treating these traumatic wounds but will also help in treating other conditions such as malignancy and arteriovenous malformations of the pinna and utilizing auricular flaps. Primary closure of partially avulsed or complex lacerated pinna wounds is possible and should be the initial treatment of choice in patients unless suitable for reimplantation or if the whole pinna is nonviable.<sup>[7,8]</sup> Primary reattachment should not be considered in bite and crush injuries cases.<sup>[7]</sup> We need further studies for a consensus/guideline on the current practice of its management.

## CONCLUSIONS

Most external ear lacerations require only a single-staged repair and are very easy to manage with proper knowledge. The dual blood supply of pinna by STA and PAA and its interconnections make its primary closure feasible. Its blood supply not only helps in the healing of wounds but may also reduce the risk of infection. Treatment should be as early as possible to achieve a good outcome in such cases. Pinna can survive even if it is attached to a narrow bridge either at the helix or lobule as small as 1 cm. There is no need for routine antipseudomonal antibiotics in each case. Primary reattachment may be an effective way in cases with complex pinna lacerations.

## Acknowledgment

The study has not received funding from any organization or institution and does not involve any potential conflict of interest (financial and nonfinancial). Procedures performed in the study were in accordance with the ethical standards of the institution and with the 1964 Helsinki declaration and its later amendments.

## Financial support and sponsorship

Nil.

## Conflicts of interest

There are no conflicts of interest.

## REFERENCES

1. Williams CH, Sternard BT. Complex Ear Lacerations. Treasure Island (FL): StatPearls Publishing; 2022.
2. Steffen A, Frenzel H. Trauma management of the auricle. *Facial Plast Surg* 2015;31:382-5.
3. Eagles K, Fralich L, Stevenson JH. Ear trauma. *Clin Sports Med* 2013;32:303-16.
4. Thill MP, Horoi M, Ostermann K, Depuydt C, Deschamps M, Ducène C. Acute external ear lesions: Clinical aspects, assessment and management. *B-ENT* 2016;12 Suppl 26:155-71.
5. Lavasani L, Leventhal D, Constantinides M, Krein H. Management of acute soft tissue injury to the auricle. *Facial Plast Surg* 2010;26:445-50.
6. Zilinsky I, Erdmann D, Weissman O, Hammer N, Sora MC, Schenck TL, *et al.* Reevaluation of the arterial blood supply of the auricle. *J Anat* 2017;230:315-24.
7. Zhang C, Teng L, Xu JJ, Lu JJ, Xie F, Yang LY, *et al.* Incomplete ear amputation. *J Craniofac Surg* 2018;29:2231-3.
8. Erdmann D, Bruno AD, Follmar KE, Stokes TH, Gonyon DL, Marcus JR. The helical arcade: Anatomic basis for survival in near-total ear avulsion. *J Craniofac Surg* 2009;20:245-8.
9. Jain LB, Shankarappa M. Ear lobe reconstruction: A complexity simplified. *J Plast Reconstr Aesthet Surg* 2014;67:1751-4.
10. Flores S, Herring AA. Ultrasound-guided greater auricular nerve block for emergency department ear laceration and ear abscess drainage. *J Emerg Med* 2016;50:651-5.
11. Yuen SM, Jennings N. To stitch or not to stitch: A case review: Auricular lacerations involving cartilage management in the emergency department. *Australas Emerg Care* 2018;21:75-9.
12. Aremu SK. Nonmicroscopic reconstruction of subtotally amputated/torn auricles: Report of 3 cases. *Ear Nose Throat J* 2014;93:E1-3.
13. Menon A, Alagesan G. Traumatic partial avulsion of pinna reconstruction with limberg flap. *World J Plast Surg* 2018;7:231-4.
14. Bai H, Tollefson TT. Treatment strategies for auricular avulsions: Best practice. *JAMA Facial Plast Surg* 2014;16:7-8.
15. Kelly H. BET 2: No evidence for prophylactic antibiotics in pinna laceration. *Emerg Med J* 2012;29:777.