

Traumatic Arteriovenous Malformation of Scalp: A Case Report

Esmail Fakharian, Afsaneh Gholipour Baboly¹, Payam Yazdipur²

Department of Neurosurgery, Trauma Research Center, Kashan University of Medical Sciences, ¹Clinical Skills Learning Center, Medical School, Kashan University of Medical Sciences, ²Department of Neurosurgery, Kashan University of Medical Sciences, Kashan, Iran

ORCID:

Esmail Fakharian: <https://orcid.org/0000-0003-0115-8398>

Afsaneh Gholipour Baboly: <https://orcid.org/0000-0002-8160-2657>

Payam Yazdipur: <https://orcid.org/0000-0001-9830-6064>

Abstract

Scalp arteriovenous malformation (SAVM) as a rare lesion may be a complication of head injury. A case and its management are presented in this article and literature is reviewed. A 27-year-old man came to us with a slowly growing pulsatile mass in his right retroauricular and parietal region of the scalp. On examination, there was a compressible mass with loud bruit. Paraclinical studies revealed a large, tortuous tuft of vessels with two different feeders. Intracranial vessels were 3 normal. The lesion excised totally by direct surgical intervention after ligation of its feeders. The patient recovered and discharged without any abnormal findings. Increased number of reports of SAVM in the past decade may be due to improved diagnostic facilities; however, the high incidence of trauma and even its increasing pattern in developing countries may be another important factor.

Keywords: Cirroid aneurysm, head injury, scalp AVM, trauma

INTRODUCTION

Arteriovenous malformation (AVM) of scalp is a relatively rare lesion presenting as a pulsatile growing mass, characterized by subcutaneous arterial and venous fistulous connections without capillary network. AVMs can present with a variety of clinical symptoms including intracranial hemorrhage, seizure, chronic headache, and progressive focal neurologic deficit. These clinical features are correlated with the size of the AVM.

Indications of treatment include cosmetic relief of the pulsatile or nonpulsatile mass, prevention of hemorrhage and other symptoms such as headache and tinnitus. The different treatment strategies available for scalp AVM (SAVMs) are surgical excision, ligation, transarterial, transvenous, direct puncture embolization and electrothrombosis. Its treatment may sometimes be difficult for its high blood flow and the possibility of massive bleeding. In this case report, we describe the clinical course of a patient with a large SAVM.

CASE REPORT

A 27-year-old man referred with a soft mass on his right retroauricular and parietal regions from few years ago. He has

a history of trauma to his head many years ago. An informed consent was obtained from the patient. On examination, there was a 10 cm × 6 cm pulsatile, soft, compressible mass posterior to the right ear. There was bruit over the mass and powerful pulsation in occipital and superficial temporal arteries of the right side. A small scar was visible in the retroauricular region.

Computed tomography scan

Right parieto-occipital scalp mass with normal intracranial content [Figure 1].

Computed tomography angiography

Intracranial blood vessels were normal. There was very large tortuous tuft of vessels in the right parietooccipital region with feeders from the right occipital artery, right superficial temporal artery as well as a small feeder from the left side [Figures 2 and 3].

Address for correspondence: Prof. Esmail Fakharian, Department of Neurosurgery, Trauma Research Center, Kashan University of Medical Sciences, Kashan, Iran.
E-mail: efakharian@gmail.com

This is an open access journal, and articles are distributed under the terms of the Creative Commons Attribution-NonCommercial-ShareAlike 4.0 License, which allows others to remix, tweak, and build upon the work non-commercially, as long as appropriate credit is given and the new creations are licensed under the identical terms.

For reprints contact: reprints@medknow.com

How to cite this article: Fakharian E, Baboly AG, Yazdipur P. Traumatic arteriovenous malformation of scalp: A case report. Arch Trauma Res 2018;7:80-4.

Access this article online

Quick Response Code:



Website:
www.archtrauma.com

DOI:
10.4103/atr.atr_78_18

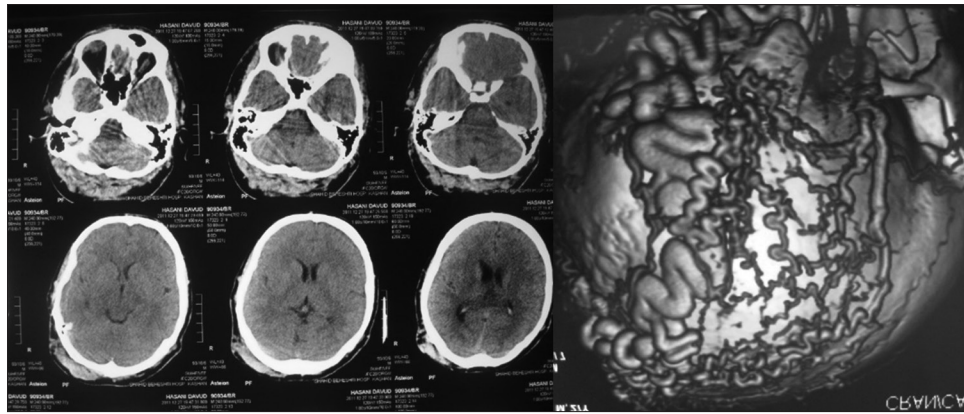


Figure 1: Brain CT scan (Lt.) of the patient showing Rt. parieto-occipital soft tissue lesion, and CT angiography (Rt.) which has revealed dilated, tortuous scalp AVM

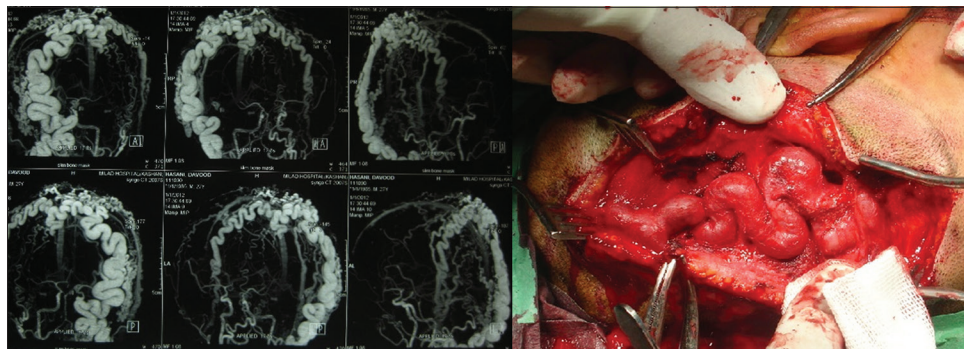


Figure 2: 3D CT angiography of the AVM (Lt.), and the lesion exposed during surgery (Rt.)

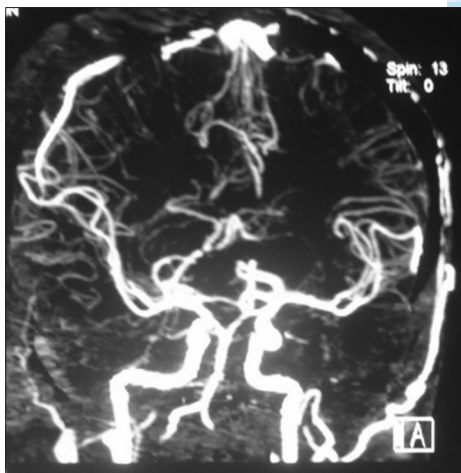

Figure 3: Post-op CT angiography of the presented case

Cerebral angiography

Normal intracranial content, very high flow vascular anomaly in the right parietooccipital region with a very large feeder, most probably occipital artery, from right external carotid artery.

Surgical procedure

An oblique incision was made along sternocleidomastoid muscle and external carotid artery encountered and occipital and superficial temporal arterial branches ligated. Flow to

the vascular anomaly decreased significantly. Then through a right occipitotemporal incision, the very large tortuous vessels exposed and released from the underlying pericranial tissue. The vessels coagulated with bipolar cauterization to decrease flow in them and facilitate their removal [Figure 3]. The feeders in occipital region and convexity ligated and the vascular anomaly excised totally.

Postoperative

The patient's complain recovered completely, and computed tomography (CT) angiography revealed the disappearance of the anomaly.

DISCUSSION

Based on a basic concept established by Mulliken and Glowacki in 1982, the International Society for the Study of Vascular Anomalies has established the current classification system: (1) vascular tumor, including various types of hemangioma, and (2) vascular malformations, including capillary malformation, lymphatic malformation, venous malformation, arteriovenous fistula, AVM, and other combined malformations.^[1]

In the past 15 years, the number of SAVM cases reported in the literature has increased significantly, most likely due to improved diagnostic procedures. The lesion has called with different names, including aneurysm cirsoides, aneurysma

serpentinum, plexiform angioma, and AVF.^[2-9] A limited number of cases of SAVMs presenting with concomitant intracranial aneurysm has been reported.^[2,8]

Differentiating this lesion from others and especially sinus pericranii is an important challenge. Sinus pericranii, a venous anomaly of the scalp, has intracranial communication with the dural sinuses, usually the superior sagittal sinus through diploic veins. Most of the times, it has midline location, has bone defect, and changes in shape in relation to patient position.^[3,10] On the other hand, SAVM as defined earlier is an abnormal arteriovenous communication within the subcutaneous layer of the scalp, with intracranial communication as an exceptional finding.^[7,8,11,12]

AVM of scalp is a rare lesion. It represents an abnormal connection between one or more arteries and one or more draining veins without an intervening capillary bed. Most often it is located subcutaneously but may involve the muscles and bony structures. The involved arteries are often enlarged and tortuous and may arise ipsilateral or contralateral to the lesion.^[13]

While the head composes about 14% of the whole-body surface area, about 50% of the integumentary system AVMs occur in this region.^[4,5,14]

Krayenbuhl and Yasargil found extracranial AVMs in 8.1% of 800 of their AVM cases.^[15] In a study by Visser *et al.*, 53 (4.7%) out of 1131 cases of vascular anomalies were extracranial AVMs, 32 of which were in the head and neck region (2.8%).^[16] In a study for endovascular treatment of head and neck AVMs, 15 (17%) out of 89 cases had scalp lesion.^[13] AVM is 20-fold less common in extracerebral sites than in the intracerebral vasculature.^[17] Kim *et al.* from Korea found 161 (10.1%) cases of AVM from 1,606 patients with vascular anomaly referred to their center over a 15-year period. Sixty (37.3%) of total AVMs, 3.7% of total vascular anomalies were in the head and neck regions. Only 1% of these 60 patients had SAVM.^[18]

There is controversy regarding etiology of AVMs. It may be congenital, traumatic, infectious, inflammatory, and idiopathic in origin. The idiopathic lesions are significantly more common.^[4-7,19-23] About 10% to 40% of SAVMs and in one study^[24] five out of nine patients (55.6%) developed following penetrating or blunt trauma to the scalp.^[2-5,7,8,14,17,20,24-27] Such interventions as craniotomy, hair transplantation,^[28-31] and even intravenous scalp infusions are reported as the implicated traumatic lesions.^[3-5,7]

In this article, we have reviewed 45 case reports of SAVM.^[2-12,14,15,17,19-21,23-49] Overall 178 cases are presented in these papers, 54 (30%) of which had a history of trauma to head. A male to female ratio was 114:64 (1.8:1). The right side scalp vessels were involved in 76 (43%) patients, left side in 62 (35%), right to left ratio of 1.2:1, and midline or bilateral involvement in 20 (11%) of cases. The side of the lesion in 20 (11%) of cases were undetermined.

Rapid increase in size during puberty, pregnancy, and menstruation may be due to increased production of a vascular endothelial growth factor leading to neovascularization and growth of these lesions.^[35,7,23] Neogenesis of AVMs might be triggered by the production of angiogenic factors secondary to venous hypertension induced by an obstruction to venous outflow, reduction of perfusion, ischemia, and aberrant angiogenic activity.^[3]

Traumatic AVMs can occur at any age whereas symptomatic congenital AVMs are not common until the second decade of life.^[17,20,26]

Posttraumatic AVM results either due to direct traumatic communication between artery and vein (laceration theory) or due to canalization of thrombus (disruption theory) by the proliferation of the endothelial cells, from the disrupted vasa vasorum, into the surrounding hematoma, formation of new vessels, and incidental connection to the adjacent veins and formation of numerous arteriovenous connections.^[9,23] Trauma antedated the appearance of lesion by 15 days–30 years with the mean duration of 3.8–8 years in different reports.^[4,7,8,17,24,36,47,49]

The feeding arteries are usually those vessels supplying the scalp. In traumatic cases, the superficial temporal artery, due to its long, unprotected course, is frequently involved,^[17,24] although external carotid artery, occipital and supraorbital arteries are common main arterial feeders.^[8,22,26,38,40,41] The association of SAVM with intracranial ones are rarely reported.^[3,37] Drainage into the intracranial sinuses is also reported,^[8,46] however, this is not reported in trauma cases.^[32]

They are equally distributed in the frontal, parietal, and temporal parts of the scalp.^[7,8,24,30,37,41]

Patients may have a history of the progressive increase in the size of the lesion usually in their third decade of life. The clinical presentations include loud bruit, hemorrhage, throbbing headache, scalp necrosis, pulsation, tinnitus, bleeding tendency, skin erosion, and occasionally cosmetic or functional problems.^[2,8,22,24,42,36,37,38,39,40,47,49] The AVM of the scalp sometimes causes neurologic abnormality.^[8] High output cardiac failure can occur with large fistulae.^[2]

Several imaging modalities can be used to map the vascular malformation and to plan management. Catheter-based angiography, CT, and magnetic resonance (MR) angiography are useful for the diagnosis; however, the former is referred as the gold standard in most of the reports.^[4,5,21,22,24,25,42]

The treatment of this lesion may be difficult for the limited experience with its management, highly complex vascular structure and shunt flow, anatomy and the possible cosmetic complications of surgery.

SAVMs are described into three stages by Matsushige *et al.*:^[20]

- Stage 1: Arterial feeders from one or multiple extracranial carotid origin
- Stage 2: Recruits additional feeders from the intracranial component of the carotid vessels through the bone

- Stage 3: SAVM further develops because of additional supply from pial arteries of the internal carotid artery.

Treatment options include surgical excision, advanced energy devices like Thunderbeat™ which delivers combined ultrasonic and electrically generated bipolar heat energy,^[48] ligation of feeding vessels, transarterial and transvenous embolization and intranidal injection of sclerosant and electrothrombosis, or a combination of them. Indications for treatment include cosmetic, relief of pulsating mass, headache, prevention of hemorrhage, and other symptoms such as tinnitus.^[2,3-49]

Surgical excision is the most common and successful way of the treatment of SAVM. AVM must be completely eliminated because recurrence or enlargement is reported after an incomplete treatment. Recurrence is reported in cases with ligation of superficial temporal artery and multiple coil embolization of the feeders. Reoperation for incomplete excision of the lesion has also reported.^[7,14,34] Recurrence of the lesion has been seen as late as 18 years after complete surgical resection of the malformation.^[16]

Furthermore, CT/MR angiography and/or digital subtraction angiography help to differentiate between low flow and high flow lesions as well as identify the feeders and the nidus. A high flow AVM with a large size, multiple feeders, skin changes, skin necrosis, ulceration, and hemorrhage is the right candidate for surgical treatment, as it gives best chances of cure with better cosmetic results and less chance of recurrence. In the management of low flow AVM, patient age, size of lesion, presenting complains, skin thickness, and intracranial venous sinus communication with the direction of venous blood flow are important factors. Various techniques have been used to control hemorrhage during surgery, for example, percutaneous suture of feeding vessels and interlocking suture along the line of incision. Preoperative embolization has been advocated by some to reduce intraoperative blood loss. Embolization of both feeders and nidus before surgery is safer than embolization of the feeders alone to reduce the risk of excessive hemorrhage. Temporary occlusion of the main feeding artery can help decrease the vascularity of the lesion.^[9,8,23,44,32]

Endovascular treatment has used to either decrease the hemorrhage and facilitate the surgical treatment or directly treat the AVMs. Embolization and endovascular treatment may be insufficient in the treatment of large SAVMs.^[21] Surgical excision resulted in an excellent outcome when used for the management of a small SAVM.^[43] In the event of scalp necrosis and excessive blood loss, total excision is the treatment of choice.^[26]

Barnwell *et al.* reported endovascular treatment of SAVM. This treatment involves coil embolization of the main vessel, followed by injection of embolic agents.^[14,33] Large diffuse lesions represent an enormous treatment challenge and are often impossible to cure. Embolization offers a high treatment success rate of 92.1%, particularly as a palliative and presurgical treatment modality. Complete cure with endovascular means alone is possible for a substantial number

of patients (31.5%) and is usually feasible for small lesions. Surgical/interventional collaboration is imperative to the well-being of these patients.^[13] The importance of palliative treatment should not be underestimated.^[13]

CONCLUSION

SAVM is a rare lesion, which may be seen as a complication of different kinds of head injury. Since, in spite of all preventive measures, the World Health Organization has reported rising incidence of such events in developing countries^[50] on the one hand and the diagnostic facilities for the lesion has improved in recent years, on the other hand, the world community may witness increasing number of the reports of this complex lesion. Surgical excision, in spite of all of the developing therapeutic armamentarium, as in this case can be used as a definite treatment strategy.

Declaration of patient consent

The authors certify that they have obtained all appropriate patient consent forms. In the form the patient(s) has/have given his/her/their consent for his/her/their images and other clinical information to be reported in the journal. The patients understand that their names and initials will not be published and due efforts will be made to conceal their identity, but anonymity cannot be guaranteed.

Financial support and sponsorship

Nil.

Conflicts of interest

There are no conflicts of interest.

REFERENCES

1. Kim JB, Lee JW, Choi KY, Yang JD, Cho BC, Lee SJ, *et al.* Clinical Characteristics of Arteriovenous Malformations of the Head and Neck. *Dermatologic Surgery* 2017;43:526-33. doi: 10.1097/DSS.0000000000000993.
2. Munakomi S, Bhattarai B, Cherian I. Conquering the odds: Cirroid aneurysm with holocranial feeders-staged embolization, excision and grafting. *Asian J Neurosurg*. 2015;10:259-61. doi: 10.7759/cureus.215.
3. Lanzino G, Passacantilli E, Lemole GM Jr, McDougall C, Spetzler RF. Scalp arteriovenous malformation draining into the superior sagittal sinus associated with an intracranial arteriovenous malformation: just a coincidence? Case report. *Neurosurgery* 2003;52:440-3.
4. Senoglu M, Yasim A, Gokce M, Senoglu N. Nontraumatic scalp arteriovenous fistula in an adult. Technical report on an illustrative case. *Surg Neurol* 2008;70:194-7.
5. Hendrix LE, Meyer GA, Erickson SJ. Cirroid aneurysm treatment by percutaneous injection of sodium tetradecyl sulfate. *SurgNeurol* 1996;46:557-61.
6. Chowdhury FH, Haque MR, Kawsar KA, Sarker MH, MomtazulHaque AF. Surgical management of scalp arterio-venous malformation and scalp venous malformation: an experience of eleven cases. *Indian J Plastic Surg* 2013;46:98-107. Available from: <http://dx.doi.org/10.4103/0970-0358.113723>. [Last accessed on 2018 Oct 29].
7. Raheja A, Satyarthee GD, Sharma BS. Single, small, spontaneous, accessory, closed type, frontal sinus pericranii in a child: favorable outcome with surgical excision. *Neurol India* 2013;61:680-3.
8. El Shazly AA, Saoud KMF: Results of surgical excision of cirroid aneurysm of the scalp without preoperative interventions. *Asian J Neurosurg*. 2012;7:191-6. doi: 10.4103/1793-5482.106651.
9. Kyung ML, EJ Kim, BJ Park, KH Kim. Direct Puncture Embolization

- of Scalp Arteriovenous Malformation in a Patient with Severe Hemophilia A: A Case Report. *J Korean Soc Radiol* 2011;65:229-33. doi.org/10.3348/jksr.2011.65.3.229.
10. Yablonsky KJ, Desai S: A Case Report of A Scalp Arteriovenous Malformation After Trauma. *The Journal of Emergency Medicine*, 2011;5:e117-9. doi:10.1016/j.jemermed.2009.07.039.
 11. Fisher-Jeffes ND, Domingo Z, Madden M, de Villiers JC. Arteriovenous Malformations of the Scalp Clinical Study. *Neurosurgery* 1995;36:656-60. Available from: <https://doi.org/10.1227/00006123-199504000-00003>. [Last accessed on 2018 Oct 31].
 12. Moon KS, Yoon SM, Shim JJ, Yun IG. Arteriovenous Malformation of the Scalp: Efficacy of Computed Tomography Angiography. *J Korean Neurosurg Soc* 2005;38:396-8.
 13. Sajikumar NR, Mathai JK, Harold D. Successful surgical management of posttraumatic cirsoïd aneurysm. *Int Surg J* 2017;4:1799-1800. DOI: <http://dx.doi.org/10.18203/2349-2902.isj20171642>.
 14. Gupta R, Kayal A. Scalp arteriovenous malformations in young, case report. *Journal of Pediatric Neurosciences* 2014;9:264-6. DOI:10.4103/1817-1745.147587.
 15. Tabuchi S. Surgical resection of scalp arteriovenous malformation: Case illustration, *Case Reports in Clinical Medicine* 2013;2:3:187-8.
 16. Shenoy SN, Raja A. Scalp arteriovenous malformations. *Neurology India* 2004;52:478-81.
 17. Li D, Heiferman DM, Rothstein BD, Syed HR, Shaibani A, Tomita T. Scalp Arteriovenous Malformation (Cirsoïd Aneurysm) in Adolescence: Report of 2 Cases and Review of the Literature. *World Neurosurg*. 2018;116:e1042-6. doi: 10.1016/j.wneu.2018.05.161.
 18. Khodadad G. Arteriovenous malformations of the scalp. *Ann Surg*. 1973;177:79-85.
 19. Kumar R, Sharma G, Sharma BS. Management of scalp arteriovenous malformation case series and review of literature. *British Journal of Neurosurgery*, June 2012;26:371-7. doi: 10.3109/02688697.2012.654838
 20. Matsushige T, Kiya K, Satoh H, Mizoue T, Kagawa K, Araki H, *et al.* Arteriovenous Malformation of the Scalp: Case Report and Review of the Literature. *Surg Neurol* 2004;62:253-9. doi:10.1016/j.surneu.2003.09.033
 21. Godwin O, Ayotunde O, Millicent O, Yvonne O: Extracranial Arteriovenous Malformation of The Scalp: Value of Computed Tomographic Angiography. *The Internet Journal of Radiology* 2006;5:1.
 22. Rane SY, Lamba S, Gohil AJ, Gupta AK. Compendium of scalp arteriovenous malformation (AVM) cases—a retrospective study and review. *European Journal of Plastic Surgery* 2017;41:223-8.
 23. Hage ZA, Few JW, Surdell DL, Adel JG. Modern endovascular and aesthetic surgery techniques to treat arteriovenous malformations of the scalp: Case illustration. *Surg Neurol* 2008;70:198-203.
 24. Barnwell SL, Halbach VV, Dowd CF, Higashida RT, Hieshima GB. Endovascular treatment of scalp arteriovenous fistulas associated with a large varix. *Radiology* 1989;173:533-9.
 25. Nishijima I, Ikemura R, Gushiken M, Miyagi K, Iha K. Nonsurgical treatment of scalp arteriovenous malformation using a combination of ultrasound-guided thrombin injection and transarterial coil embolization. *Journal of vascular surgery* 2012;833-6.
 26. Dmytriw AA, terBruggen KG, Krings T, Agid R. Endovascular treatment of head and neck arteriovenous malformations, *Neuroradiology*: 2014;56:227-36.
 27. Wilkinson HA. Recurrence of vascular malformation of the scalp 18 years following excision. Case report. *J Neurosurg* 1971;34:435-7.
 28. Souder DE, Bercaw BL: Arteriovenous fistula secondary to hair transplantation. *N Engl J Med* 1970;283:473-4.
 29. Barros d'Sa, AA, Heard, CE. Arteriovenous fistula after hair transplantation. *BMJ* 1978;1:340-1. doi:10.1136/bmj.1.6109.340.
 30. Lanzieri CF, Sacher M, Som PM, Haimov M: Arteriovenous fistula after hair transplantation. *AJNR* 1985;6:111-2.
 31. Liounakos JI, Urakov T, Snelling B, Peterson EC. Scalp Arteriovenous Fistula following Hair Transplantation: A Case Report and Review of the Literature. *Clin Med Rev Case Rep* 2018;5:200. doi.org/10.23937/2378-3656/1410200.
 32. Gupta AK, Purkayastha S, Bodhey NK, Kapilamoorthy TR, Krishnamoorthy T, Kesavadas C, *et al.* Endovascular treatment of scalp cirsoïd aneurysm. *Neurology India* 2008;56:167-72.
 33. Gangadharaswamy SB, Nagaraj NM, Pai BS. Surgical management of scalp arteriovenous malformations using a novel surgical technique—Case series. *International Journal of Surgery Case Reports* 2017;37:250-3. doi.org/10.1016/j.ijscr.2017.06.057.
 34. Gupta R, Agrawal A. Arteriovenous malformation of external ear and temporal region: A case report. *Int J Res Med Sci*. 2015;3:3427-9. <http://dx.doi.org/10.18203/2320-6012.ijrms20151205>.
 35. Tual-Chalot S, Oh SP, Arthur HM. Mouse models of hereditary hemorrhagic telangiectasia: recent advances and future challenges. *Front Genet*. 2015;6:25.
 36. Albuquerque Sousa LH, Maranha Gatto LA, Junior ZD, Koppe GL. Scalp Cirsoïd Aneurysm: An Updated Systematic Literature Review And An Illustrative Case Report. *World Neurosurg* 2018;119:416-27. Available from: <https://doi.org/10.1016/j.wneu.2018.08.098>. [Last accessed on 2018 Nov 05].
 37. Karsy M, Raheja A, Guan J, Osborn AG, Couldwell WT. Scalp Arteriovenous Malformation with Concomitant, Flow-Dependent Malformation and Aneurysm. *World Neurosurgery*, 2016;90:708.e5–708.e9. doi:10.1016/j.wneu.2016.03.047.
 38. Hasturk AE, Erten F, Ayata T. Giant arteriovenous malformation of the scalp. *Asian Journal of Neurosurgery* 2012;7:1:39-41. DOI: 10.4103/1793-5482.95698.
 39. Worm PV, Ruschel LG, Roxo MR, Camelo R. *Rev Assoc Med Bras*. 2016;62:828-30. doi: 10.1590/1806-9282.62.09.828.
 40. Mohamed WNZW, Abdullah NNL, Muda AS. Scalp arteriovenous malformation: a case report. *Malays J Med Sci* 2008;15:3:55-7.
 41. Gupta P, Gupta N, Chaudhary J, Mishra HK, Verma AP. Cirsoïd aneurysm of the scalp. *International Medical Journal*. 2016;3:729-31.
 42. Pukar MM, Patel IS, Mewada SG. Cirsoïd aneurysm of scalp occipital region- A case report. *Int J Res Health Sci [Internet]* 2014;2:698-702.
 43. Gupta AK, Iyengar SN, Sharma A. Scalp arteriovenous malformation: A case report with review. *Romanian Neurosurgery* 2018;32:151-5. DOI: 10.2478/romneu-2018-0018.
 44. Visser A, FitzJohn T, Tan ST. Surgical management of arteriovenous malformation. *Journal of Plastic, Reconstructive & Aesthetic Surgery* 2011;64;3:283-91. doi.org/10.1016/j.bjps.2010.05.033
 45. Jung SH, Yim MB, Lee CY, Song DW, Kim IM, Son EI. Treatment of Scalp Arteriovenous Malformation. *J Korean Neurosurg Soc* 2005;38:269-72.
 46. Corr PD. Cirsoïd aneurysm of the scalp. *Singapore Med J* 2007;48:e268-9.
 47. Ki HJ, Lee HK, Hur JW, Lee JW. Post-Traumatic Arteriovenous Fistula of the Scalp. *J Korean Neurosurg Soc* 2015;58:298-300. DOI: <https://doi.org/10.3340/jkns.2015.58.3.298>.
 48. Amin O, Molina AR, Constantinides J, Greig AV. Excision of a scalp arteriovenous malformation using Thunderbeat™: The safe way forward. *J Plastic, Reconstr Aesthet Surg*. 2016;69:1572-1574. Available from: <https://doi.org/10.1016/j.bjps.2016.06.014>. [Last accessed on 2018 Nov 05].
 49. Barhate MV, Vhora SS, Pandey RK. Cirsoïd Aneurysm of the Scalp. *Indian J Neurosurg* 2016;5:129-32. DOI:<http://dx.doi.org/10.1055/s-0036-1581974>.
 50. Global status report on road safety 2015. p. 2-5.