

Isolated Open Total Talar Dislocation: A Case Report and Literature Review

Sylvain Steinmetz, Niccolo Rotigliano, Philippe Zermatten

Department of Surgery, Division of Orthopaedic Surgery and Traumatology, Centre Hospitalier du Valais Romand, Sion, Switzerland

Abstract

Open total talar dislocation without associated fractures is an extremely rare injury. There are scant reports in the literature. Accordingly, there is no consensus about the appropriate treatment of the extruded talus. We present the case of a 33-year-old man who sustained an isolated open total talar dislocation focusing on its management and outcome and review the literature. Open total talar dislocation is a terrible injury and its treatment is demanding. Early reimplantation of the talus appears to be a relatively risk-free and feasible procedure. Talcotomy should be considered as a salvage procedure.

Keywords: Avascular necrosis, care management, dislocation, talus

INTRODUCTION

Open total talar dislocation is a rare injury and is frequently associated with critical soft-tissue injury, wound contamination, and malleolar, talar body, or neck fractures.^[1] Total dislocation of the talus without associated fractures is even rarer.^[2,3] The talus is free of insertions and origins of muscles and is covered over 60% by cartilage. These anatomical characteristics make the talus vulnerable to dislocation. A high-energy trauma is responsible in the majority of cases. The mechanism of the trauma is usually a combined movement of extreme subtalar supination and tibiotalar plantar flexion that moves the talus out of the ankle mortise. In case of extrusion, the talus can rest attached to the body by soft-tissue attachments or thrown out the skin and lacking at the time of early presentation.^[4,5] Most reports in the literature describe an anterior lateral ankle wound with the talus extruded laterally.^[1,5-7]

We present a case of an isolated open total talar dislocation and discuss its surgical management, potential complications, and functional outcome.

CASE REPORT

A 33-year-old man injured his right and left ankles in a workplace accident. He was occupied to remove a heavy (about 300 pounds) steel security door which fell on him. He will retain

it, but he did not succeed in doing that. In the heat of the moment, he sustained in all probability a movement of extreme supination and plantar flexion of his right ankle. He received the door on the right side of his ribcage and remained trapped. His colleagues immediately assisted him removing the door. When the first-aid workers arrived, the patient was conscious and hemodynamically stable. They provided him with medical care and brought him to the emergency department of our hospital. At admission (90 min after the accident), he was in moderate distress due to pain and well oriented. Vital signs were constant. To facilitate the initial management, he was intubated. Examination of the right foot revealed a rather clean wound on the anterolateral side of the ankle through which the talar body was thrown out [Figure 1]. Further, there was clearly a fracture dislocation of the left ankle which was immediately reduced and immobilized. Neither vascular impairment nor sensory loss was evident. The patient was administered 1.5 g of cefuroxim (Zinacef®) intravenously and a tetanus toxoid booster. The talus was wrapped in antiseptic standard solution-soaked gauze. Preoperative computed tomography (CT) scan displayed a total dislocation

Address for correspondence: Dr. Philippe Zermatten, Department of Surgery, Division of Orthopaedic Surgery and Traumatology, Centre Hospitalier du Valais Romand, Sion, Switzerland. E-mail: philippe.zermatten@hopitalvs.ch

Access this article online

Quick Response Code:



Website:
www.archtrauma.com

DOI:
10.4103/atr.atr_18_17

This is an open access article distributed under the terms of the Creative Commons Attribution-NonCommercial-ShareAlike 3.0 License, which allows others to remix, tweak, and build upon the work non-commercially, as long as the author is credited and the new creations are licensed under the identical terms.

For reprints contact: reprints@medknow.com

How to cite this article: Steinmetz S, Rotigliano N, Zermatten P. Isolated open total talar dislocation: A case report and literature review. Arch Trauma Res 2017;6:49-52.

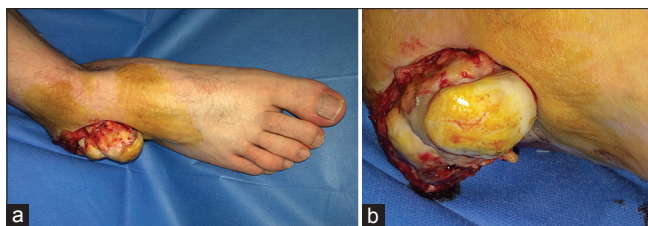


Figure 1: Clinical photographs of the right ankle showing open extrusion of the talus on the anterolateral side (a) overall picture (b) close-up picture

of the talus with a small inferolateral osteochondral fragment, a reduced “equivalent trimalleolar” fracture of the left ankle and fractures of the anterior arch of the 5th, 6th, and 7th ribs. The patient was then brought to the operating room. The wound was copiously irrigated with pulsed lavage using 9 L of sterile normal saline followed by 10% povidone-iodine. The single strand of soft tissue attached to the talar neck was preserved and the talus was reduced anatomically with the help of a threaded Steinmann pin previously inserted into the posterior calcaneal tuberosity. The anterolateral capsular ligamentar apparatus was repaired as a possible attempt and the wound was closed by primary intention. The ankle was then stabilized by means of an external fixator placed in a delta configuration. The left lateral malleolus was as well open reduced and fixed by a plate and the ankle was placed in a walker boot (VACoped®). Intravenous antibiotics (amoxicillin-acid clavulanic 2.2 g every 6 h) were continued for a total of 5 days. The external fixator was maintained for 8 weeks. Weightbearing was forbidden for 2 months. At 8 weeks, postoperative radiographs showed the absence of the Hawkins’ sign conveying a high risk of avascular necrosis (AVN) of the talus. The external fixator was removed at 8 weeks postoperatively. Partial weightbearing was then allowed under protection of an ankle brace for further 4 weeks on the right limb and total weightbearing was allowed on the left limb together with a range of motion exercises of both the ankles and muscular reinforcement of the legs. At the 6-month follow-up, an arthro-magnetic resonance (MR) imaging showed posttraumatic sequelae of the right ankle, especially on the lateral part of the talus (AVN) with signs of revascularization [Figure 2]. One year postoperatively, the patient was evaluated both radiographically and functionally. He reported moderate daily pain with weightbearing but painless motion of his right ankle. Physical examination showed a mild restriction of the sagittal motion of the right ankle compared with the left ankle. The patient also displayed a moderate restriction of subtalar joint motion. A Single Photon Emission Computed Tomography (SPECT) scan confirmed a delimited zone of AVN of the talus on its superolateral part [Figure 3]. The American Orthopaedic Foot and Ankle Society (AOFAS) Ankle-Hindfoot Scale (AHS) score and the Manchester-Oxford Foot Questionnaire-Index (MOXFQ-Index) score were, respectively, 77/100 and 40/0. At the last follow-up (18 months postoperatively), radiographs demonstrated a mild narrowing of the tibiotalar joint space [Figure 4]. The AOFAS AHS score and the MOXFQ-Index score were then, respectively, 74/100 and 45/0.

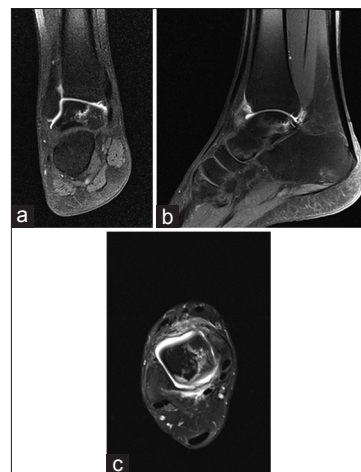


Figure 2: Arthro-magnetic resonance images at follow-up (at 6 months postoperatively) showing signs of avascular necrosis of the lateral part of the talus with signs of revascularization (a) coronal view (b) sagittal view (c) axial view

DISCUSSION

Talar dislocation is open and anterolateral in more than 50% of cases.^[1,5-7] No specific mechanism of trauma leads distinctly to ankle, subtalar, or total talus dislocation. Leitner^[2] defined a 3-stage mechanism of dislocation: talar extrusion can be regarded as the end point of a combined movement of extreme subtalar supination and tibiotalar plantar flexion. A high-energy trauma is mostly responsible. In our case, the mechanism was in all probability a movement of extreme supination and plantar flexion on the right ankle when the patient was trying to hold a heavy steel security door which was falling on him.

This rare injury is reputed to be one of the most disabling and potentially catastrophic injuries to the ankle.^[8] It is often associated with massive wound contamination, severe soft-tissue impairment, and disruption of the blood supply to the talus. Infection and AVN are hence the most early complications.^[1,9-11] Late complications could be seen approximately about 1 year after trauma and principally include bone collapse, stiffness, arthritis, and bone necrosis.^[12] The latter is the most feared complication. Most authors put forward that early reduction and salvage of the extruded talus is a relatively risk-free and feasible procedure.^[1,13,14]

Open talar dislocations are frequently complicated by soft-tissue infection. The infection rate ranges from 11.5% to 38% of cases^[9,15] compared with 88.9% initially reported by Detenbeck and Kelly.^[8] Over the years, infection risk has been diminished through improvement of staged procedures for wound care and soft-tissue management and adapted antibiotherapy.

AVN of the talus is a feared complication. The blood supply to the talus includes the artery of the tarsal canal, branch of the posterior tibial artery, the deltoid branches of the posterior tibial artery, and the sinus tarsi artery formed by the anterior tibial artery and perforating peroneal artery.^[16] There is also

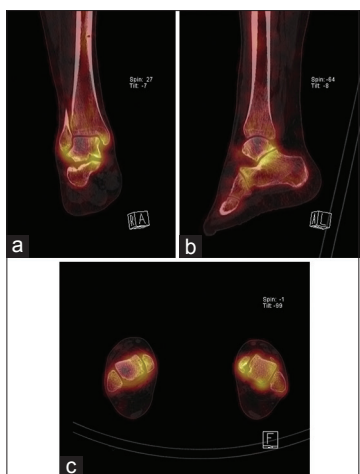

Figure 3: Single photon emission scan/computed tomography images at follow-up (12 months postoperatively) showing signs of avascular necrosis of the superolateral part of the talus and mild anteromedial tibiotalar and posterior subtalar degenerative changes (a) coronal view (b) sagittal view (c) axial view

a system of interosseous anastomoses which are complete in approximately 60% of cases.^[17] The incidence of AVN is due to the vulnerable nature of this blood supply^[11] and depends on the loss of soft-tissue attachments.^[5,18] In the early postoperative period, the development of AVN is not easy to predict. MR imaging remains the most specific and sensitive examination to recognize early development of AVN; it can be seen from 6 months to 2 years postinjury albeit posttraumatic arthritis may develop after more than 10 years.^[19] The Hawkins' sign is the only early predictive marker of revascularization that can be seen on standard radiography. It is defined as subchondral radiolucency in the talar dome, which is visible 6–8 weeks postinjury. If a full or partial positive Hawkins' sign is observed, it is improbable that AVN will develop subsequently.^[20] In our case, we cannot observe this sign on standard radiography. The arthro-MR of the right ankle showed a delimited zone of talar AVN 6 months postoperatively with signs of revascularization. At 1 year after the operation, a SPECT/scan confirmed the presence of an AVN of the talar dome on its superolateral part. Hiraizumi *et al.*^[5] showed that the risk of AVN was highest in cases in which no soft tissues remained attached to the talus.

Posttraumatic osteoarthritis is not a rare complication of these injuries.^[5,14,21,22] It is reasonable to expect at least some degree of subtalar or tibiotalar arthritis. Clinically significant osteoarthritis in patients with isolated talar dislocation is lower (10%) than the incidence in the overall talar dislocation (16%).^[23] The possible reason of predisposing to this complication is the forces applied during the injury to talus cartilage. In our case, the radiographs at the last follow-up (18 months postoperatively) showed mild tibiotalar arthritis.

Historically, total talar dislocation has been treated by primary talectomy and tibio-calcaneal arthrodesis with the

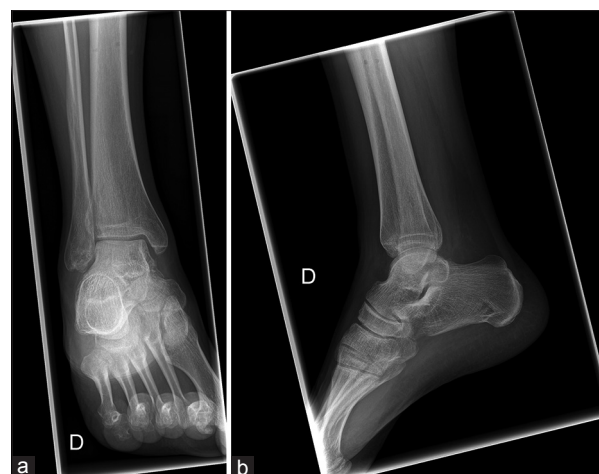


Figure 4: Eighteen months' postoperative radiographs (at the last follow-up) showing a mild superolateral narrowing of the tibiotalar joint space (a) anteroposterior view (b) sagittal view

aim of diminishing the risk of the complications. Weston *et al.*^[23] have recently suggested that talectomy does not reduce the rate of complications even in cases of total extrusion with massive contamination. Many authors put forward that, in spite of the risk of infection or post-AVN talar collapse, talar reimplantation allows to retain height and bone stock.^[8,24-26] Good short- and long-term clinical outcomes have been reported after preservation and reduction of the talus regardless to his contamination and soft-tissue connection.^[9,11,24-28] If there is tendency to redislocation, K-wire transfixation may be used.^[1] An additional immobilization for 6–8 weeks with an external fixator is hardly recommended.^[1,29,30]

In conclusion, open total talar dislocation is a terrible injury and its treatment is demanding. Early reimplantation of the talus appears to be a worthwhile procedure to avoid talectomy and tibio-calcaneal arthrodesis initially. The latter gives rise to severe functional loss and should be regarded as a secondary choice in case of talar salvage failure. All patients should be enlightened of the unpredictable long-term prognosis and the feasibility of further reconstructive procedures.

Declaration of patient consent

The authors certify that they have obtained all appropriate patient consent forms. In the form the patient(s) has/have given his/her/their consent for his/her/their images and other clinical information to be reported in the journal. The patients understand that their names and initials will not be published and due efforts will be made to conceal their identity, but anonymity cannot be guaranteed.

Financial support and sponsorship

Nil.

Conflicts of interest

There are no conflicts of interest.

REFERENCES

1. Van Opstal N, Vandeputte G. Traumatic talus extrusion: Case reports and literature review. *Acta Orthop Belg* 2009;75:699-704.
2. Leitner B. The mechanism of total dislocation of the talus. *J Bone Joint Surg Am* 1955;37-A:89-95.
3. Schuind F, Andrienne Y, Burny F, Donkerwolcke M, Saric O, Body J, *et al.* Fractures and dislocations of the astragalus. Review of 359 cases. *Acta Orthop Belg* 1983;49:652-89.
4. Montoli C, De Pietri M, Barbieri S, D'Angelo F. Total extrusion of the talus: A case report. *J Foot Ankle Surg* 2004;43:321-6.
5. Hiraizumi Y, Hara T, Takahashi M, Mayehiyo S. Open total dislocation of the talus with extrusion (missing talus): Report of two cases. *Foot Ankle* 1992;13:473-7.
6. Lee HS, Chung HW, Suh JS. Total talar extrusion without soft tissue attachments. *Clin Orthop Surg* 2014;6:236-41.
7. Hidalgo Ovejero AM, Garcia Mata S, Heras Izaguirre J, Martinez Grande M. Posteromedial dislocation of the talus. A case report and review of the literature. *Acta Orthop Belg* 1991;57:63-7.
8. Detenbeck LC, Kelly PJ. Total dislocation of the talus. *J Bone Joint Surg Am* 1969;51:283-8.
9. Palomo-Traver JM, Cruz-Renovell E, Granell-Beltran V, Monzonis-Garcia J. Open total talus dislocation: Case report and review of the literature. *J Orthop Trauma* 1997;11:45-9.
10. Ramesh P, Avadhani A, Dheenadhayalan J, Rajasekaran S. Reimplantation of total talar extrusions. *Injury Extra* 2010;41:53-7.
11. Karampinas PK, Kavroudakis E, Polyzois V, Vlamis J, Pneumaticos S. Open talar dislocations without associated fractures. *Foot Ankle Surg* 2014;20:100-4.
12. Lesić AR, Zagorac SG, Bumbasirević MZ. Talar injuries – The orthopaedic challenge. *Acta Chir Iugosl* 2012;59:25-30.
13. Gerken N, Yalamanchili R, Yalamanchili S, Penagaluru P, Md EM, Cox G, *et al.* Talar revascularization after a complete talar extrusion. *J Orthop Trauma* 2011;25:e107-10.
14. Memisoglu K, Hürmeydan A. Total extrusion of the talus in an adolescent: A case report. *J Am Podiatr Med Assoc* 2009;99:431-4.
15. Marsh JL, Saltzman CL, Iverson M, Shapiro DS. Major open injuries of the talus. *J Orthop Trauma* 1995;9:371-6.
16. Gelberman RH, Mortensen WW. The arterial anatomy of the talus. *Foot Ankle* 1983;4:64-72.
17. Mulfinger GL, Trueta J. The blood supply of the talus. *J Bone Joint Surg Br* 1970;52:160-7.
18. Huang PJ, Fu YC, Tien YC, Lin GT, Lin SY, Cheng YM, *et al.* Open total talar dislocation – Report of two cases. *Kaohsiung J Med Sci* 2000;16:214-8.
19. Breccia M, Peruzzi M, Cerbarano L, Galli M. Treatment and outcome of open dislocation of the ankle with complete talar extrusion: A case report. *Foot (Edinb)* 2014;24:89-93.
20. Tezval M, Dumont C, Stürmer KM. Prognostic reliability of the Hawkins sign in fractures of the talus. *J Orthop Trauma* 2007;21:538-43.
21. Brewster NT, Maffulli N. Reimplantation of the totally extruded talus. *J Orthop Trauma* 1997;11:42-5.
22. Gulan G, Sestan B, Jotanović Z, Madarević T, Mikacević M, Ravlić-Gulan J, *et al.* Open total talar dislocation with extrusion (missing talus). *Coll Antropol* 2009;33:669-72.
23. Weston JT, Liu X, Wandtke ME, Liu J, Ebraheim NE. A systematic review of total dislocation of the talus. *Orthop Surg* 2015;7:97-101.
24. Fleming J, Hurley KK. Total talar extrusion: A case report. *J Foot Ankle Surg* 2009;48:690.e19-23.
25. Smith CS, Nork SE, Sangeorzan BJ. The extruded talus: Results of reimplantation. *J Bone Joint Surg Am* 2006;88:2418-24.
26. Mohindra M, Gogna P, Thora A, Tiwari A, Singla R, Mahindra P, *et al.* Early reimplantation for open total talar extrusion. *J Orthop Surg (Hong Kong)* 2014;22:304-8.
27. Schiffer G, Jubel A, Elsner A, Andermahr J. Complete talar dislocation without late osteonecrosis: Clinical case and anatomic study. *J Foot Ankle Surg* 2007;46:120-3.
28. Assal M, Stern R. Total extrusion of the talus. A case report. *J Bone Joint Surg Am* 2004;86-A:2726-31.
29. Wagner R, Blattert TR, Weckbach A. Talar dislocations. *Injury* 2004;35 Suppl 2:SB36-45.
30. Taymaz A, Gunal I. Complete dislocation of the talus unaccompanied by fracture. *J Foot Ankle Surg* 2005;44:156-8.