

# Avulsion Fractures at the Base of the 2<sup>nd</sup> Metacarpal Due to the Extensor Carpi Radialis Longus Tendon: A Case Report and Review of the Literature

Ali Najefi,<sup>1\*</sup> Lucksmanna Jeyaseelan,<sup>1</sup> Anand Patel,<sup>1</sup> Akhil Kapoor,<sup>1</sup> and Sunil Auplish<sup>1</sup>

<sup>1</sup>Trauma and Orthopaedic Department, Queen's Hospital, Romford, United Kingdom

\*Corresponding author: Ali Najefi, Trauma and Orthopaedic Department, Queen's Hospital, Romford, United Kingdom. Tel: +44-1708435000, Fax: +44-7956071227, E-mail: anajefi@doctors.org.uk

Received 2015 September 1; Accepted 2015 September 30.

## Abstract

**Introduction:** Simultaneous contraction of the extensor carpi radialis longus (ECRL) with forced hyperflexion of the wrist can result in avulsion of the tendon and its bony attachment at its insertion at the dorsum of the base of the second metacarpal. This is a rare and often unreported fracture pattern.

**Case Presentation:** We present a 31-year-old male who sustained a hyperflexion injury. He was managed surgically and had good post-operative outcomes. A literature search revealed 16 papers covering 18 cases of similar injuries. 12 were initially managed surgically and 6 were managed conservatively.

**Conclusions:** Of the open reductions and internal fixations, 11 (92%) were successful and patients made a full recovery. Conservative management was unsuccessful in 4 cases; one patient required surgery for metacarpal boss, one patient had retraction of the tendon at one week follow up and another had weak flexion of the wrist. We recommend open reduction and internal fixation for these injuries. It may allow a faster recovery and therefore allow an earlier return to work and activity.

**Keywords:** EcrL, Extensor Carpi Radialis Longus, Avulsion, Metacarpal, Tendon

## 1. Introduction

Avulsion fractures involving the radial wrist extensors are rare. The tendon of extensor carpi radialis longus (ECRL) is inserted at the dorsum of the base of the second metacarpal forming a "hood-like" structure over the carpometacarpal (CMC) articulation. The dorsal and volar capsulo-ligamentous complex as well as the bony architecture allows little motion at the index finger and middle finger CMC articulations, preventing dorsal dislocation of the second CMC joint during a forced hyperflexion injury at the wrist. Simultaneous contraction of the ECRL tendon results in avulsion at its insertion, usually with its bony attachment. We present a case describing this type of injury and provide a review of the literature.

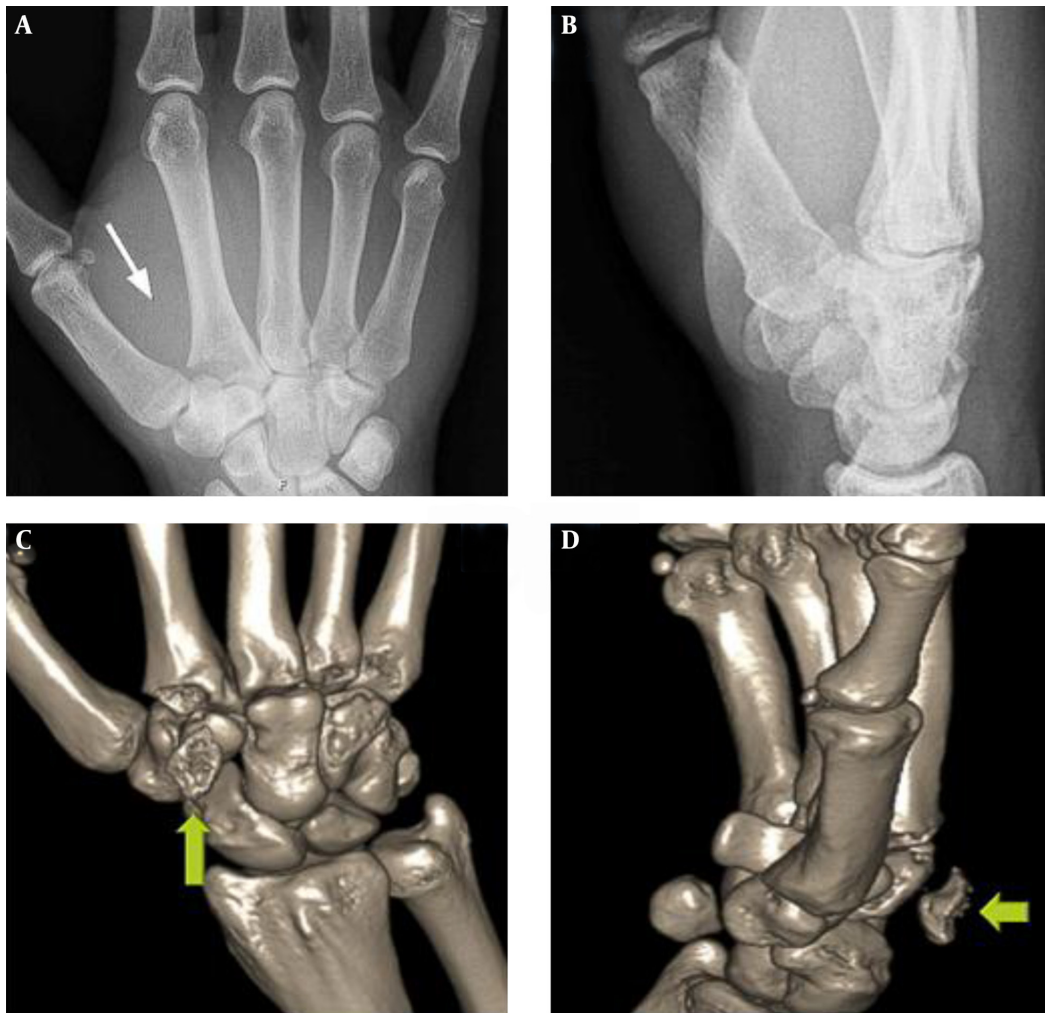## 2. Case Presentation

A thirty-one year old right hand dominant male presented after sustaining a hyperflexion injury to his right hand in a kickboxing fight. There was no evidence of any rotational deformity on examination. Radiographs and Computed Tomography (CT) scans showed an intra-articular avulsion fracture of the base of the 2<sup>nd</sup> metacarpal, with a radial sided articular fragment of approximately 50% of the joint surface (Figure 1).

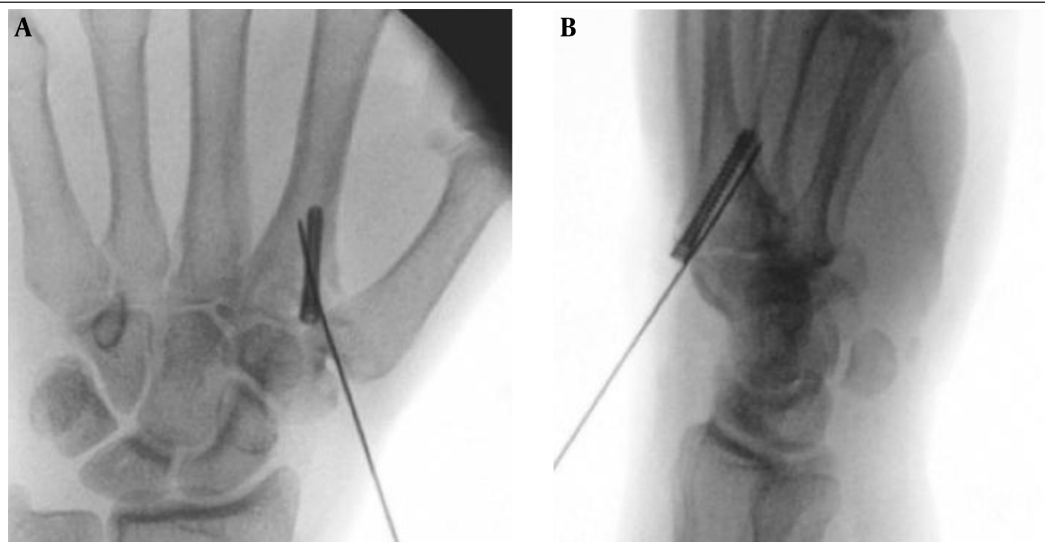
Operative intervention was undertaken to restore the congruity of the articular surface. A dorsal longitu-

dinal skin incision was made over the base of second metacarpal. The fragment of bone attached to the ECRL tendon had displaced proximally and rotated. The fracture was reduced anatomically and provisionally stabilized with a 1.1 mm Kirschner wire (K-wire). A second K-wire was placed to provide rotational stability. A 26 mm Mini-Acutrak (Acumed) headless screw was placed over the second K-wire, which held the bony fragment and attached tendon (see Figure 2). Both K-wires were subsequently removed. The method was well tolerated and there were no adverse outcomes. He began hand therapy at 4 weeks. At 18 months follow up, he had fully restored grip strength and wrist extension, and had normal DASH scores.

A literature search was performed using Pubmed, Cochrane and Medline databases. All ECRL ruptures were included, even if they were found together with another tendon rupture. The keywords "ECRL," "extensor carpi radialis longus," "tendon," "metacarpal," and "avulsion" were used. There were sixteen published case reports which included eighteen reported cases. Sixteen cases were from avulsion fractures to the base of the second metacarpal, whereas the remaining two were purely tendinous avulsions. Twelve cases were initially managed surgically and six were managed conservatively.



**Figure 1.** A and B, AP and lateral radiographs; C and D, and AP and lateral 3D reconstruction CT images; taken at the time of the injury, the arrows demonstrate the fragment that attaches to the ecll tendon.



**Figure 2.** A, Intra-operative AP; B, lateral radiographs showing the reduction of the fracture with a K-wire and fixation using a headless 26 mm Mini Acutrak (Acumed) Screw.

### 3. Discussion

#### 3.1. Surgical Management Outcomes

Open reduction and internal fixation (ORIF) has been advocated by most authors. Six cases reported normal hand function and wrist extensor power after K-wire fixation (1-6). Ishida et al. and Vandeputte and De Smet reported successful surgical repair of ipsilateral avulsions of both ECRL and extensor carpi radialis brevis (ECRB) with K-wires and suture anchors (7, 8). One case report described the repair of the ECRL tendon with the aid of suture anchors within 24 hours of the injury (9). At follow up, the patient regained full function but had some mild loss of grip and wrist extension strength. Clark et al. used two screws to fix the avulsed fragment and had a successful outcome (10). Sadr and Lalehzarian reported residual weakness in hand grip and wrist extension after inability to reattach the ECRL at its insertion site 12 days post injury (11). They advocated earlier intervention with open reduction and internal fixation with anatomic repair of the detached tendon. They successfully performed an ECRL to ECRB tenodesis at 12 days.

Jena et al. initially attempted to pursue non-surgical treatment with plaster immobilization, but retraction of the extensor carpi radialis longus caused displacement of the fracture fragment after 1 week, with the patient complaining of pain and swelling (12). ORIF with K-wires led to satisfactory results.

One case reported a missed diagnosis with persistent dorsal wrist pain and limited wrist extension at 2 weeks (13). An MRI revealed a retracted ECRL tendon, which was successfully repaired with a tenodesis to ECRB at 5 weeks.

#### 3.2. Conservative Management Outcomes

The 6 cases managed conservatively came from 3 reports. They were all bony fragment avulsions. Crichlow and Hoskinson reported three cases of ECRL avulsions managed non-operatively (14). However, one patient had prominent metacarpal boss which later needed surgical removal whilst one patient had weak dorsiflexion. There are two case reports that have successfully conservatively managed an avulsion fracture of index base metacarpal with ECRL injury (15, 16).

This is a rare and often unrecognised fracture pattern, and early recognition is key to its management. Due to its rarity, there is a paucity of high level evidence regarding the optimal treatment option. Based on the current available literature, we have found that open reduction and internal fixation for these injuries leads to positive outcomes by restoring joint surface integrity and grip stability. It prevents complications such as rupture of extensor pollicis longus, metacarpal boss and reduced wrist power and movement (4, 10). There are 4 unsuccessful cases of conservative management in the literature, all of which required surgical fixation or correction (3, 7-9). There has been no dif-

ference in outcome demonstrated between non-fragment and fragment avulsions.

There is no direct comparison of surgical techniques and subsequent outcomes, but several differing methods of ORIF have been successful. Our own method of internal fixation was well tolerated and may provide a more stable fixation than K-wires alone. A self-tapping headless screw provides excellent compression at the fracture site and may cause less soft tissue irritation. Early ORIF allows for early mobilisation, which allows patients to return to work and activity much faster; thus having socio-economic benefits.

### References

1. DeLee JC. Avulsion fracture of the base of the second metacarpal by the extensor carpi radialis longus. A case report. *J Bone Jt Surg Am.* 1979;**61**(3):445-6.
2. Takami H, Takahashi S, Ando M. Avulsion fracture of the second metacarpal base by the extensor carpi radialis longus. *Arch Orthop Trauma Surg.* 1998;**118**(1-2):109-10. [PubMed: 9833121]
3. Kuschner SH, Shepard L, Stephens S, Gellman H. Fracture of the index metacarpal base with subluxation of the trapeziometacarpal joint. A case report. *Clin Orthop Relat Res.* 1991;(264):197-9. [PubMed: 1997236]
4. Cassell OC, Vidal P. An unreported cause of rupture of the extensor pollicis longus tendon. *J Hand Surg Br.* 1996;**21**(5):640-1. [PubMed: 9230951]
5. Thomas WO, Al M, Gottliebson WM, D'Amore TF, Harris CN, Parry SW. Isolated palmar displaced fracture of the base of the index metacarpal: A case report. *J Hand Surg Br.* 1994;**19**(3):455-6. doi: 10.1016/0363-5023(94)90061-2.
6. Treble N, Arif S. Avulsion fracture of the index metacarpal. *J Hand Surg Br.* 1987;**12**(1):38-9. [PubMed: 3572176]
7. Ishida K, Fujioka H, Doi R. Acute rupture of extensor pollicis longus tendon due to avulsed fracture of the second metacarpal base: a case report. *Hand Surg.* 2006;**11**(1-2):43-5. doi: 10.1142/S0218810406003097. [PubMed: 17080527]
8. Vandeputte G, De Smet L. Avulsion of both extensor carpi radialis tendons: a case report. *J Hand Surg Am.* 1999;**24**(6):1286-8. doi: 10.1053/jhsu.1999.1286. [PubMed: 10584955]
9. Boles SD, Durbin RA. Simultaneous ipsilateral avulsion of the extensor carpi radialis longus and brevis tendon insertions: Case report and review of the literature. *J Hand Surg Am.* 1999;**24**(4):845-9. doi: 10.1053/jhsu.1999.0845. [PubMed: 10447178]
10. Clark D, Amirfeyz R, McCann P, Bhatia R. Extensor carpi radialis longus avulsion: a literature review and case report. *Hand Surg.* 2008;**13**(3):187-92. doi: 10.1142/S0218810408004067. [PubMed: 19378365]
11. Sadr B, Lalehzarian M. Traumatic avulsion of the tendon of extensor carpi radialis longus. *J Hand Surg Am.* 1987;**12**(6):1035-7. [PubMed: 3693831]
12. Jena D, Giannikas KA, Din R. Avulsion fracture of the extensor carpi radialis longus in a rugby player: a case report. *Br J Sports Med.* 2001;**35**(2):133-5. [PubMed: 11273978]
13. Gurich RW, Tanksley JA, Pappas ND. Late repair of combined extensor carpi radialis longus and brevis avulsion fractures. *Orthopedics.* 2013;**36**(10):766-9. doi: 10.3928/01477447-20130920-03. [PubMed: 24093687]
14. Crichlow TP, Hoskinson J. Avulsion fracture of the index metacarpal base: three case reports. *J Hand Surg Br.* 1988;**13**(2):212-4. [PubMed: 3385304]
15. Shyamsundar S. Avulsion fracture of the extensor carpi radialis longus tendon: case report and literature review. *Hand Surg.* 2012;**17**(2):247-9. doi: 10.1142/S0218810412720264. [PubMed: 22745093]
16. Jessa KK, Hodge JC. Avulsion fracture of tendon of extensor carpi radialis longus: unknown mechanism. *J Emerg Med.* 1997;**15**(2):201-7. [PubMed: 9144063]