

# Forearm Longitudinal Discrepancy after Forearm Fractures' Fixation in Pediatric: A Case Series Study

Ali Tabrizi, Ahmadreza Afshar, Meisam Haghmoradi

Department of Orthopedics, Imam Khomeini Hospital, Urmia University of Medical Sciences, Urmia, Iran

ORCID:

Ali Tabrizi: <https://orcid.org/0000-0002-4385-6445>

Ahmadreza Afshar: <https://orcid.org/0000-0002-3676-5932>

Meisam Haghmoradi: <https://orcid.org/0009-0004-0403-1418>

## Abstract

**Background and Objectives:** Forearm fractures in childhood are one of the most common traumatic injuries to the upper extremities. The aim of this study was to investigate the development of growth disturbance after surgical treatment of pediatric forearm fractures and the related factors. **Methods:** This retrospective descriptive study was conducted on 38 children with unstable forearm fractures undergoing surgical treatment. Growth disorder, either overgrowth or undergrowth, was investigated using imaging findings. Functional dysfunction, loss of motion, and pain severity were also evaluated in children with developmental disorders. **Results:** In 13 children (34.2%), forearm longitudinal growth disorder had occurred as overgrowth and no undergrowth was observed in any of the pediatric follow-up periods. The minimum increase in longitudinal growth was 4 mm and the maximum was 10 mm. The mean longitudinal growth was  $5.8 \pm 1.6$  mm. All cases of increased longitudinal overgrowth occurred in the radius. In one case, the longitudinal overgrowth was followed by fixation with Titanium Elastic Nail, and in 12 cases, it was followed by plate fixation. In cases with the increase in longitudinal growth, 12 cases (92.4%) of fractures were in the distal third and 1 case (7.6%) was in the midshaft third. Based on age, there was a significant negative correlation between longitudinal growth and age, so that with decreasing the age of children, the amount of forearm growth increases ( $P = 0.002$ ,  $R = -0.8$ ). **Conclusions:** The most common finding of surgical treatment of pediatric forearm fractures is longitudinal overgrowth. Young age, fractures in the distal third, and the use of plate for fixation appear to be associated with forearm longitudinal overgrowth.

**Keywords:** Forearm, intramedullary nail, overgrowth, pediatric, plate

## INTRODUCTION

Forearm fractures in childhood are one of the most common traumatic injuries to the upper extremities. Most of these fractures are treated with closed reduction and cast immobilization.<sup>[1]</sup> In cases where there is instability or open injury, surgery is often needed to create a proper alignment along the bone. The most common devices to use fixation after open reduction include intramedullary elastic nails (Titanium Elastic Nail [TEN]) and plates. In the distal third fractures, plate fixation is mostly used. Intramedullary nail fixation method is widely used in skeletally immature patients.<sup>[1,2]</sup> Furthermore, open reduction and osteosynthesis with plate and screw fixation are successful treatments in over 90% of pediatrics.<sup>[2]</sup> One of the findings of pediatric fractures in the lower extremity bones is growth disturbance. The longitudinal

growth disturbance is due to the growth plate arrest, which causes shortening or overgrowth with increasing limb length for unknown reasons.<sup>[3]</sup> Overgrowth and angular deformity occur after TENs implantation in pediatric femoral shaft fractures and several studies have been performed in this field.<sup>[4-6]</sup>

One of the findings that can occur in the treatment of intramedullary elastic nails is growth disturbance after fracture

**Address for correspondence:** Dr. Ali Tabrizi,

Department of Orthopedics, Imam Khomeini Hospital, Urmia University of Medical Sciences, Urmia, Iran.  
E-mail: [Ali.tab.ms@gmail.com](mailto:Ali.tab.ms@gmail.com)

This is an open access journal, and articles are distributed under the terms of the Creative Commons Attribution-NonCommercial-ShareAlike 4.0 License, which allows others to remix, tweak, and build upon the work non-commercially, as long as appropriate credit is given and the new creations are licensed under the identical terms.

**For reprints contact:** [WKHLRPMedknow\\_reprints@wolterskluwer.com](mailto:WKHLRPMedknow_reprints@wolterskluwer.com)

**How to cite this article:** Tabrizi A, Afshar A, Haghmoradi M. Forearm longitudinal discrepancy after forearm fractures' fixation in pediatric: A case series study. Arch Trauma Res 2023;12:39-43.

**Received:** 01-10-2022,

**Revised:** 16-03-2023,

**Accepted:** 18-03-2023,

**Published:** 29-04-2023.

### Access this article online

Quick Response Code:



**Website:**  
[www.archtrauma.com](http://www.archtrauma.com)

**DOI:**  
10.4103/atr.atr\_58\_22

fixation. In a study conducted by Dai *et al.* on pediatric femoral shaft fractures fixed with flexible titanium intramedullary nails, limb overgrowth was investigated. Based on the findings of this study, nail–canal diameter and fracture type are important factors causing limb overgrowth.<sup>[4]</sup> Furthermore, the age of patients between 2 and 10 years is another factor that has been mentioned in other studies in this field.<sup>[7]</sup> The exact mechanism of overgrowth is not yet known. However, what is clear is that the power of remodeling angular and rotational deformities is high in children.<sup>[3]</sup> In pediatric forearm fractures, unlike lower limb fractures, few studies have been performed and our knowledge in this field is very limited. In a study conducted by de Pablos *et al.* in 1994 on the pattern of radius growth, pediatric forearm fractures were treated conservatively. Radial overgrowth occurred in 21% of patients and radial shortening occurred in 25%. Factors that increase the vascularity of the growth plate in the femur and tibia as growth promoters should be further investigated in pediatric forearm fractures.<sup>[8]</sup> Longitudinal overgrowth of long bones after the use of intramedullary elastic nails in the lower limb has been proven, but it is rare in the upper limb, and the exact mechanism of occurrence of this phenomenon has not been determined. This study aimed at evaluating the longitudinal growth disturbance and functional outcomes in the forearm of children after surgical interventions.

## METHODS

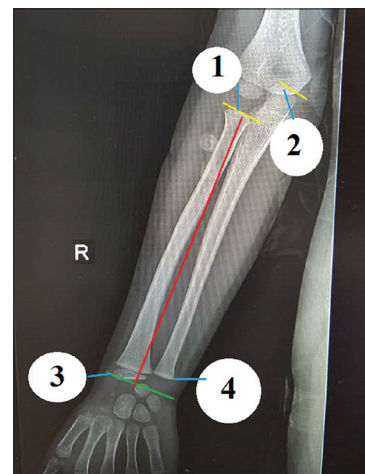
In this case series study, all children under 14 years of age with a fracture in one or both of the forearm bones referred to the Department of Orthopedic Surgery in the Imam Khomeini Hospital of Urmia University of Medical Sciences were included from November 2015 to December 2020. They were recalled at least after 12 months of primary treatment and clinical examination and contralateral forearm radiography was done for the uninjured side. Inclusion criteria included patients with diaphyseal radius and ulna fractures, those with open fractures, those with compartment syndrome, and floating elbow injuries, and patients with fractures that develop unacceptable displacement during nonoperative management with residual angulation who need operative treatment and fixation with flexible intramedullary nail (TEN) or plate. Exclusion criteria included isolated ulnar fractures, the Salter–Harris type fractures on distal radius, refractures, congenital deformities of the upper extremities, and metabolic or genetic diseases. All children were followed up for at least 12 months after the initial treatment and, after being selected, were re-examined by calling patients at the orthopedic clinic. Clinical examination is performed at least 12 months after treatment, which is a sufficient time for longitudinal limb growth. Demographic findings, type of fracture based on its anatomical location, and type of treatment including a surgical fixation with flexible intramedullary nail or plate are recorded. For accurate examination of longitudinal growth disorder, control radiographs were taken from the treated and healthy limbs; and the amount of growth disorder was

determined in the presence and absence and its amount in millimeters. Finally, children were divided into two groups with and without longitudinal growth disorder, and the risk factors considered were examined between the two groups. In this study, patients who had more than 3 mm of growth compared to the opposite side in the forearm were considered as longitudinal overgrowth.<sup>[9]</sup> The amount of loss of motion in the wrist, including pronation/supination and flexion/extension on the injured side compared to the healthy side, has been investigated. Quantifying disabilities has also been assessed using the MAYO Elbow Score (MES) and MAYO Wrist Score (MWS).<sup>[10]</sup> According to this method, scoring ranges from 0 (no disability) to 100 (maximum disability). Children’s pain was recorded using the Visual Analog Scale and Wong–Baker’s Faces Pain Rating Scale, which was displayed to the child as an emoticon on a standard ruler and was based on the emoticon selected by the child as pain intensity.<sup>[11]</sup>

## Measurement of radiographic parameters in ulnar and radius

On anterior–posterior and lateral radiographs, the forearm is divided into three equal parts, including proximal, middle, and distal, and each part is examined separately. Image-J software was used to analyze radiographs. The ulnar length was measured through a line from the center of the olecranon to the tip of the ulnar distal physis. To measure the length of the radius, a linear radius from the neck (radial neck) to the tip of the radial styloid is considered and compared with the healthy side<sup>[12]</sup> [Figure 1].

Descriptive statistical methods including mean  $\pm$  standard deviation were used to analyze the data. Chi-square frequency analysis or Fisher’s exact test was used to compare qualitative data between the two groups with and without longitudinal overgrowth. An independent *t*-test was used to compare the quantitative findings between the two groups. Pearson



**Figure 1:** Measuring method of radial and ulnar length. To measure the length of the radius, a linear radius from the neck (radial neck) (1) to the tip of the radial styloid (3) in millimeter. Measure the ulnar length through a line from the center of the olecranon (2) to the distal physis (4)

correlation coefficient was used to examine the relationship between age and longitudinal growth of children's forearms. To analyze the data, SPSS17 was used and  $P < 0.05$  was considered significant.

In this study, all patient information was confidential and a written consent form was obtained from the children's parents for re-examination. This study was implemented under the supervision of the Ethics Committee of Urmia University of Medical Sciences (IR.UMSU.REC.1397.182).

## RESULTS

In this study, 38 children with forearm fractures were included in the study. The demographic findings are presented in Table 1. In 13 children (34.2%), forearm longitudinal growth had occurred as overgrowth and no shortage was observed in any of the pediatric follow-up periods. All cases of growth increase were in the radius and were not present in the ulnar. The minimum longitudinal overgrowth was 4 mm and the maximum was 10 mm. The average longitudinal overgrowth was  $5.8 \pm 1.6$  mm. In one case, the longitudinal overgrowth was followed by fixation with TEN [Figure 2], and in 12 cases, it was followed by plate fixation [Figures 3 and 4]. All cases of increased longitudinal overgrowth occurred in the radius. There was no significant functional impairment in the range of motion of the wrist and forearm in children with increased longitudinal growth so that the mean and standard deviation of the MWS was  $92.4 \pm 8.6$  and the mean MES was  $90.3 \pm 6.2$  [Table 2]. Secondary distal radioulnar joint instability was not occurred in any cases with increased longitudinal growth; however, some of them had mild wrist pain in overactivity. In cases where there was an increase in longitudinal growth, 12 cases (92%) had fractures of distal third and 1 case (8%) had the midshaft third fracture [Figure 5]. Regarding age, there was a significant negative relationship between longitudinal growth and the age of individuals, so that with decreasing age of children, the amount of longitudinal growth of forearm increases ( $P = 0.002$ ,  $R = -0.8$ ) [Figure 6].

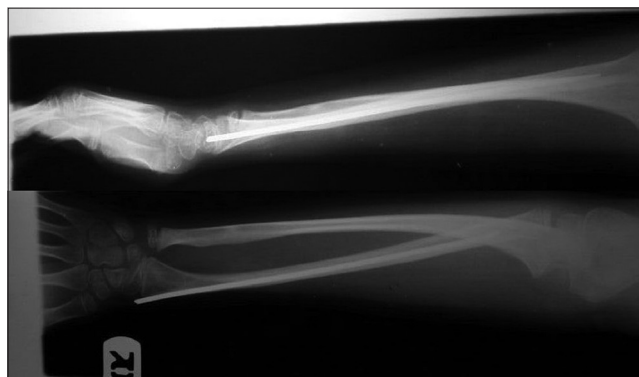
**Table 1: Demographic findings of all pediatrics with forearm fractures enrolled in this study**

Variables	Frequency (%)
Age (years), mean±SD	9.6±2.6
Mean of follow-up (months)	28.6±12.4
Boys	31 (81.6)
Girls	7 (18.4)
Radius fractures	5 (13.2)
Double (radius and ulna) fractures	33 (86.8)
One-third of distal	16 (42.1)
One-third of mid shaft	12 (31.6)
One-third of proximal	10 (26.3)
longitudinal overgrowth	13 (34.2)
Plate fixation	24 (63.1)
TEN fixation	14 (36.9)

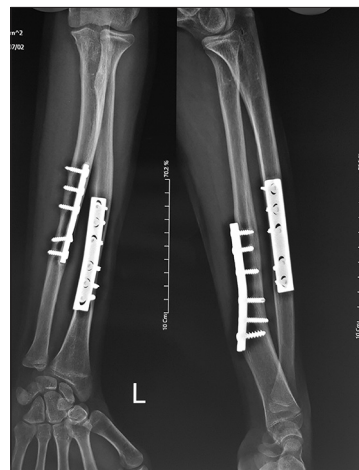
TEN: Titanium Elastic Nail

## DISCUSSION

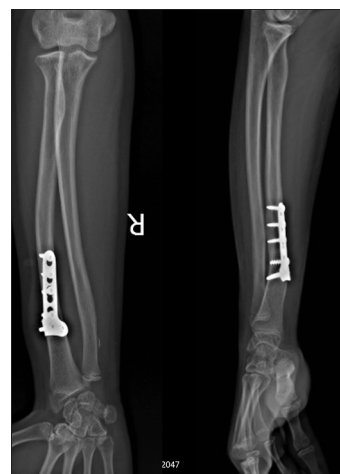In this study, we tried to examine one of the surgical treatment cycles of pediatric forearm fractures, including longitudinal growth disturbance. There are few studies in this area. Unlike



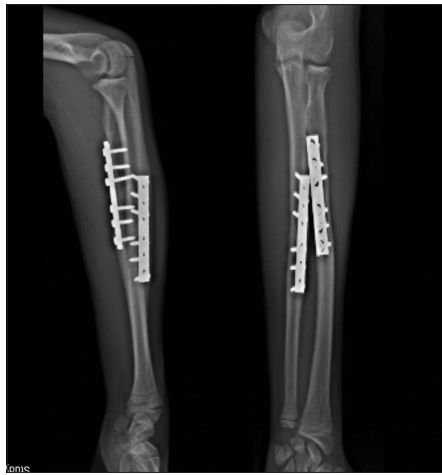**Figure 2:** Twelve months after fracture fixation with Titanium Elastic Nail and longitudinal bone overgrowth (4 mm) in the radius



**Figure 3:** Ten months after plate fixation on the distal third both bone fractures with 9 mm longitudinal bone overgrowth in the radius



**Figure 4:** Twelve months after plate fixation on the radius isolated fracture with 7 mm longitudinal bone overgrowth



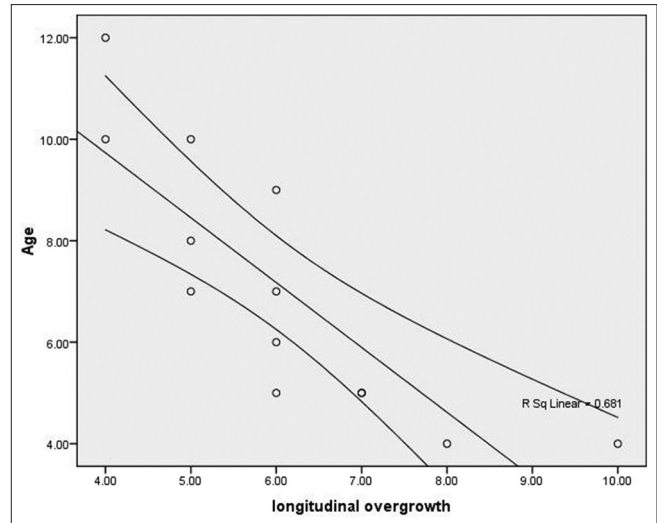
**Figure 5:** Fourteen months after plate fixation on the mid-shaft both bone fractures with 4mm longitudinal bone overgrowth in the radius

**Table 2: Findings in pediatric with forearm longitudinal discrepancy after surgical treatment (n=13)**

Variables	Frequency (%)
Age (years), mean±SD	7.5±2.7
Boys	11 (84.7)
Girls	2 (15.3)
Overgrowth (mm)	6.07±1.6
Undergrowth (mm)	-
Plate fixation	12 (92.4)
Intramedullary nail fixation	1 (7.6)
Right hand	10 (76)
Left hand	3 (23)
Radius fractures	6 (38.5)
Double fractures	8 (61.5)
One-third distal	12 (92.4)
One-third middle	1 (7.6)
One-third proximal	-
Mayo wrist score (mean±SD)	92.4±8.6
Mayo elbow score (mean±SD)	90.3±6.2
Pain (VAS score) (mean±SD)	2.5±0.8
Pronation/supination (wrist) degree (mean±SD)	135.4±12.6
Flexion/extension (wrist) degree	68.2±10.2/60.3±11.3

VAS: Visual Analog Scale, SD: Standard deviation

adults due to the growth capability by physis, the presence of a tough periosteum and the rapid remodeling capacity in children are the desired results of the final treatment of forearm fractures.<sup>[5,6]</sup> In unstable forearm fractures, fixation with plate or intramedullary nails can be used. Growth discrepancy can be one of the findings of fracture stabilization, which manifests itself as reduced or increased growth. In pediatric femoral shaft fractures, the phenomenon of increased longitudinal growth after fracture fixation is known, but in the upper limb, the mechanism and factors involved have not been studied.<sup>[5,7]</sup> Increased radius growth and deformity after fracture fixation in children were first described in a report by Williams and Szabo.<sup>[13]</sup> Increased growth and development of angular deformity after surgical treatment and fracture fixation due to



**Figure 6:** Negative correlation between pediatric age and longitudinal bone overgrowth

palmar instability caused functional impairment and pain in the child's wrist.<sup>[13]</sup> In a study conducted by Dai *et al.* in pediatric femoral shaft fractures, there was an association between increased femoral longitudinal growth after fixation with the intramedullary nail. Furthermore, younger age of pediatric has been another effective factor in increased longitudinal growth on femoral fractures.<sup>[4]</sup> However, the exact mechanism of enhancement of longitudinal growth is not known in the upper extremities, but what is clear is that the remodeling power of angular and rotational deformities is greater in children than in adults. One of the reasons for the increase in longitudinal growth is due to the increase in blood supply around the growth plate, which occurs during fixation device insertion.<sup>[7]</sup>

In a study by Cremer *et al.* in 13 children with forearm fractures fixed with a plate, there was an increase in the longitudinal growth in 2 cases, so that a maximum increase in longitudinal growth of 11 mm was reported.<sup>[14]</sup> In our study, there was a 34% increase in longitudinal growth. Furthermore, the study of de Pablos *et al.* indicates radial overgrowth in 21% of children with forearm fractures after being conservatively treated.<sup>[8]</sup> Increased longitudinal growth in the study of de Pablos *et al.* had no relationship between the type of forearm fracture in healthy and injured children.<sup>[8]</sup>

Similar findings were found in children with increased longitudinal growth. In our study, no significant functional impairment was observed, and this longitudinal overgrowth was tolerable in children and often did not require therapeutic intervention. There have been cases of longitudinal overgrowth of the forearm after plate fixation in children,<sup>[15]</sup> in which the average longitudinal overgrowth was 2.4 mm. In a study conducted by Carsi *et al.*, 119 pediatric cases with forearm fractures were treated conservatively, 27% showed radius overgrowth and 24% had ulnar overgrowth at the 5-year follow-up.<sup>[9]</sup> Contrary to our findings, proximal and middle third fractures were strongly associated with overgrowth, while all



cases of overgrowth in our study were within the radius and most cases of overgrowth were in distal third fractures. Most cases of overgrowth were in the distal third.<sup>[14]</sup> Perhaps, one of the reasons for the difference in the results of the study performed by Carsi *et al.* and the present study is due to the investigation of nonsurgical cases.<sup>[9]</sup> Increased local blood flow near the growth plate due to trauma caused by surgery can induced longitudinal growth in the pediatric forearm after surgical fixation. Rouhani *et al.* reported that the site of intramedullary nail insertion is near the distal growth plate which can increase the blood supply in this area; this can be considered a factor for the growth increase, however, further studies need to be conducted in this regard.<sup>[16]</sup> The present study shows the negligible effect of forearm longitudinal overgrowth on the final function of children. Parents and orthopedic surgeons should not worry and seek early operative intervention. However, the X-ray may be worrying and there will be no problem clinically.

### Limitations of the study

This case series study was a descriptive study, in which all children with surgical forearm fractures were included. It was not possible to increase the sample size further due to practical constraints. Surgical interventions have been performed by several surgeons with various devices and the two methods of fixation with the plate and intramedullary nail have been used. Furthermore, due to the small sample size, there were not divided and compared effects of two method fixation with plate or elastic intramedullary nail in the pediatric forearm longitudinal overgrowth after surgical fixation.

### CONCLUSIONS

Longitudinal overgrowth is one of the findings of surgical treatment of pediatric forearm fractures. Young age, fractures of the distal third, and the use of plate for fixation appear to be associated with forearm longitudinal overgrowth. This longitudinal overgrowth does not affect the functional ability of children, most of them do not require intervention.

### Ethical issues

The study was confirmed by the Ethics Committee of Urmia University of Medical Sciences.

### Acknowledgments

This study was financially supported by Urmia University of Medical Sciences.

### Financial support and sponsorship

Nil.

### Conflicts of interest

There are no conflicts of interest.

### REFERENCES

1. Guitton TG, Van Dijk NC, Raaymakers EL, Ring D. Isolated diaphyseal fractures of the radius in skeletally immature patients. *Hand (N Y)* 2010;5:251-5.
2. Kelly BA, Shore BJ, Bae DS, Hedequist DJ, Glotzbecker MP. Pediatric forearm fractures with *in situ* intramedullary implants. *J Child Orthop* 2016;10:321-7.
3. Stilli S, Magnani M, Lampasi M, Antonioli D, Bettuzzi C, Donzelli O. Remodelling and overgrowth after conservative treatment for femoral and tibial shaft fractures in children. *Chir Organi Mov* 2008;91:13-9.
4. Dai CQ, Yang J, Guo XS, Sun LJ. Risk factors for limb overgrowth after the application of titanium elastic nailing in the treatment of pediatric femoral fracture. *J Orthop Sci* 2015;20:844-8.
5. Teoh KH, Chee YH, Shortt N, Wilkinson G, Porter DE. An age- and sex-matched comparative study on both-bone diaphyseal paediatric forearm fracture. *J Child Orthop* 2009;3:367-73.
6. Fernandez FF, Egenolf M, Carsten C, Holz F, Schneider S, Wentzensen A. Unstable diaphyseal fractures of both bones of the forearm in children: Plate fixation versus intramedullary nailing. *Injury* 2005;36:1210-6.
7. Kuo FC, Kuo SJ, Ko JY. Overgrowth of the femoral neck after hip fractures in children. *J Orthop Surg Res* 2016;11:50.
8. de Pablos J, Franzreb M, Barrios C. Longitudinal growth pattern of the radius after forearm fractures conservatively treated in children. *J Pediatr Orthop* 1994;14:492-5.
9. Carsi B, Abril JC, Epeldegui T. Longitudinal growth after nonphyseal forearm fractures. *J Pediatr Orthop* 2003;23:203-7.
10. Cusick MC, Bonnaig NS, Azar FM, Mauck BM, Smith RA, Throckmorton TW. Accuracy and reliability of the mayo elbow performance score. *J Hand Surg Am* 2014;39:1146-50.
11. Friedrichsdorf SJ, Kang TI. The management of pain in children with life-limiting illnesses. *Pediatr Clin North Am* 2007;54:645-72, x.
12. Cravino M, Oni JK, Sala DA, Chu A. A radiographic study of pediatric ulnar anatomy. *J Pediatr Orthop* 2014;34:537-41.
13. Williams AA, Szabo RM. Case report: Radial overgrowth and deformity after metaphyseal fracture fixation in a child. *Clin Orthop Relat Res* 2005;435:258-62.
14. Cremer P, Angelliaume A, Lalioui A, Cellarier G, Harper L, Lefevre Y. Functional and radiological outcome after forearm plating in children and adolescent fracture. *Acta Orthop Belg* 2021;87:143-9.
15. Nielsen AB, Simonsen O. Displaced forearm fractures in children treated with AO plates. *Injury* 1984;15:393-6.
16. Rouhani A, Tabrizi A, Afshar A, Elmi A. Longitudinal overgrowth of the forearm after fracture fixation with flexible intramedullary nail: A case report and review of the literature. *Trauma Mon* 2018;23:e63088.