

Minimally Invasive Management of a Dental Trauma: Two Years of Follow-up in Biodentine-Induced Maturogenesis

Khashayar Sanjari, Hosna Ebrahimi Zadeh¹

Department of Pediatric Dentistry, School of Dentistry, Arak University of Medical Sciences, Arak, Iran, ¹Department of Restorative, Dental Research Center, School of Dentistry, Shahid Beheshti University of Medical Sciences, Tehran, Iran

ORCID:

Khashayar Sanjari: <https://orcid.org/0000-0001-5011-0927>

Hosna Ebrahimi Zadeh: <https://orcid.org/0000-0002-8910-2745>

Abstract

Dental trauma is an ordinary complication in childhood period. Most of the traumas are crown fractures in the permanent dentition. Complicated crown fracture, introduced as a crown fracture accompanied by pulp exposure. Treatment plan and long-term prognosis could be modified by different factors, such as fracture line position, root development, alveolar bone fracture, and occlusion. In traumatized open apices teeth, apexogenesis can be occurred after traumatic exposure by vital pulp therapy procedures such as pulp capping, partial or complete pulpotomy in pertinent to the size of the exposure. In this complicated crown fracture case, cervical pulpotomy was performed with a silicate-based biomaterial. Patients smile and esthetic demands play an important role in the perception and judgment that people have of others appearance and character. To reconstruct the patient's smile line, the adhesive reattachment of the coronal fractured fragment to the remaining tooth structure was planned. Reattachment could be suggested as an ideal treatment procedure for crown fracture cases. This technique could be applied to achieve excellent esthetic outcomes and normal function. At 1-year follow-up visit, the patient had no complaints of pain. The clinical and radiographic examination showed a stable reattachment and good periodontal health. Apex diameter was decreased significantly. Physiological root-end closure was obvious. Secondary dentin and calcific barrier were also observed on the radiograph below the Biodentine layer.

Keywords: Biodentine, dental trauma, mineral trioxide aggregate, pulpotomy, reattachment

INTRODUCTION

Dental trauma is an ordinary complication in the childhood period.^[1] Most of the traumas are crown fractures in the permanent dentition.^[2] Maxillary incisors are involved in most of the situations, about 96% of all crown fractures.^[3] The involvement of males in crown fracture is reported more than females.^[4] Traumatic injuries are the most common threats to the vitality and integrity of developing teeth since trauma may jeopardize the pulp vitality.^[5] If the root formation is completely done, routine endodontic treatment must be advised immediately after the trauma.^[6] However, in patients with open apices, pulp vitality should be preserved.^[7] Preserving the pulp vitality of traumatized teeth with incomplete root formation is the most important criterion for tooth survival because a vital pulp can provide nutrition for metabolic and dentinogenesis activities and biosensory, and defense functions against noxious irritants and finally encourage continuous

normal root development. In traumatized open apices teeth, apexogenesis can be occurred after traumatic exposure by vital pulp therapy procedures, including pulp capping, partial or cervical pulpotomy in pertinent to the size of the exposure.^[8] These induce continuous physiological deposition of dentin in the coronal region and all along the length of the root canal with greater quality and structural integrity.^[9]

In permanent dentition, mineral trioxide aggregate (MTA) is suggested in most of the pulp capping cases.^[10] The main

Address for correspondence: Dr. Hosna Ebrahimi Zadeh, Department of Restorative, Dental Research Center, School of Dentistry, Shahid Beheshti University of Medical Sciences, Tehran, Iran. E-mail: ebrahimi_hosna@yahoo.com

This is an open access journal, and articles are distributed under the terms of the Creative Commons Attribution-NonCommercial-ShareAlike 4.0 License, which allows others to remix, tweak, and build upon the work non-commercially, as long as appropriate credit is given and the new creations are licensed under the identical terms.

For reprints contact: reprints@medknow.com

How to cite this article: Sanjari K, Zadeh HE. Minimally invasive management of a dental trauma: Two years of follow-up in Biodentine-induced maturogenesis. Arch Trauma Res 2020;9:93-8.

Received: 17-10-2019, **Revised:** 10-12-2019,

Accepted: 04-02-2020, **Published:** 30-05-2020.

Access this article online

Quick Response Code:



Website:
www.archtrauma.com

DOI:
10.4103/atr.atr_94_19

disadvantages of MTA are tooth discoloration, long setting time, and solubility during the setting period.^[11] Furthermore, MTA is difficult to handle because of its granular consistency, low mechanical properties, and initial looseness.^[12]

The other biomaterial, which is used as a pulp capping agent, is biodentine. Biodentine releases more calcium ions than MTA.^[13] Biodentine has several ingredients such as tricalcium silicate, dicalcium silicate, calcium carbonate, iron oxide, and zirconium oxide. Liquid of Biodentine includes calcium chloride as an accelerator agent, water-soluble polymer, and a water reducing agent.^[14] Biodentine has multiple advantages, such as low level of cytotoxicity,^[15] excellent biocompatibility, and inducing formation of dentinal tags.^[16]

A natural smile has a great impaction on the apprehension of people about the character of others.^[17] Tooth fracture has physical and emotional trauma to a child and adolescent because it leads to missing a part of tooth structure.^[18]

Lots of techniques have been reported to regain the esthetic in these cases of the anterior zone in the oral cavity,^[19] but the most conservative solution for the treatment of a tooth with crown fracture is reattachment of the fragment. It can be used to attain maximum maintenance of tooth structure and highly esthetics demands.^[20]

This paper reports a complicated crown fracture case in the left mandibular central incisor, which was treated by coronal pupotomy with Biodentine and reattachment of the fractured fragment using a light cure composite resin. This case was followed up until 2 years to demonstrate the procedure of maturogenesis.

CASE REPORT

A 7-year old male referred to the department of Endodontics of Shahid Beheshti University of Medical Sciences, Tehran, Iran, with a chief complaint of dental pain and broken lower anterior tooth due to a physical contact during a football match. The refer visit was 3 days after the traumatic accident, and the child and his parents reported a long-lasting pain after drinking cold water and tenderness during biting. On extraoral and intraoral examination, there was no apparent trauma to the soft tissues. Parents reported no systemic disease. Intraoral examination revealed a complicated crown root fracture of the mandibular left central incisor.

Palatal gingiva and interdental papilla were neither inflamed nor edematous. The evaluation of periodontal status of the patient revealed the absence of periodontitis. The intraoral periapical radiograph showed the fracture line. There was no evidence of periapical pathosis [Figure 1]. The tooth was tender mildly to percussion and showed no mobility [Figure 1].

The status of pulp was evaluated by pulp sensitivity tests, which included cold testing with ice stick, and readings of pulpal response were recorded by an electric pulp tester (Parkell Inc.,

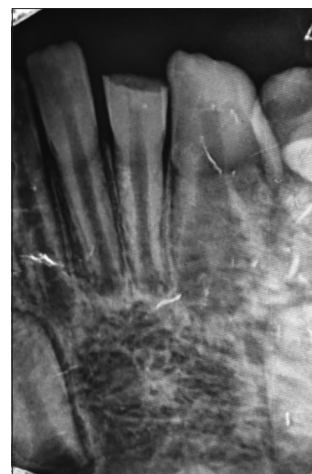

Figure 1: Complicated crown fracture

Edgewood, NY, USA) and compared with its contralateral tooth.

The fragment was preserved in saline until reattachment to avoid discoloration and dehydration. The surface of fragment and pulp chamber was debrided and cleaned.

Mandibular nerve block and buccal infiltration of 2% lidocaine containing 1:80,000 epinephrine (Darupakhsh, Tehran, Iran) was administered and rubber dam was placed.

Although the patient referred 3 days after the trauma, access cavity was prepared with a diamond fissure bur followed by a cervical pulpotomy with round diamond bur #2 using a high-speed handpiece under water irrigation and sufficient cooling, pulpal floor and all vital tissues in coronal pulp were amputated, and bleeding was controlled by three times application of 2.5% hypochlorite sodium. Each time a cotton pellet soaked in 2.5% hypochlorite sodium and applied on pulp for 3 min. When hemostasis achieved, Biodentine (Septodont, Saint-Maur-des-Fosses, France) was processed according to the manufacturer's instruction by mixing a single-unit powder part and five drops of a single-unit liquid part for 30 s. Biodentine was placed in the coronal pulp space with an MTA carrier (Dentsply Maillefer, USA) and was condensed gently using hand pluggers (Dentsply Maillefer, USA). The orifice area was filled with Biodentine. The thickness of Biodentine layer was 3 mm. A periapical radiography was taken to confirm proper sealing of the orifice region [Figure 2]. After waiting for 12 min, a thin layer of resin-modified glass ionomer was applied to prepare coronal seal.

The adhesive reattachment of the coronal fractured fragment to the remaining tooth structure was planned. In addition, 37.5% phosphoric acid as an enamel etchant was applied for 20 s.

After rinsing and lightly air-drying of both tooth and fragment surfaces, a chalk-like (frosty) appearance of the enamel on both surfaces was observed.

The adhesive resin was applied with rubbing for 10 s to both surfaces without light curing to prevent misfit of the bonded parts.

A flowable composite resin (Voco, Cuxhaven, Germany) was used in order to bind the broken fragment to the retained tooth.

The fragments were reattached to the remaining tooth and light-cured for 10 s using a light-emitting diode light-curing unit (Demetron A.2; Kerr Italia, S.p.A., Scafati, Italy) on both labial and lingual surfaces with a light intensity of 1000 mW/cm² while pressing the coronal fragment against the matching tooth part. After curing, a chamfer was prepared on the enamel at the bonding line of buccal aspect and filled with composite to cover the fracture line and increase esthetic.

The subsequent appointment was a week later. There was no tenderness to percussion and patient-reported the absence of pain. Pulp tests were not reliable because of different reactions of the child.

One month later, clinical and radiographic examination revealed a stable reattachment of crown fragments. Pulp tests were also normal.

The patient was recalled at a scheduled manner: 1, 2, 6, and 12 months and evaluated both clinically and radiographically for evidence of pulpal and periapical pathology. Digital intraoral radiographs were evaluated for evidence of root obliteration, root resorption, or periapical changes.

At 1-year follow-up visit, the patient had no complaints of pain. The clinical and radiographic examination showed a stable reattachment and good periodontal health. Furthermore, apex diameter was decreased significantly. Physiological root-end closure was obvious [Figure 3].

In an 18-month follow-up session, apex closure was performed, and root thickness was increased. Vitality tests (cold test and electric pulp testing) showed that the tooth is vital, and pulp condition is normal [Figure 4].

Secondary dentin and calcific barrier were also observed on the radiograph below the Biodentine layer. The thickness of the secondary dentin layer was 2 mm.

The patient and his parents were satisfied by the appearance.

Photographs of this patient, before and after treatment, are shown in Figures 5 and 6.

DISCUSSION

Dental injuries predominantly occur during the first two decades of life.^[21] It has been reported that more than 20% of school-age children suffer a traumatic dental injury (TDIs).^[1] Coronal fractures of the anterior teeth are the most frequent form of TDI that mainly affects children and adolescents.^[22]

Esthetic considerations

In the case of esthetic considerations and rebuilding of these teeth, various treatment modalities are available for the management of fractured anterior teeth include composite restoration, post, and core supported prosthesis.

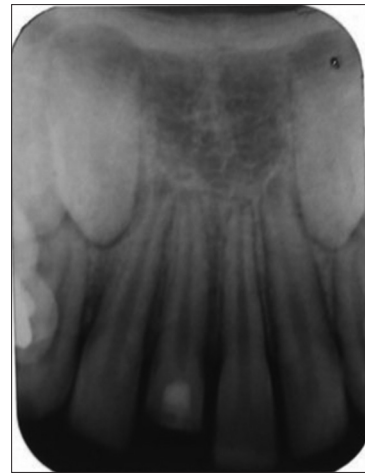


Figure 2: Application of Biodentine

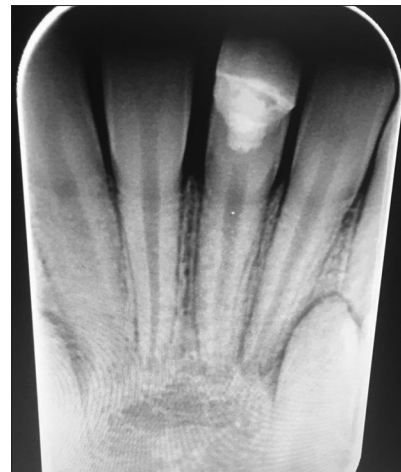

Figure 3: Root closure

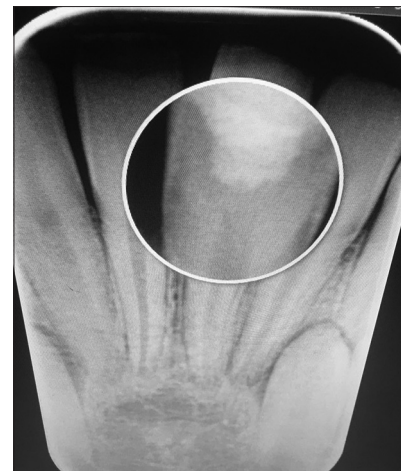

Figure 4: Dental bridge, complete root closure

In a case report conducted by Vâlceanu and Stratul^[23] after the endodontic treatment, the patient was treated using the combination of several techniques: periodontal surgery (crown lengthening with apically repositioned flap and osseous

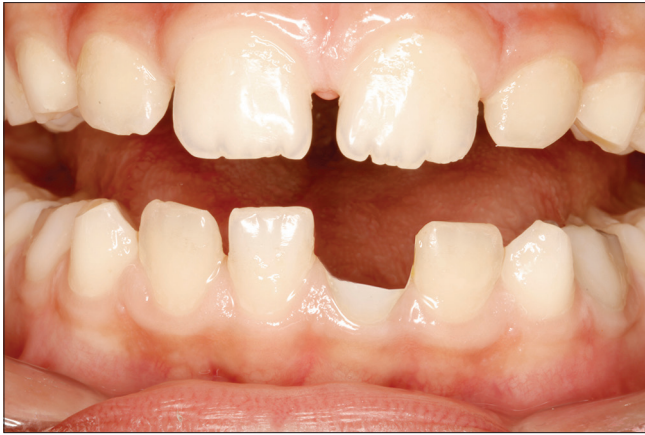

Figure 5: Before treatment

resective surgery), adhesive technique, and cast restoration plus esthetic crown.

In the case of Vâlceanu, despite our case, the vitality of tooth was not preserved. The esthetic management of Vâlceanu case was invasive. In addition, chair time and cost of treatment were high.

Complex metal-ceramic crowns with considerable loss of remaining sound structure are no longer necessary due to adhesive techniques, such as composite restorations and reattachment techniques. With the advent of newer generation dentin bonding agents and adhesive materials, reattachment of the fractured fragments has become a reliable treatment modality. Reattached teeth are resistant to shear stresses, similar to the intact teeth.^[24]

Reattachment of the original tooth fragment to the fractured tooth helps in maintaining the tooth's color, wear resistance, morphology, and translucency in the restoration; it is probably less traumatic, simple and low-cost method. In addition, it establishes superior esthetics, positive emotional, and social response from the patient toward the preservation of natural tooth structure.^[20,25] Currently, the use of 37% phosphoric acid is the standard protocol for enamel conditioning.^[26] Longevity of the reattached teeth is the major concern in view of the success of the treatment. Most of the failures result due to trauma or nonphysiologic use of the reattached tooth.^[27]

Many adhesive methods have been tested, but the worst fracture resistance was obtained when reattachment is completed by adhesive materials alone (without using flowable composite). An innovative method was used to reattach the tooth fragments whereby the fiber post was inserted without drilling a hole in the crown thus preserving the integrity of the crown.^[28]

Pulp management

In the case of pulp management of crown fractured teeth, direct pulp capping and partial pulpotomy are two clinical modalities to preserve tooth vitality in cases of pulp exposure in young permanent teeth.^[29]

There was no difference between partial and coronal pulpotomy. There was no difference between partial and

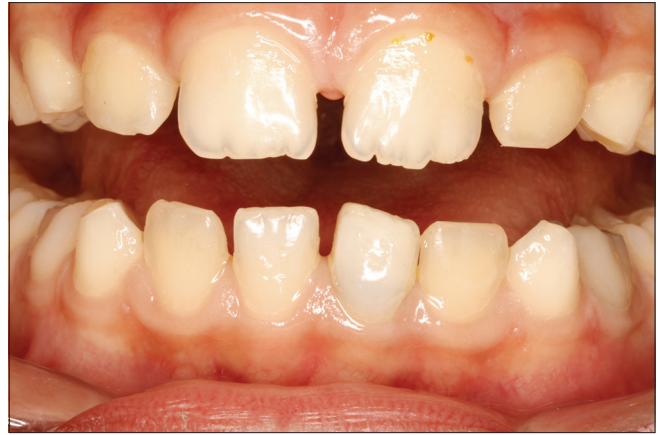

Figure 6: After treatment

coronal pulpotomy. The risk of pulp necrosis and infection was not significantly different between pulpotomy. However, the frequency of pulp necrosis and infection after direct pulp capping was significantly higher than that with pulpotomy. The time interval between dental injury and treatment did not significantly influence pulp survival after, but the stage of root development had a significant impact.^[30] MTA is a biocompatible material with many cons and pros.^[10]

To remove disadvantages of MTA, Biodentine has been introduced. It is a bioactive tooth-colored calcium silicate-based cement.^[31] The major ingredient of this biomaterial is tricalcium silicate. Calcium and silicon ion release of this material is more than MTA.^[32] The presence of silicon in its composition has a crucial effect on bioactivity. Furthermore, it could induce the mineralization of dentine.^[33] It has been shown that Biodentine is biocompatible. It could play a crucial role in odontoblast differentiation in pulp cells.^[34] Based on these features, we applied Biodentine to preserve pulp vitality and induce the formation of secondary dentin in a fractured tooth with pulp exposure. In a long-term follow-up, a thick dentinal bridge could be seen in periapical radiography.

Excellent physical characteristics of Biodentine are due to applying finer particle size, use of zirconium oxide as an agent to make the material radiopaque, purity of tricalcium silicate, and absence of dicalcium silicate. Because of these aspects, Biodentine could be an ideal biomaterial to rectify the main disadvantages of MTA.^[35]

It should be considered that blood contamination does not impact on the marginal adaptation of Biodentine.^[36] Because of this ideal characteristic of Biodentine, it was applied as an effective material in this case to reduce marginal leakage and maintain normal structure and function of fractured tooth in long time.

CONCLUSION

Biodentine could be recommended as a useful biomaterial for preserving tooth vitality in traumatic pulp exposure. Handling characteristics of this biomaterial and its potential to form

secondary dentin encourage practitioners to apply it. It has the ability to make a great effect on treatment procedures in pediatric dentistry and endodontics, especially in pulp exposure management. However, it is necessary to plan high-quality clinical studies to prove it.

Tooth vitality in traumatic cases can be preserved, and routine root canal therapy should not be implemented in all crown-fractured cases.

Reattachment could be suggested as an ideal treatment procedure for crown fracture cases. This technique could be applied to achieve excellent esthetic outcomes and normal function.

Declaration of patient consent

The authors certify that they have obtained all appropriate patient consent forms. In the form the patient(s) has/have given his/her/their consent for his/her/their images and other clinical information to be reported in the journal. The patients understand that their names and initials will not be published and due efforts will be made to conceal their identity, but anonymity cannot be guaranteed.

Financial support and sponsorship

Nil.

Conflicts of interest

There are no conflicts of interest.

REFERENCES

- Ghadimi S, Seraj B, Keshavarz H, Shamshiri AR, Abiri R. The effect of using an educational poster on elementary school health teachers' knowledge of emergency management of traumatic dental injuries. *J Dent (Tehran)* 2014;11:620-8.
- Singh TK, Passi D, Aggarwal S, Mohan S, Sharma A, Gupta U. Esthetic management of complicated crown fracture of three permanent maxillary teeth by grout technique -A case report. *J Family Med Prim Care* 2019;8:2538-41.
- Goenka P, Marwah N, Dutta S. Biological approach for management of anterior tooth trauma: Triple case report. *J Indian Soc Pedod Prev Dent* 2010;28:223-9.
- Zerman N, Cavalleri G. Traumatic injuries to permanent incisors. *Endod Dent Traumatol* 1993;9:61-4.
- Ghorbanzadeh A, Ghorbanzadeh A. Maturogenesis of two maxillary central incisors: A Case report with 10 years of follow up. *J Dent (Tehran)* 2015;12:306-15.
- Scholtes E, Suttorp CM, Loomans BA, Van Elsas P, Schols JG. Combined orthodontic, surgical, and restorative approach to treat a complicated crown-root fracture in a maxillary central incisor. *Am J Orthod Dentofacial Orthop* 2018;154:570-82.
- Cavalleri G, Zerman N. Traumatic crown fractures in permanent incisors with immature roots: A follow-up study. *Endod Dent Traumatol* 1995;11:294-6.
- Martens L, Rajasekharan S, Cauwels R. Pulp management after traumatic injuries with a tricalcium silicate-based cement (Biodentine™): a report of two cases, up to 48 months follow-up. *Eur Arch Paediatr Dent* 2015;16:491-1.
- Weisleder R, Benitez CR. Maturogenesis: Is it a new concept? *J Endod* 2003;29:776-8.
- Khedmat S, Aminipor M, Pourhajibagher M, Kharazifar MJ, Bahador A. Comparison of antibacterial activities of ProRoot MTA, OrthoMTA, and RetroMTA against three anaerobic endodontic bacteria. *J Dent (Tehran)* 2018;15:294-9.
- Kazemipoor M, Azizi N, Farahat F. Evaluation of microhardness of mineral trioxide aggregate after immediate placement of different coronal restorations: An *in vitro* study. *J Dent (Tehran)* 2018;15:116-22.
- Dianat O, Naseri M, Tabatabaei SF. Evaluation of properties of mineral trioxide aggregate with methyl cellulose as liquid. *J Dent (Tehran)* 2017;14:7-2.
- Han L, Okiji T. Bioactivity evaluation of three calcium silicate-based endodontic materials. *Int Endod J* 2013;46:808-14.
- Grech L, Mallia B, Camilleri J. Investigation of the physical properties of tricalcium silicate cement-based root-end filling materials. *Dent Mater* 2013;29:e20-8.
- Zhou HM, Shen Y, Wang ZJ, Li L, Zheng YF, Häkkinen L, *et al.* *In vitro* cytotoxicity evaluation of a novel root repair material. *J Endod* 2013;39:478-83.
- Han L, Okiji T. Uptake of calcium and silicon released from calcium silicate-based endodontic materials into root canal dentine. *Int Endod J* 2011;44:1081-7.
- Saffarpour A, Ghavam M, Saffarpour A, Dayani R, Fard MJ. Perception of laypeople and dental professionals of smile esthetics. *J Dent (Tehran)* 2016;13:85-91.
- Magno MB, de Paiva Cabral Tristão SK, Jural LA, Aguiar Sales Lima SO, Coqueiro RDS, Maia LC, *et al.* Does dental trauma influence the social judgment and motivation to seek dental treatment by children and adolescents? Development, validation, and application of an instrument for the evaluation of traumatic dental injuries and their consequences. *Int J Paediatr Dent* 2019;29:474-88.
- Berk N, Berk G, Uluçam S. Case report: laser-assisted rebonding of a central incisor tooth due to a severe trauma - 4 years of follow-up. *Eur Arch Paediatr Dent* 2011;12:96.
- Mahesh Patni P, Jain P, Jain Patni M. A conservative approach to the management of a dental trauma for immediate natural esthetics. *Arch Trauma Res* 2016;5:e29042.
- Enshaei Z, Ghasemi M. Multidisciplinary management of complicated crown-root fracture: A case report. *J Dent (Tehran)* 2018;15:193-6.
- Hamilton FA, Hill FJ, Holloway PJ. An investigation of dento-alveolar trauma and its treatment in an adolescent population. Part 2: Dentists' knowledge of management methods and their perceptions of barriers to providing care. *Br Dent J* 1997;182:129-33.
- Vâlceanu AS, Stratul SI. Multidisciplinary approach of complicated crown fractures of both superior central incisors: A case report. *Dent Traumatol* 2008;24:482-6.
- Davari A, Sadeghi M. Influence of different bonding agents and composite resins on fracture resistance of reattached incisal tooth fragment. *J Dent (Shiraz)* 2014;15:6-14.
- Murchison DF, Burke FJ, Worthington RB. Incisal edge reattachment: Indications for use and clinical technique. *Br Dent J* 1999;186:614-9.
- Akhoundi MS, Etemadi A, Nasiri M, Borujeni ES. Comparison of enamel morphologic characteristics after conditioning with various combinations of acid etchant and Er: YAG laser in bonding and rebonding procedures: A SEM analysis. *J Dent (Tehran)* 2017;14:144-52.
- Macedo GV, Diaz PI, De O Fernandes CA, Ritter AV. Reattachment of anterior teeth fragments: A conservative approach. *J Esthet Restor Dent* 2008;20:5-18.
- Tonini R. An innovative method for fragment reattachment after complicated crown fracture. *J Esthet Restor Dent* 2017;29:172-7.
- Qudeimat MA, Barrieshi-Nusair, KM, Owais AI. Calcium hydroxide vs mineral trioxide aggregates for partial pulpotomy of permanent molars with deep caries. *Eur Arch Paediatr Dent* 2007;8:99.
- Wang G, Wang C, Qin M. Pulp prognosis following conservative pulp treatment in teeth with complicated crown fractures: A retrospective study. *Dent Traumatol* 2017;33:255-60.
- Khoshkhounejad M, Shokouhinejad N, Pirmoazen S. Regenerative endodontic treatment: Report of two cases with different clinical management and outcomes. *J Dent (Tehran)* 2015;12:460-8.
- Gandolfi MG, Van Landuyt K, Taddei P, Modena E, Van Meerbeek B, Prati C. Environmental scanning electron microscopy connected with energy dispersive X-ray analysis and Raman techniques to study ProRoot mineral trioxide aggregate and calcium silicate cements in wet

- conditions and in real time. J Endod 2010;36:851-7.
33. Saito T, Toyooka H, Ito S, Crenshaw MA. *In vitro* study of remineralization of dentin: Effects of ions on mineral induction by decalcified dentin matrix. Caries Res 2003;37:445-9.
 34. Soundappan S, Sundaramurthy JL, Raghu S, Natanasabapathy V. Biodentine versus mineral trioxide aggregate versus intermediate restorative material for retrograde root end filling: An *in vitro* study. J Dent (Tehran) 2014;11:143-9.
 35. Rajasekharan S, Martens LC, Cauwels RGEC, Anthonappa RP, Verbeeck RMH. Biodentine™ material characteristics and clinical applications: a 3 year literature review and update. Eur Arch Paediatr Dent 2018;19:1-22.
 36. Bolhari B, Ashofteh Yazdi K, Sharifi F, Pirmoazen S. Comparative scanning electron microscopic study of the marginal adaptation of four root-end filling materials in presence and absence of blood. J Dent (Tehran) 2015;12:226-34.